

CONGRESSO NAZIONALE SIFE

Rigenerazione ossea con tecniche di fissazione interna ed esterna.
Prevenzione e trattamento delle infezioni ossee in traumatologia

Presidente del Congresso
Dott. Alexander Kirienko
Istituto Clinico Humanitas - Rozzano

SIFE
SOCIETÀ ITALIANA
FISSAZIONE ESTERNA

2023
27-28 Ottobre
MILANO

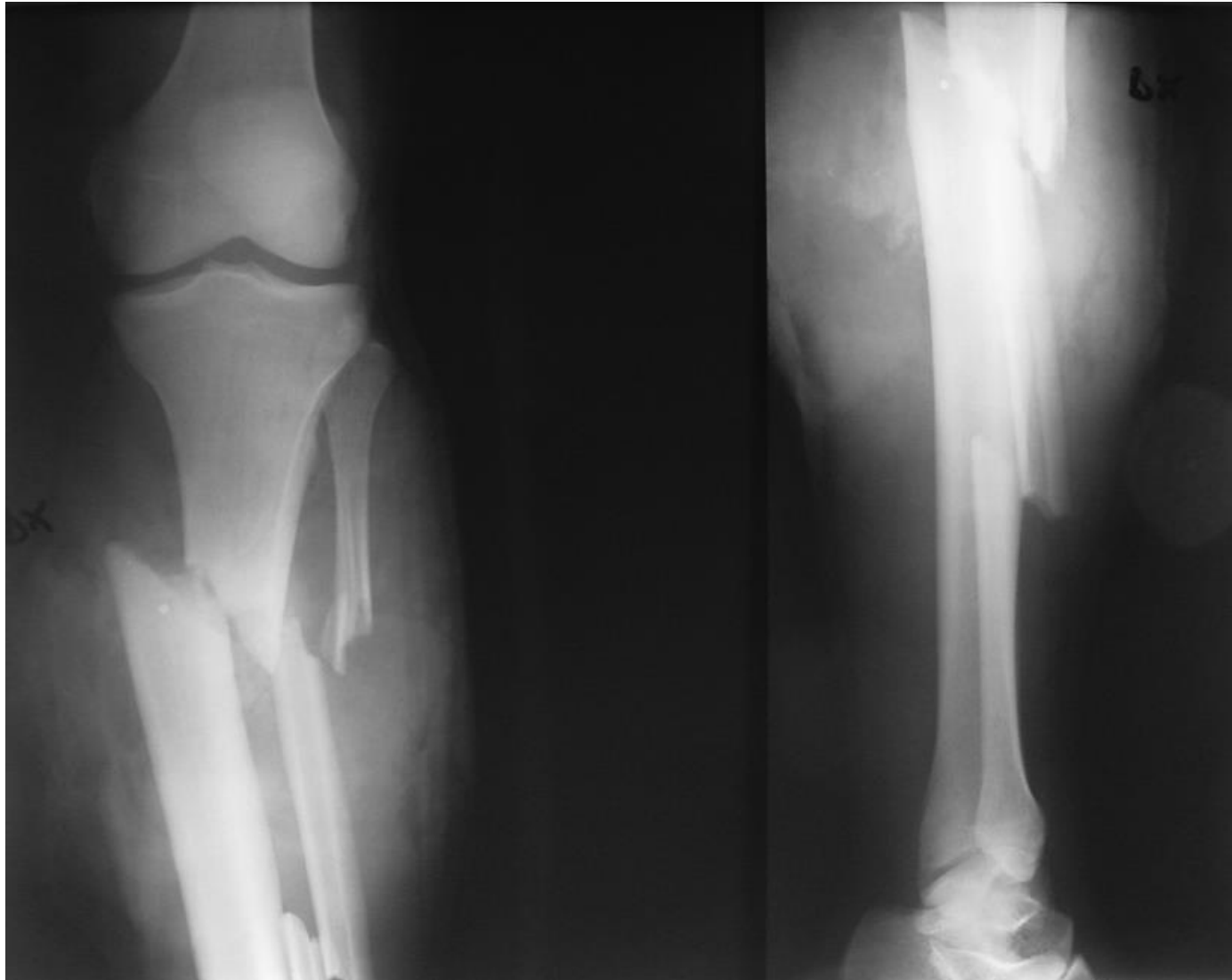
TRATTAMENTO DEI DIFETTI OSSEI PARZIALI CON TRASPORTO DI UN FRAMMENTO OSSEO

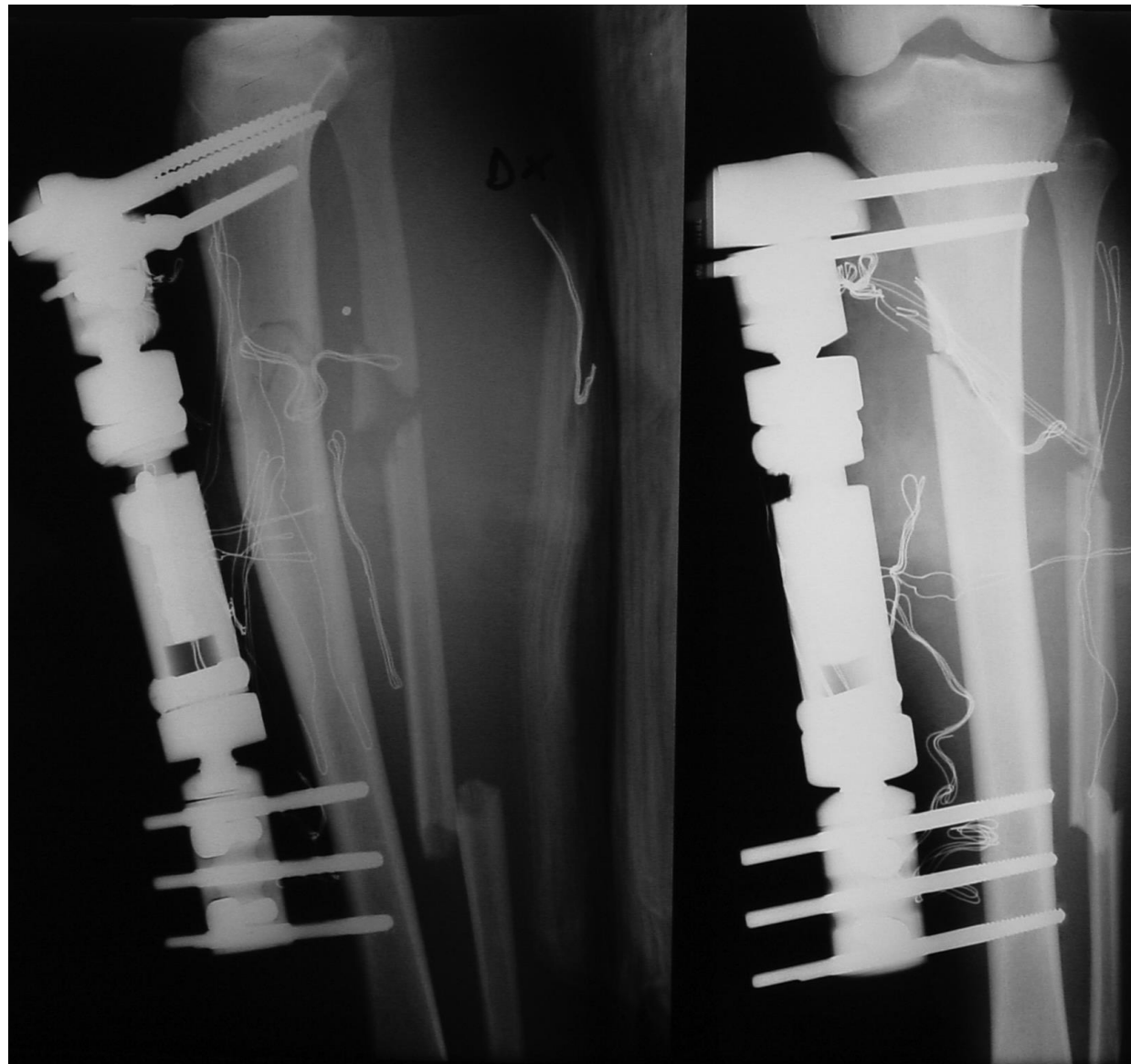
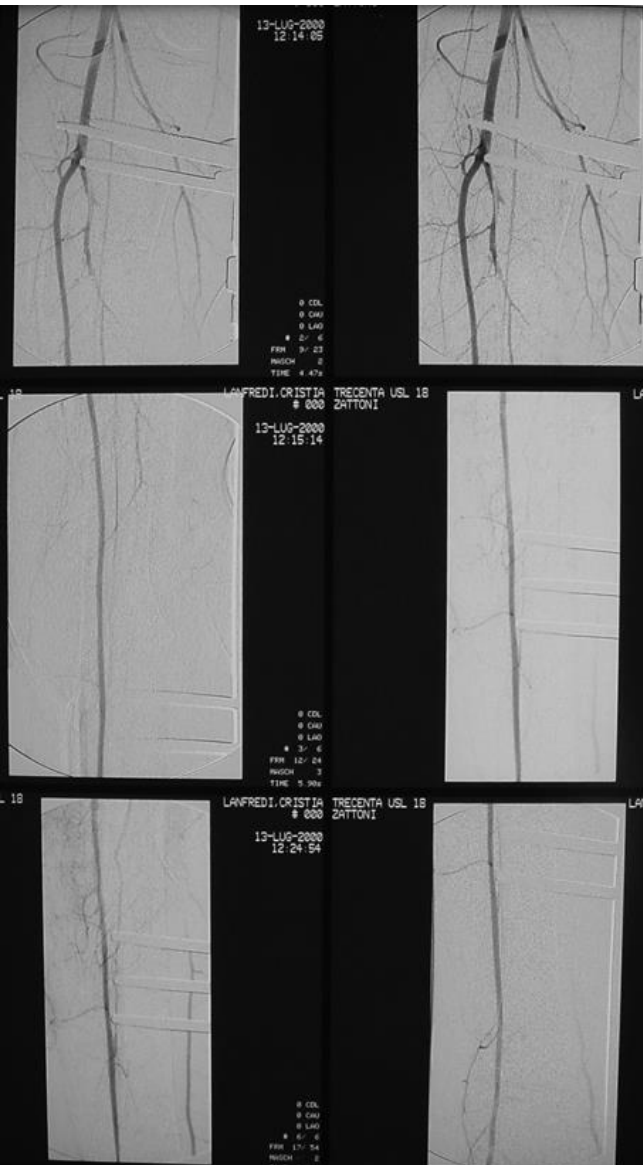Partial bone defects treatment with transport of a bone fragment

E. Malagoli, A. Kirienko, F. Vandenbulcke

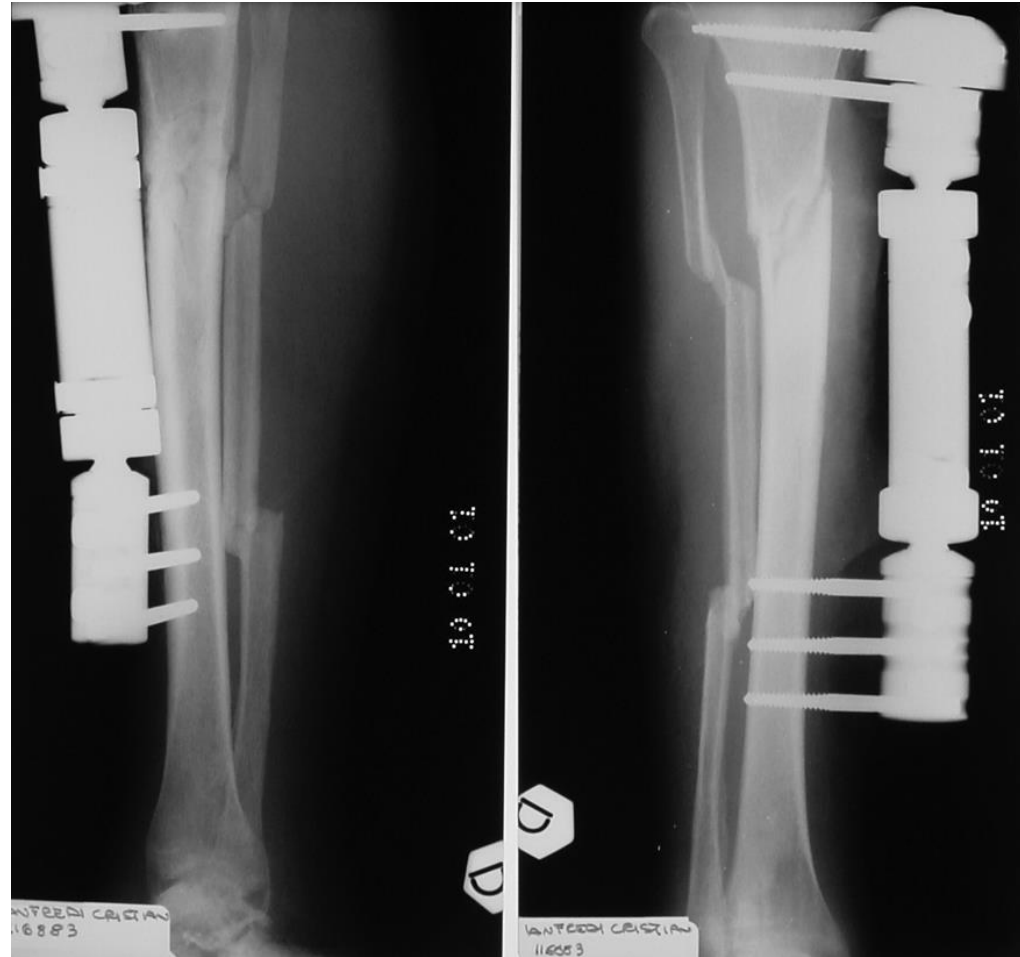
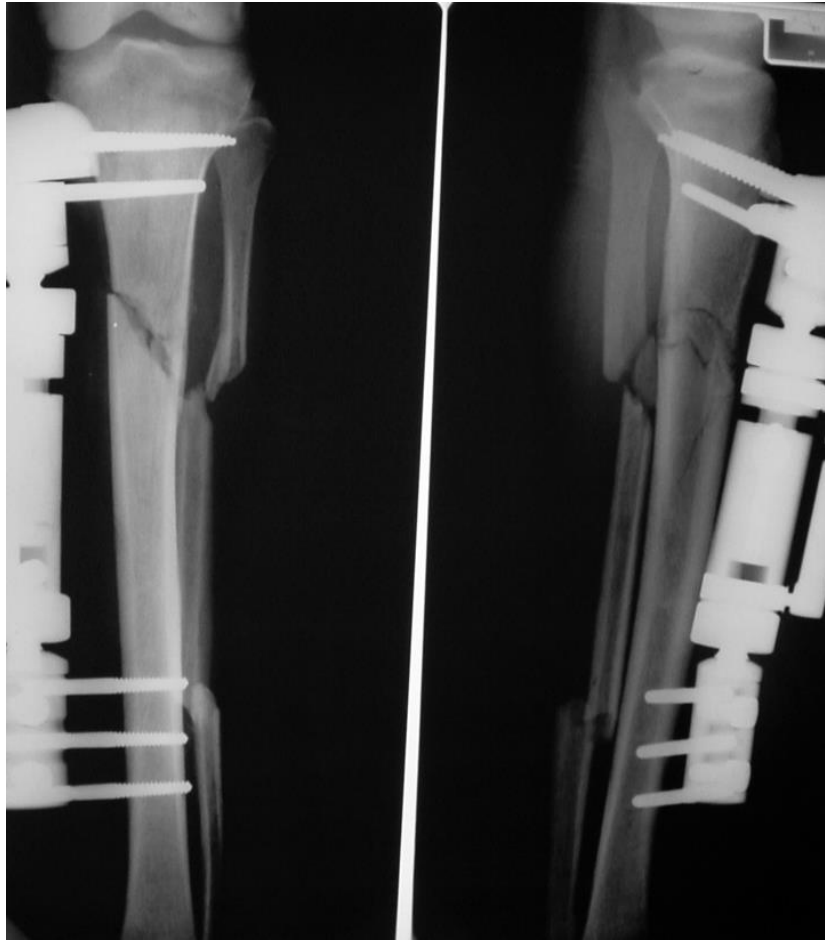Istituto Clinico Humanitas. Traumatologia - Sezione Fissazione Circolare

Male 27 y.o. Motocircle accident, open fracture with lost of soft tissue, lesion of the muscle branch of the post tib. artery

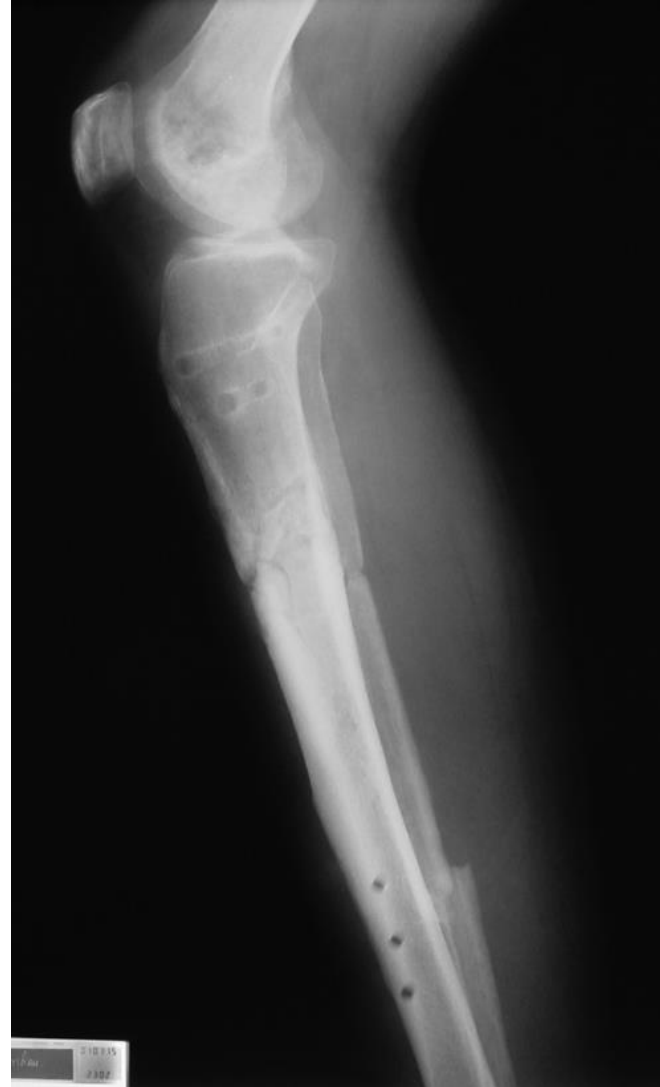
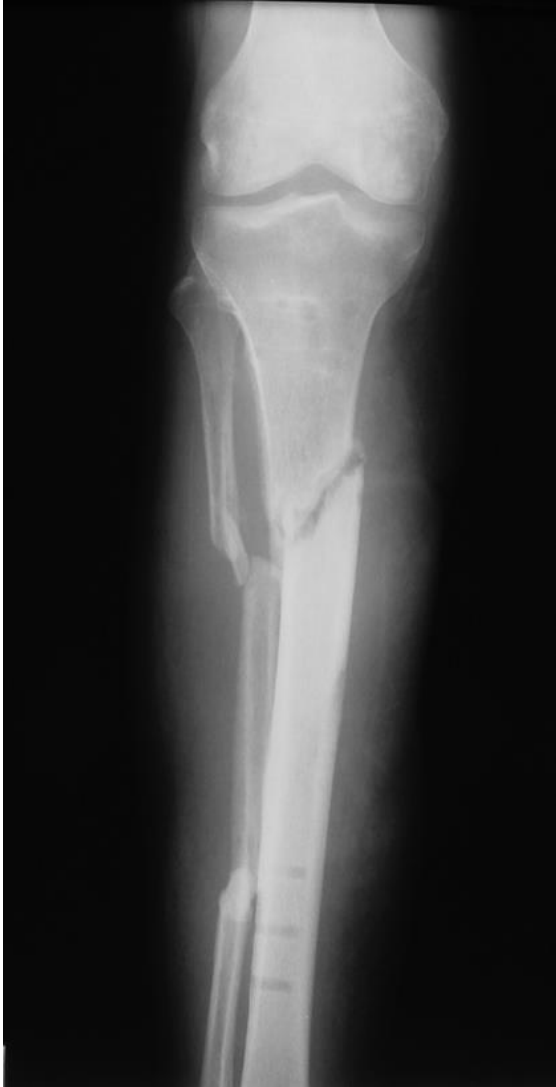


3 months with monolateral frame



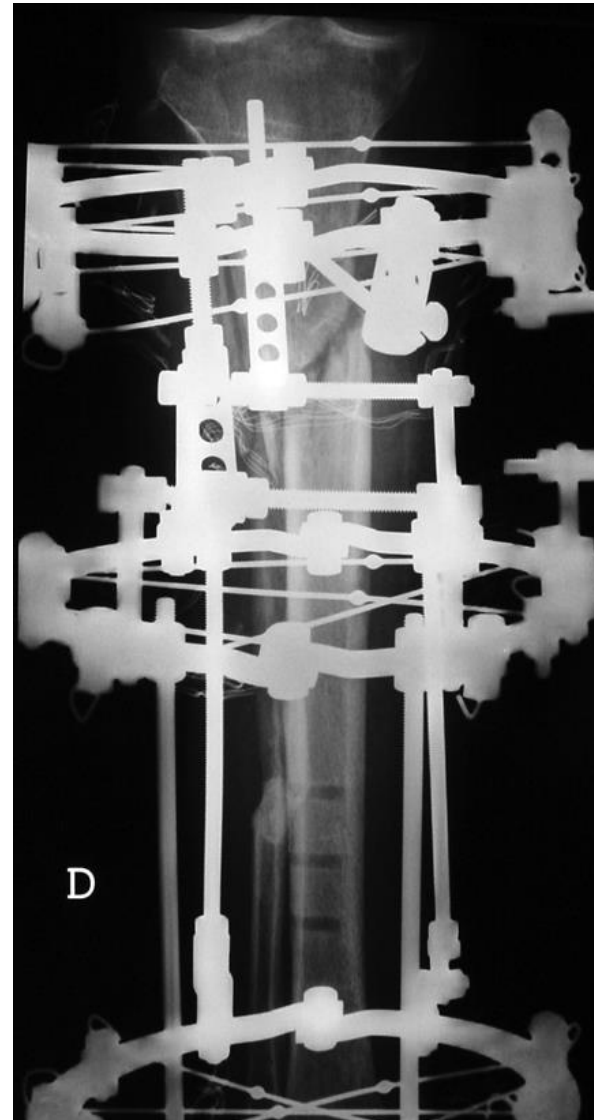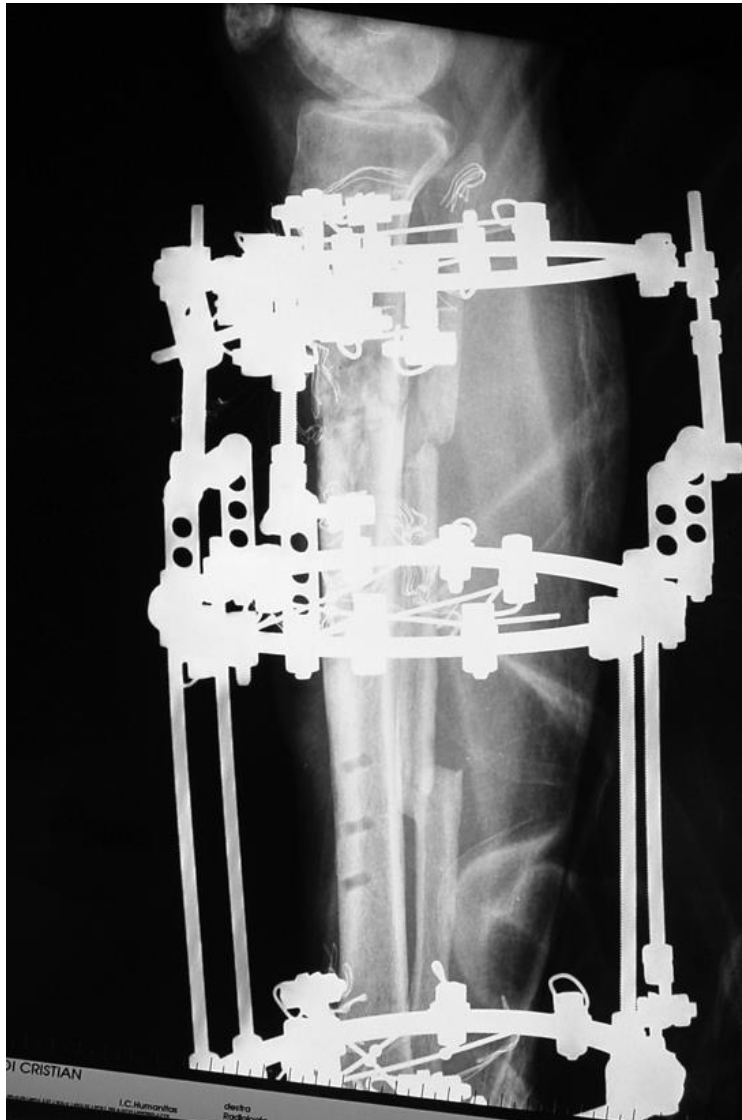
After 6 months frame was removed,
infection and pseudoarthrosis of the tibia




Treatment
plan?


- Plate
- Nail
- Bone graft
- Other?

Treatment with Ilizarov closed method by compression, 7 month after trauma.




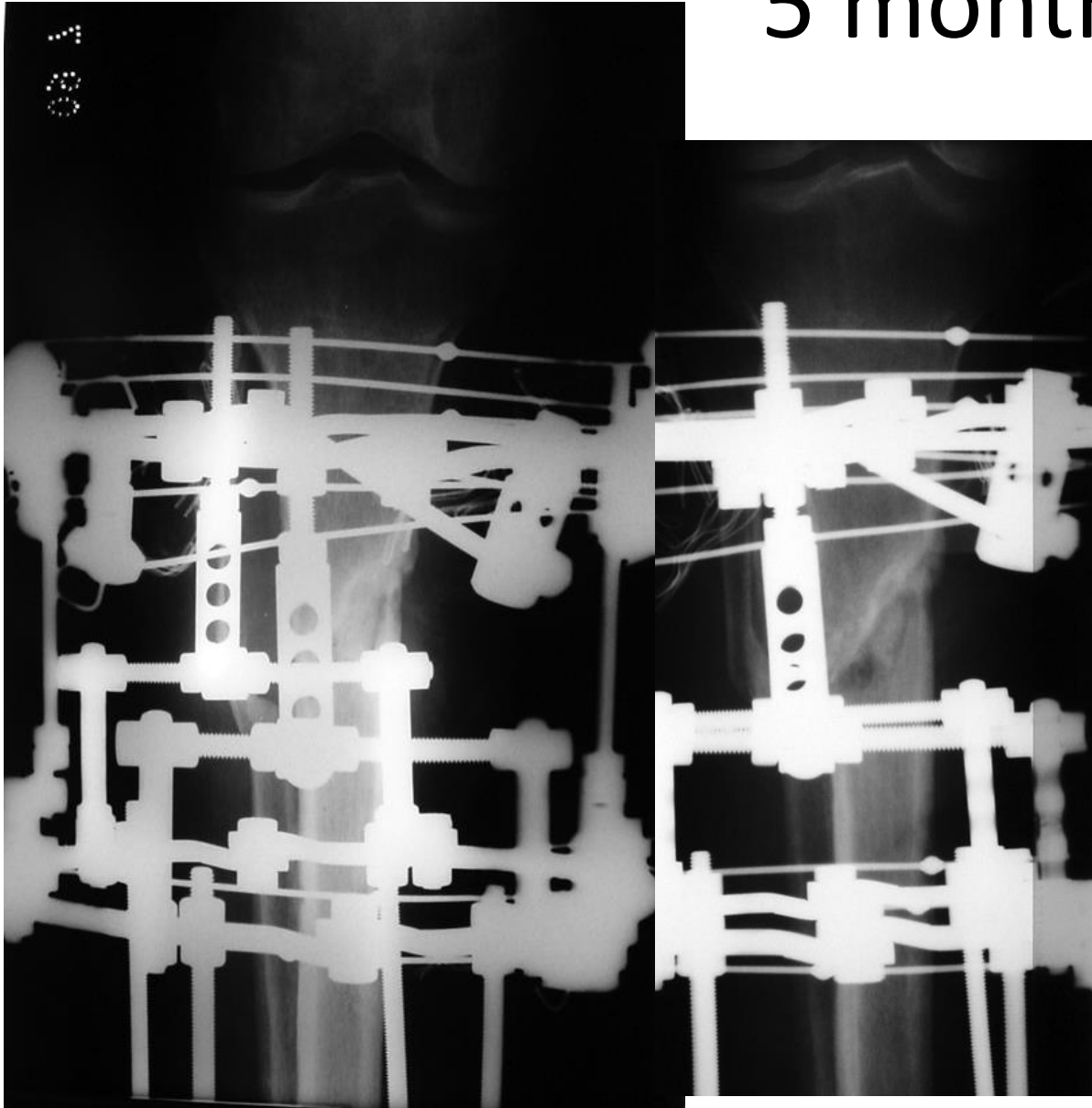


Progressive lateral compression
2 month of Ilizarov



Progressive
realignment

5 month

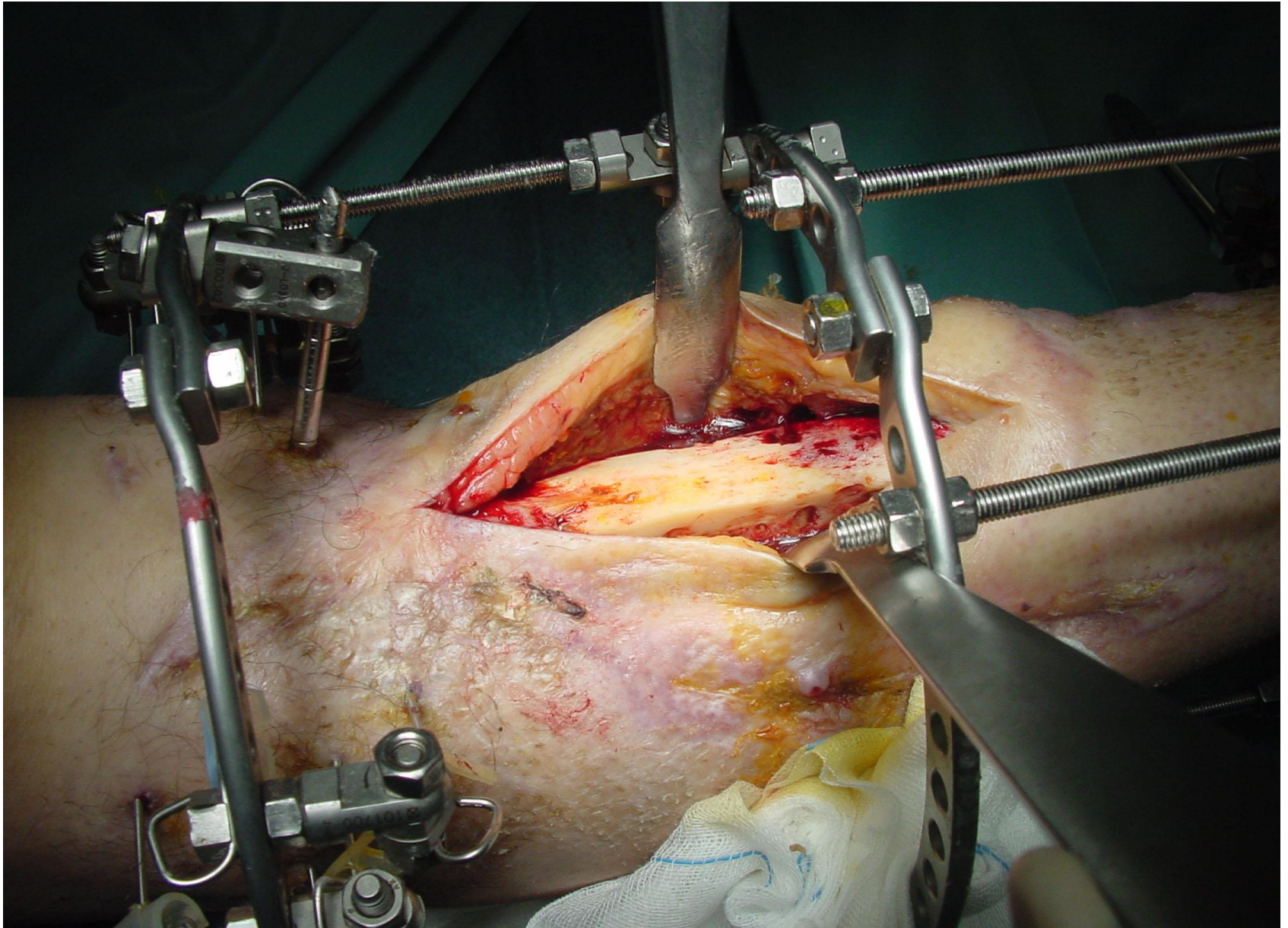


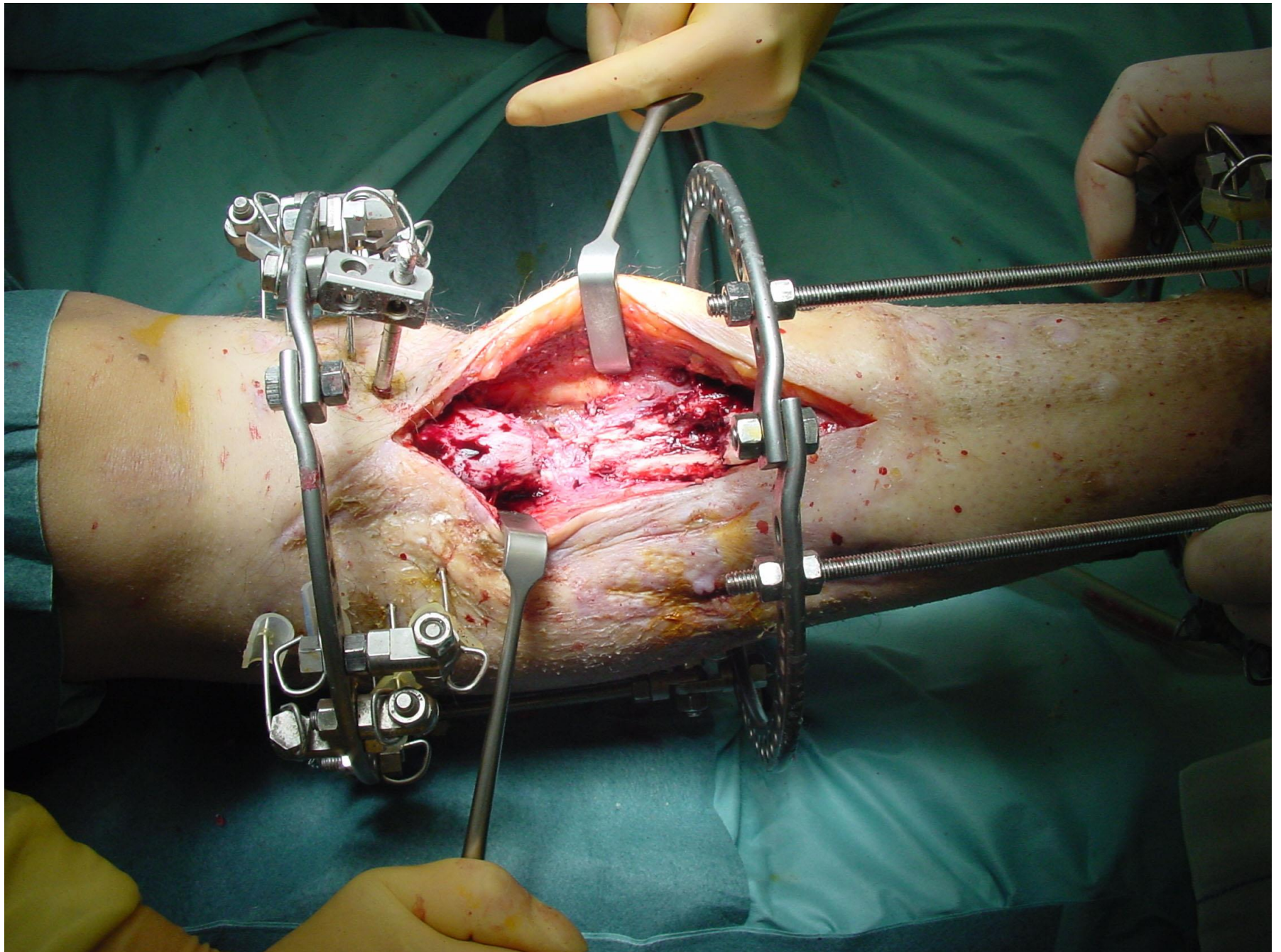


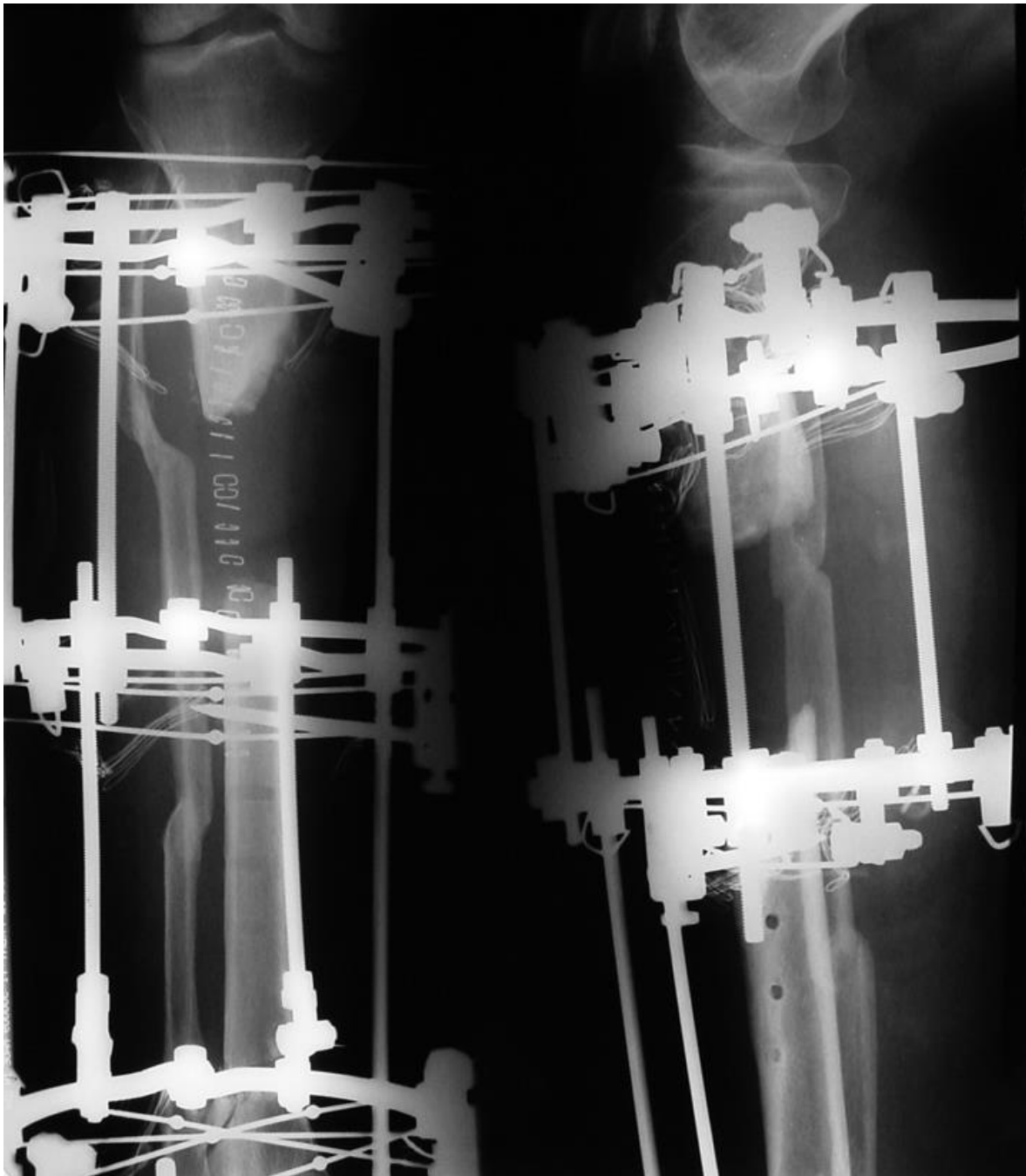
6 month,
infection around
the wires

- What to do
Cosa fare?
 - Plate
 - Nail
 - Bone graft
 - Other?

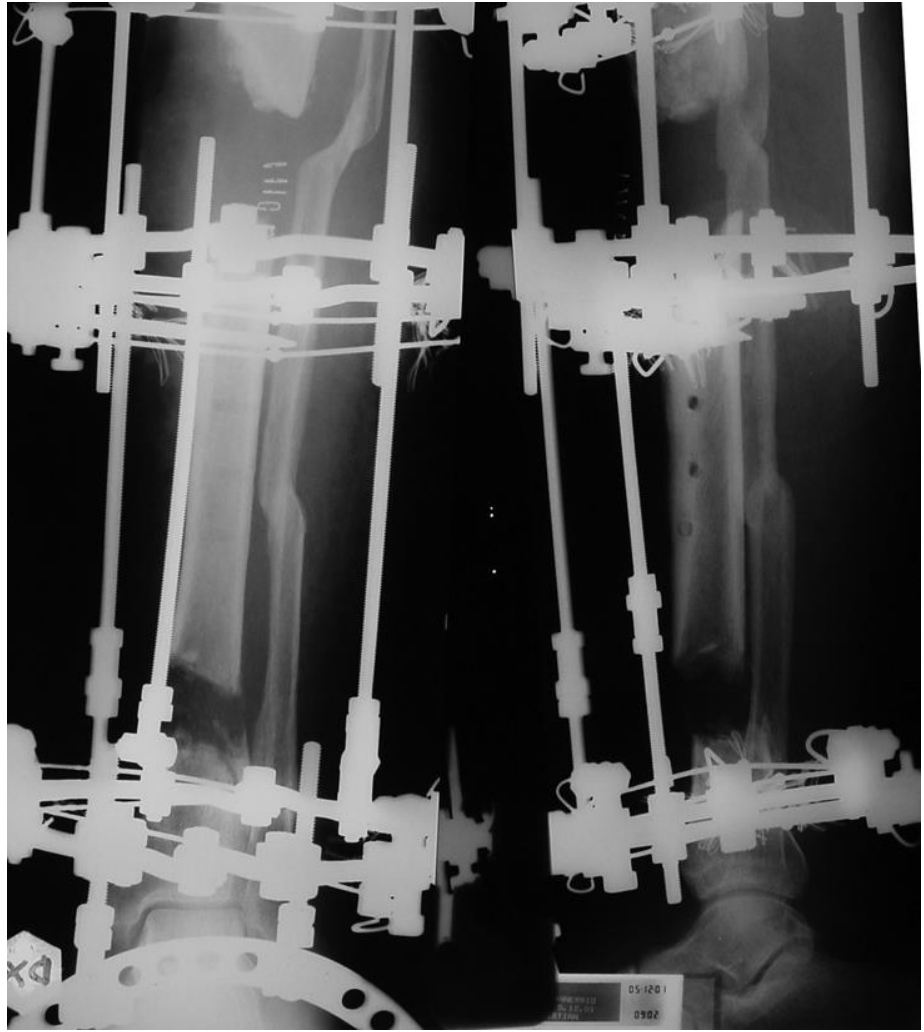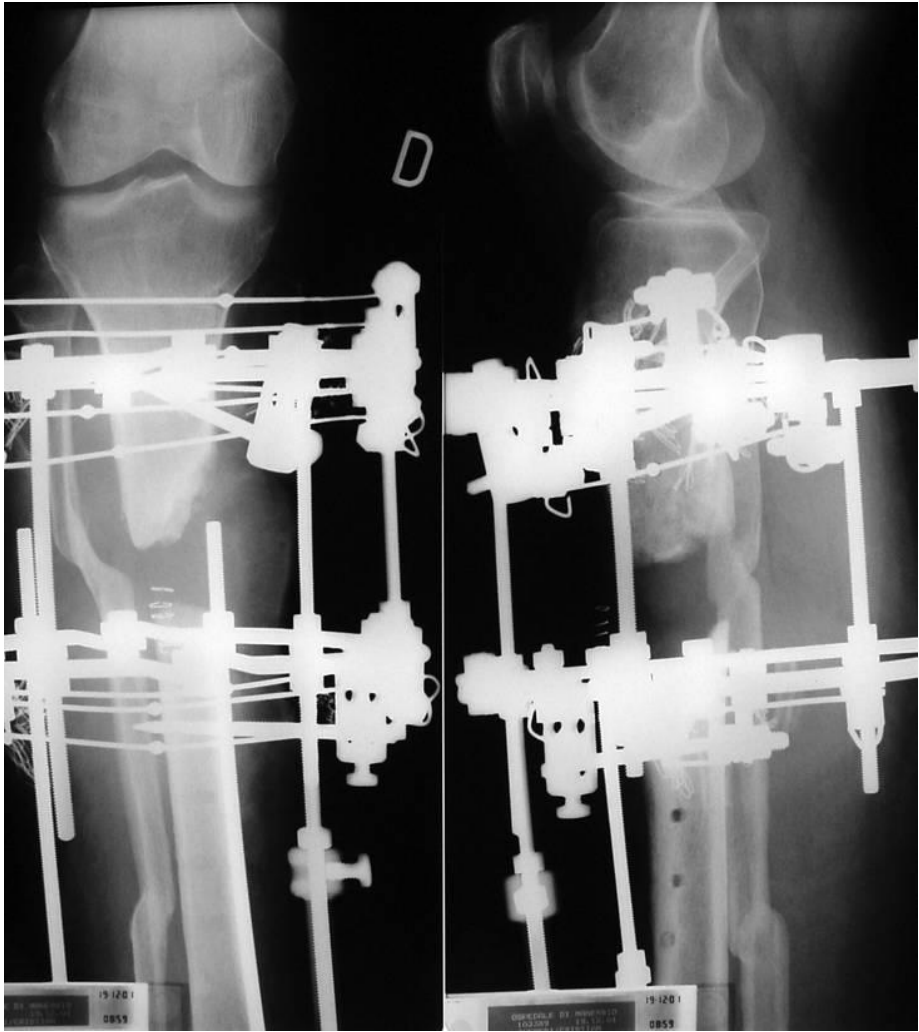Surgical revision, necrosis of the proximal 1/3 of tibia!!

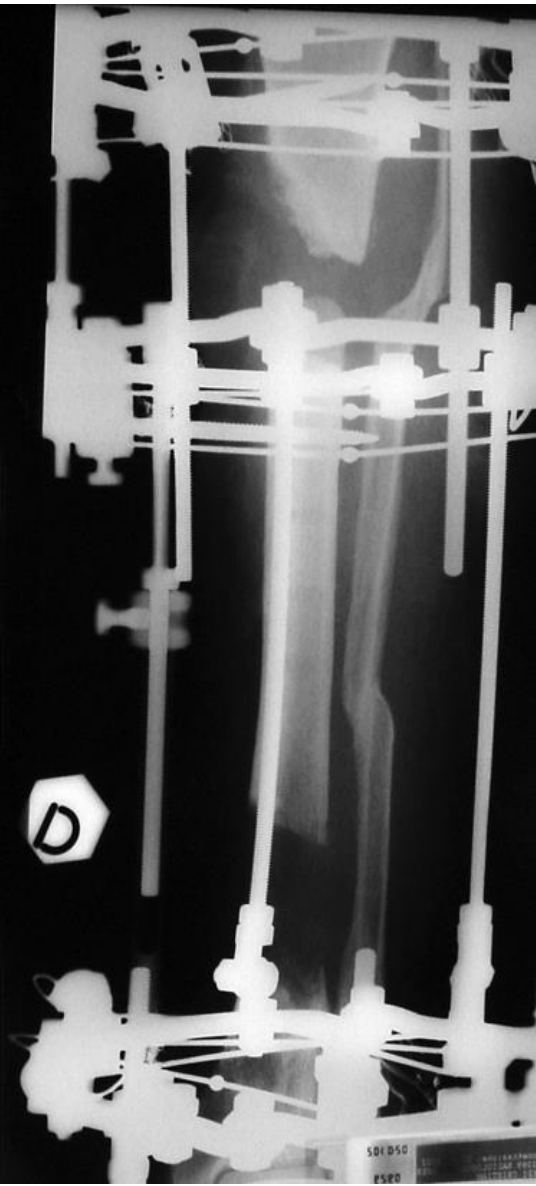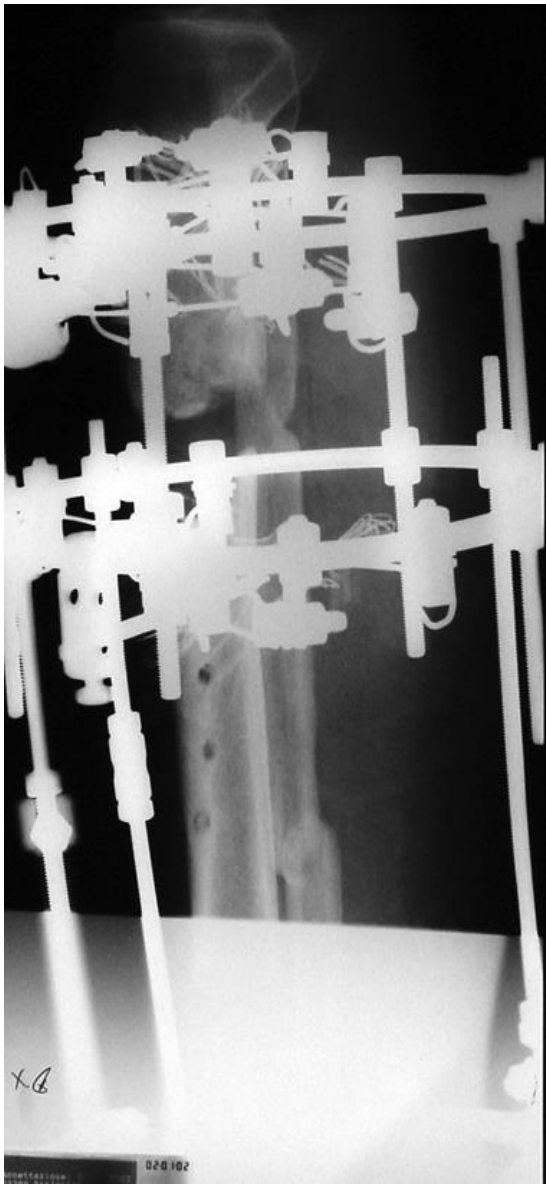



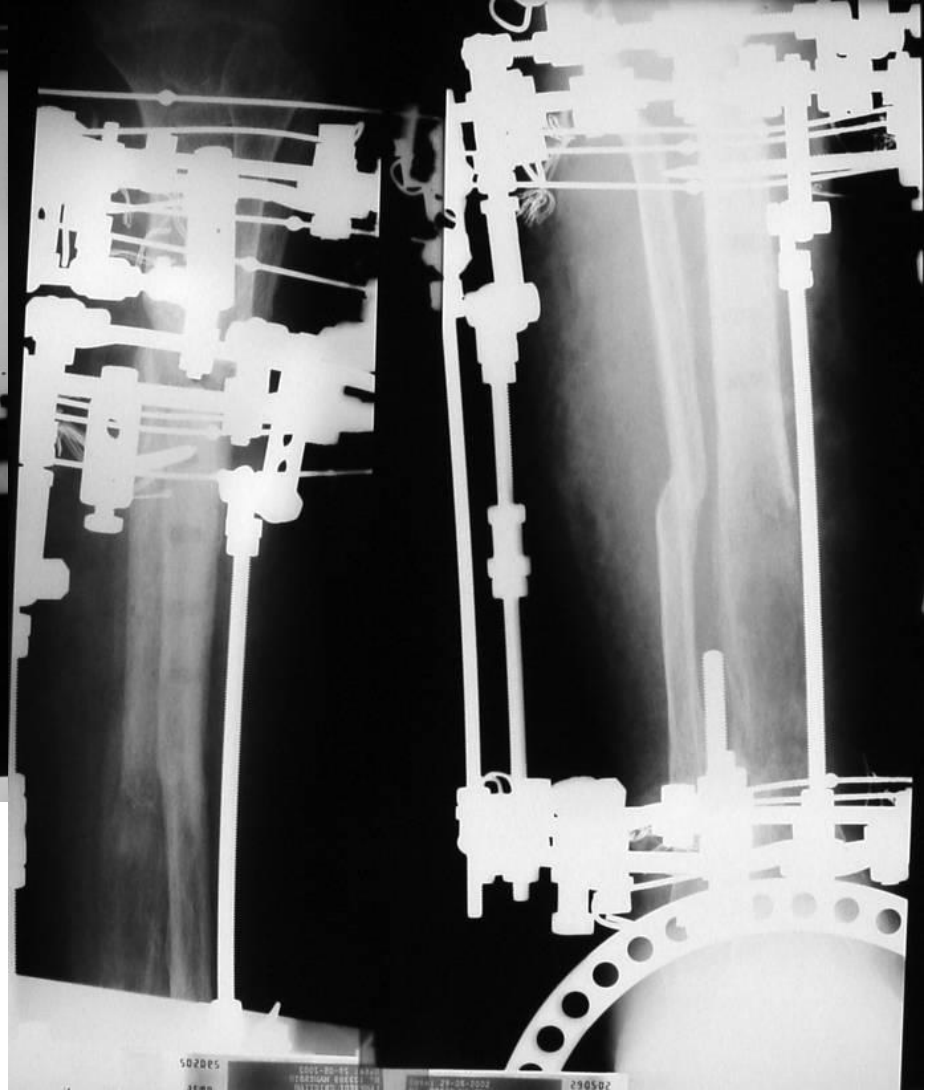
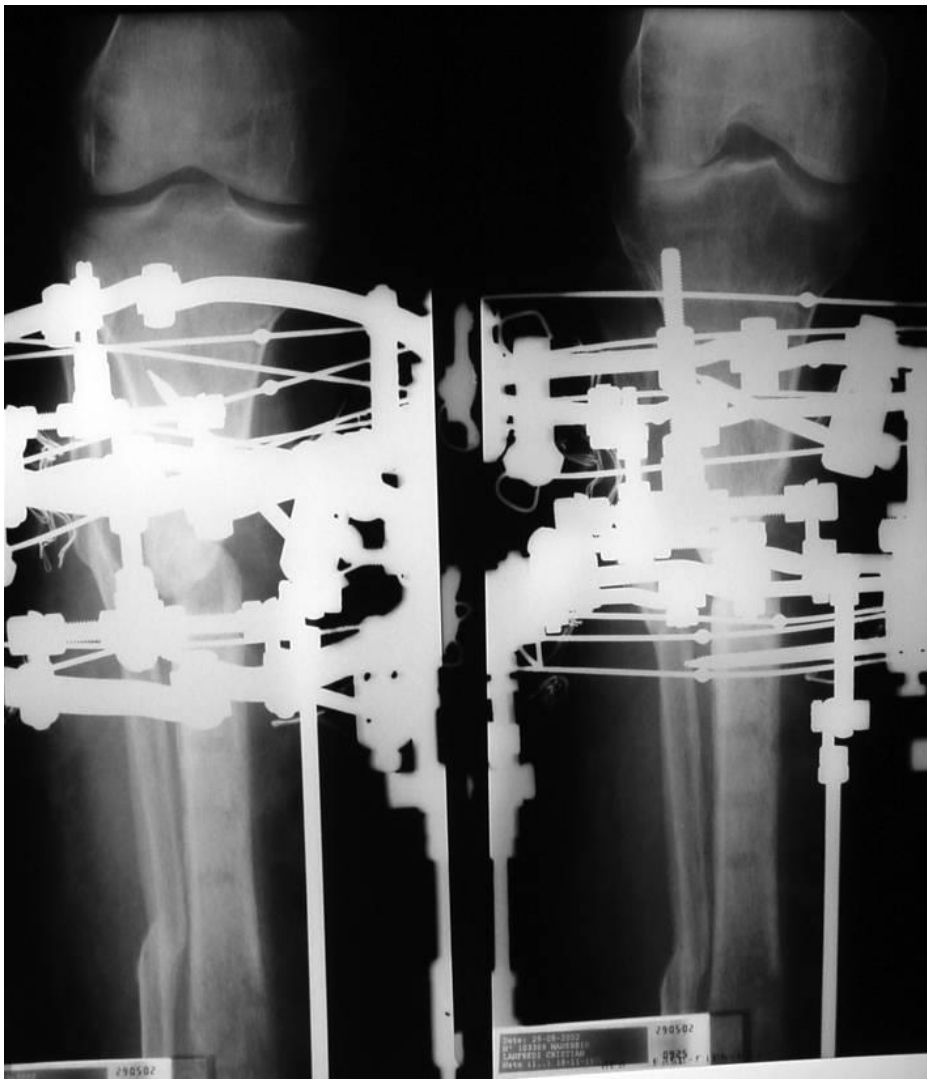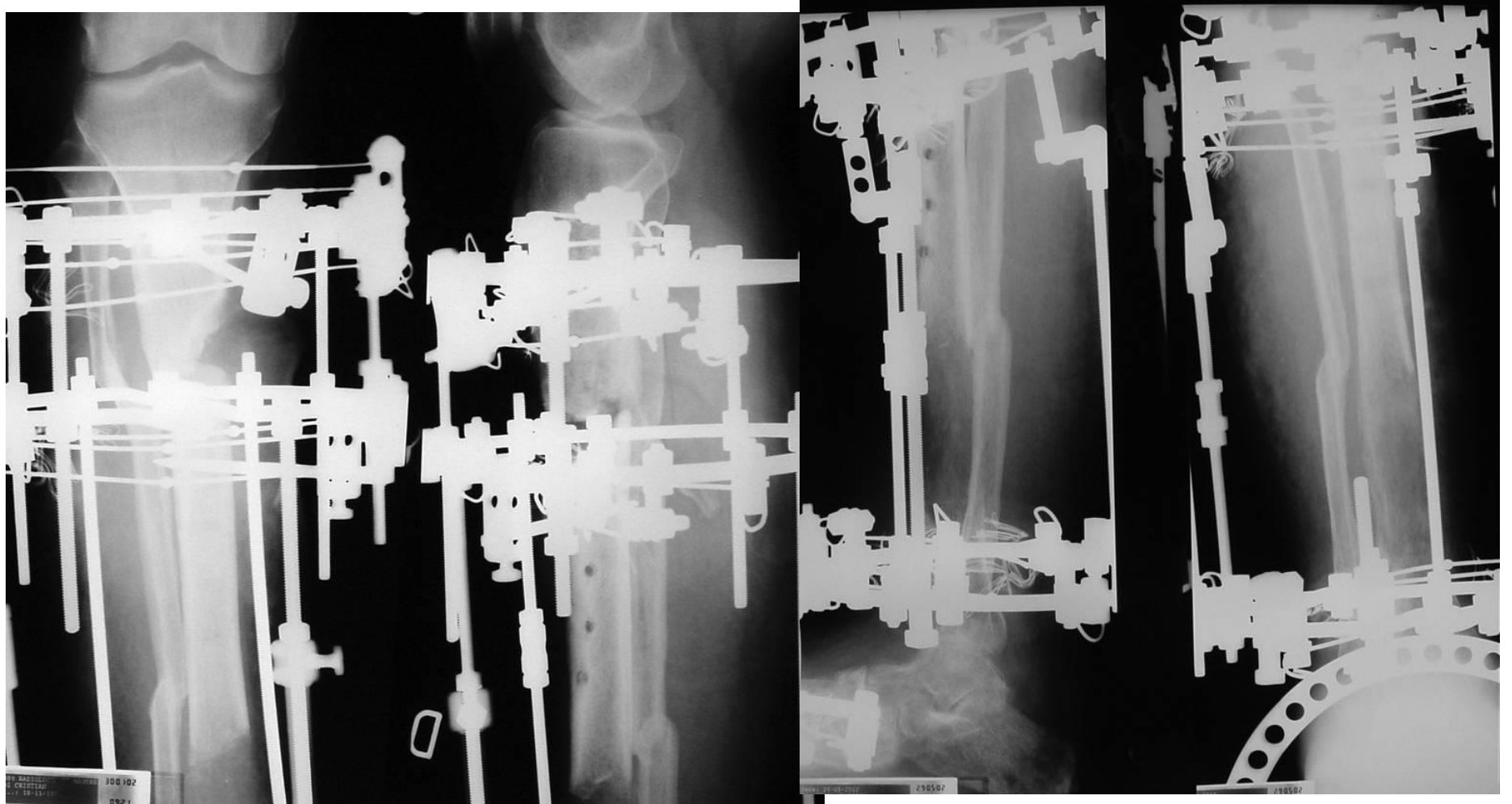


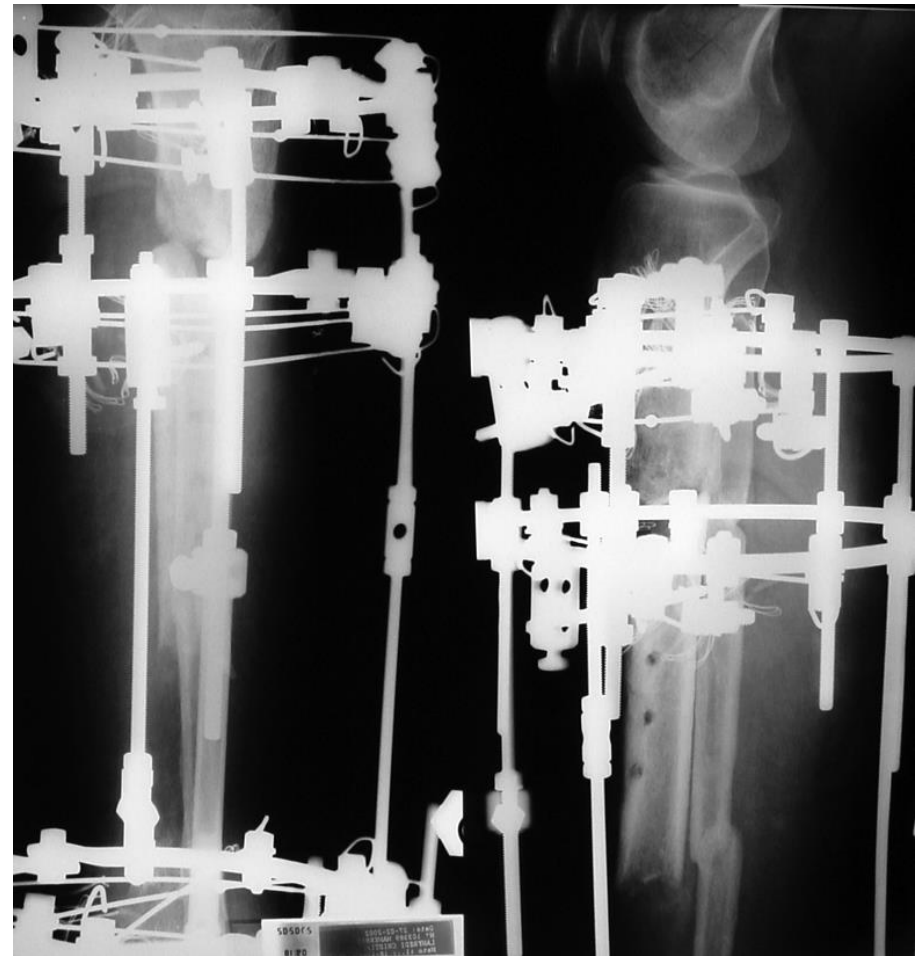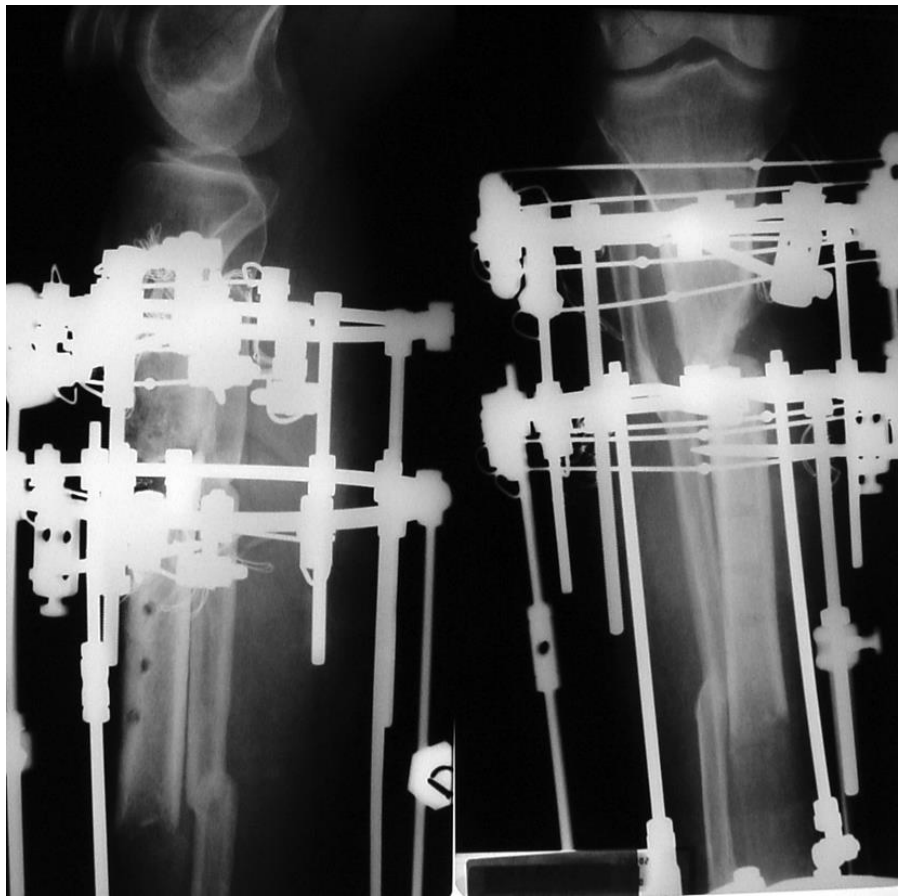Bone
transport

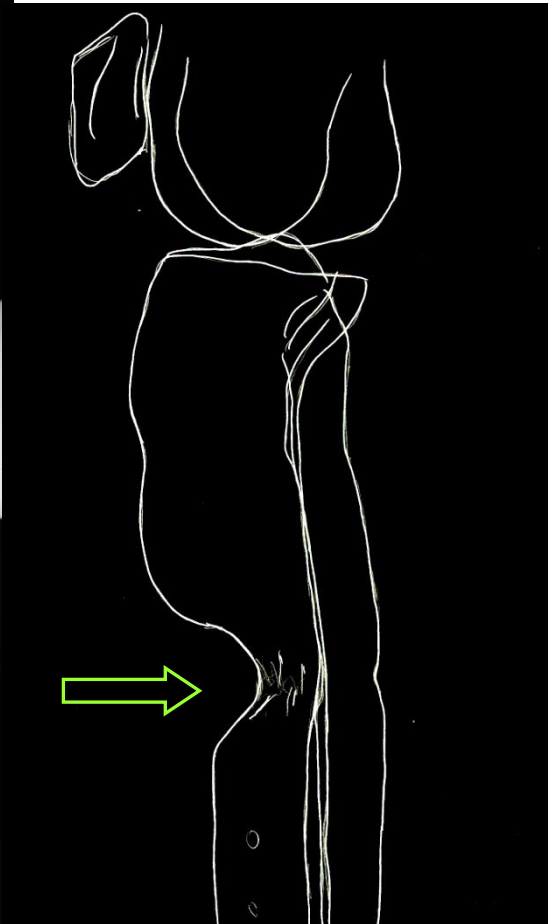
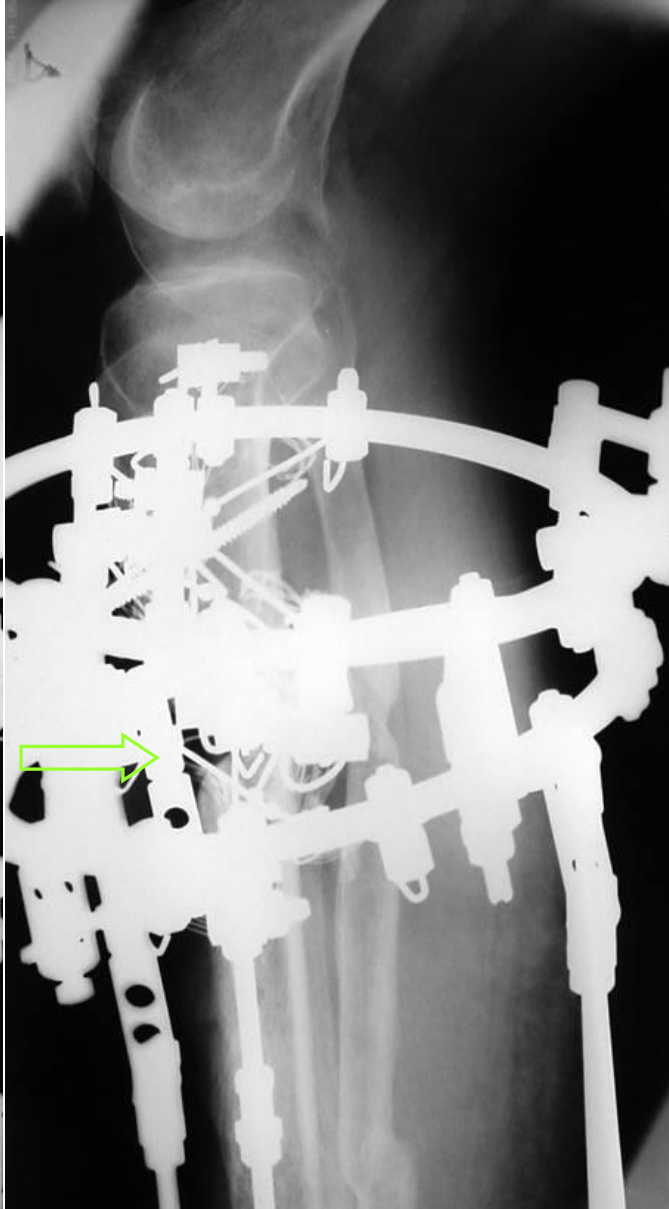
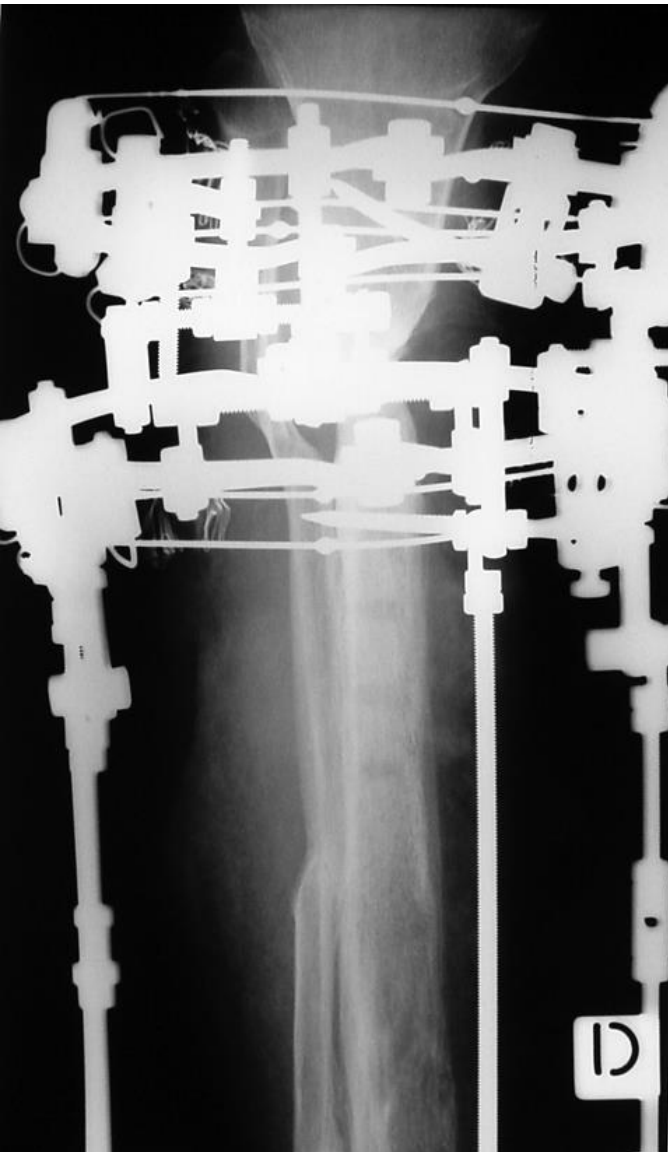





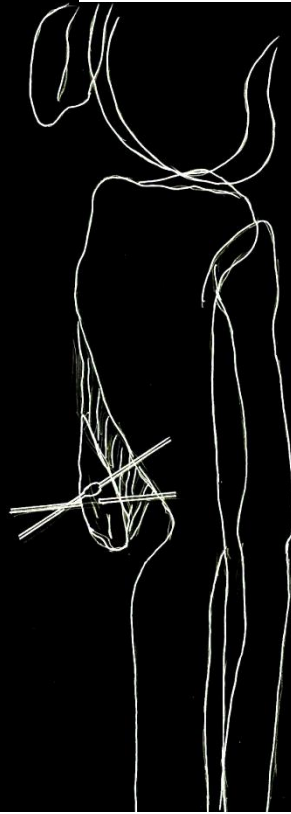
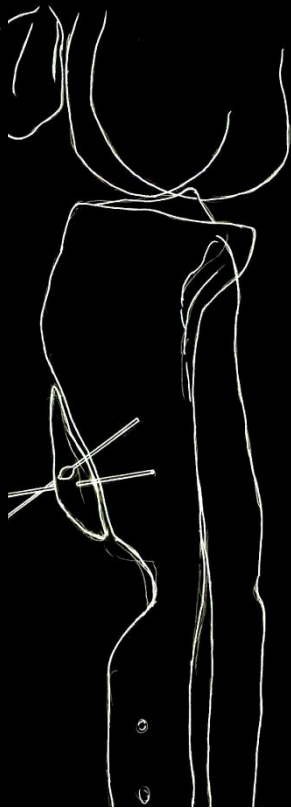
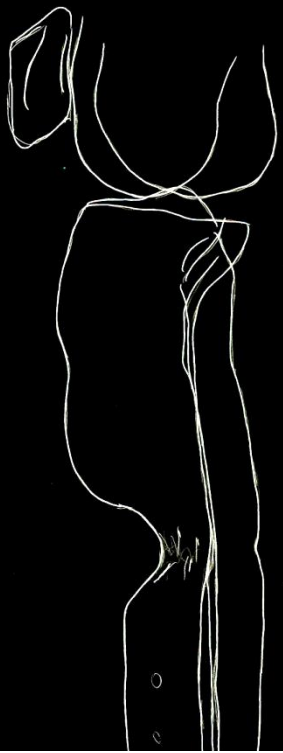


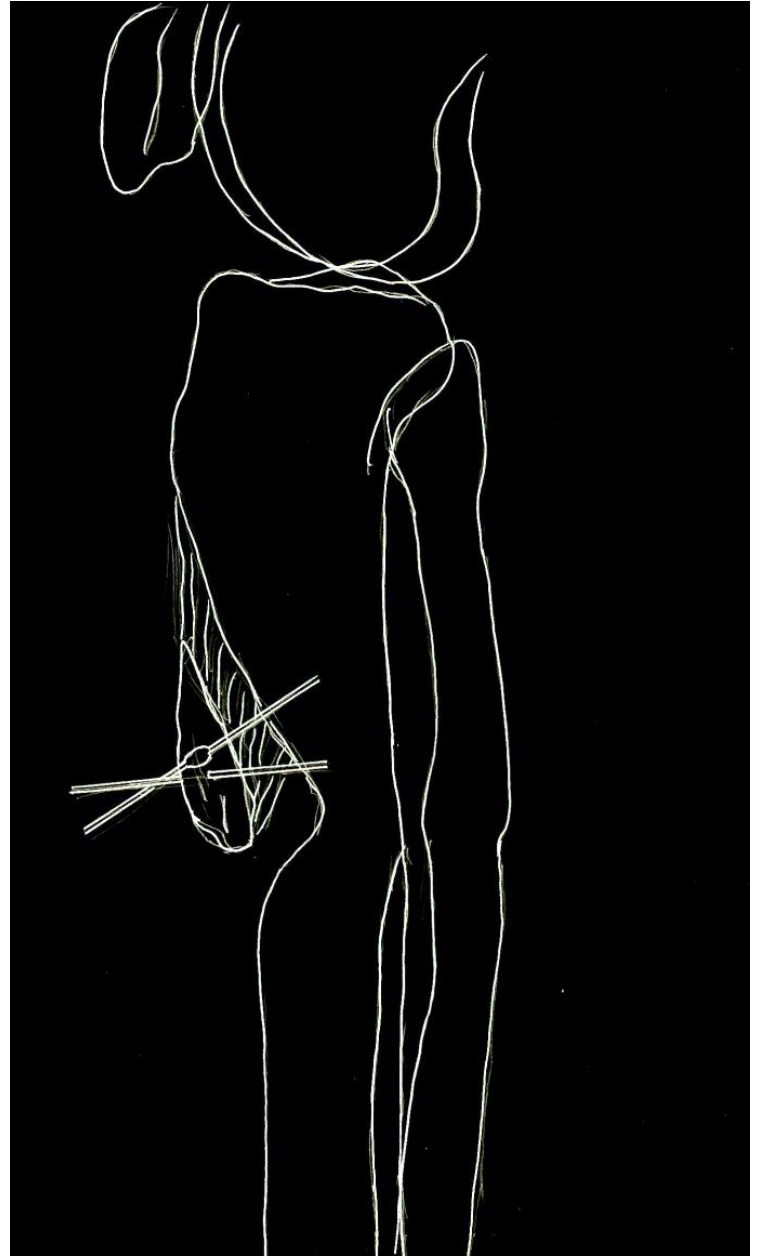
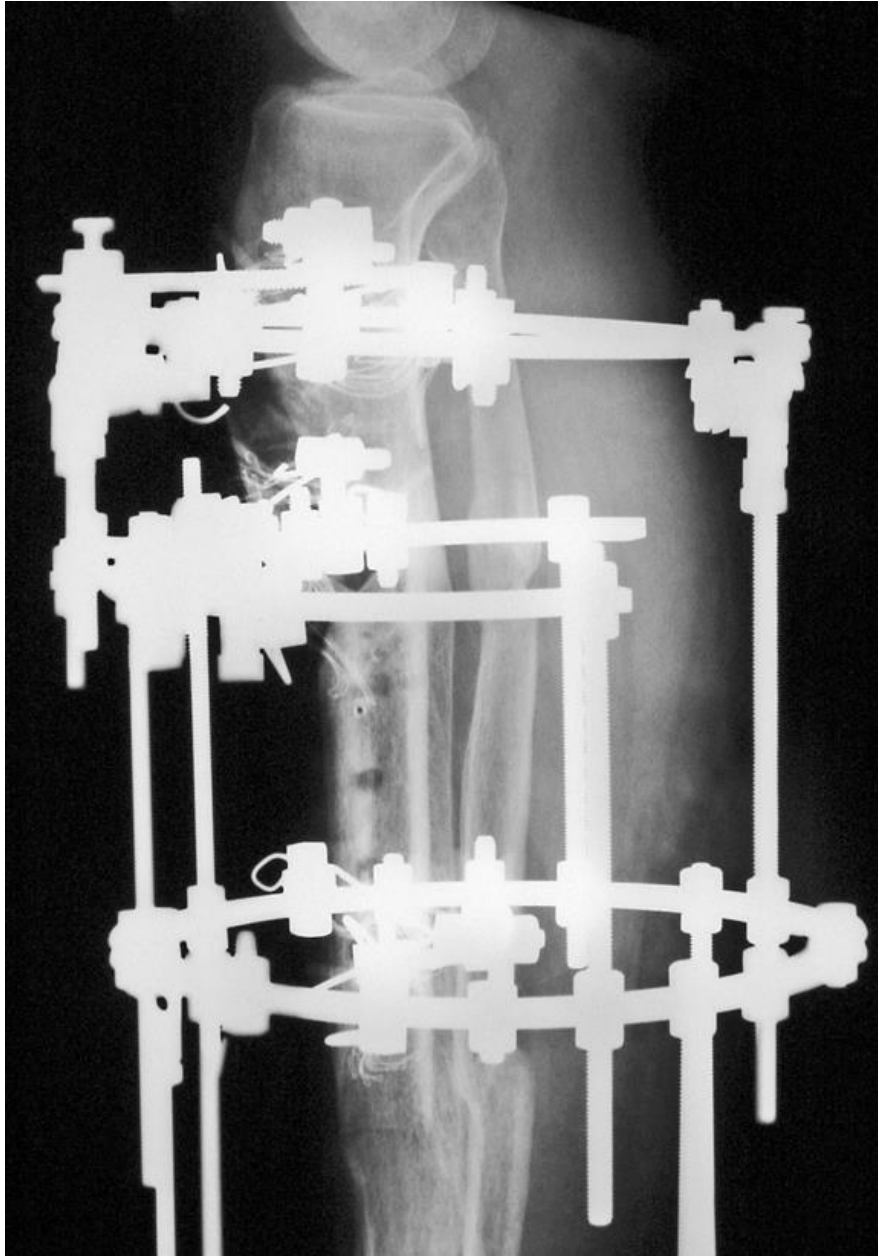


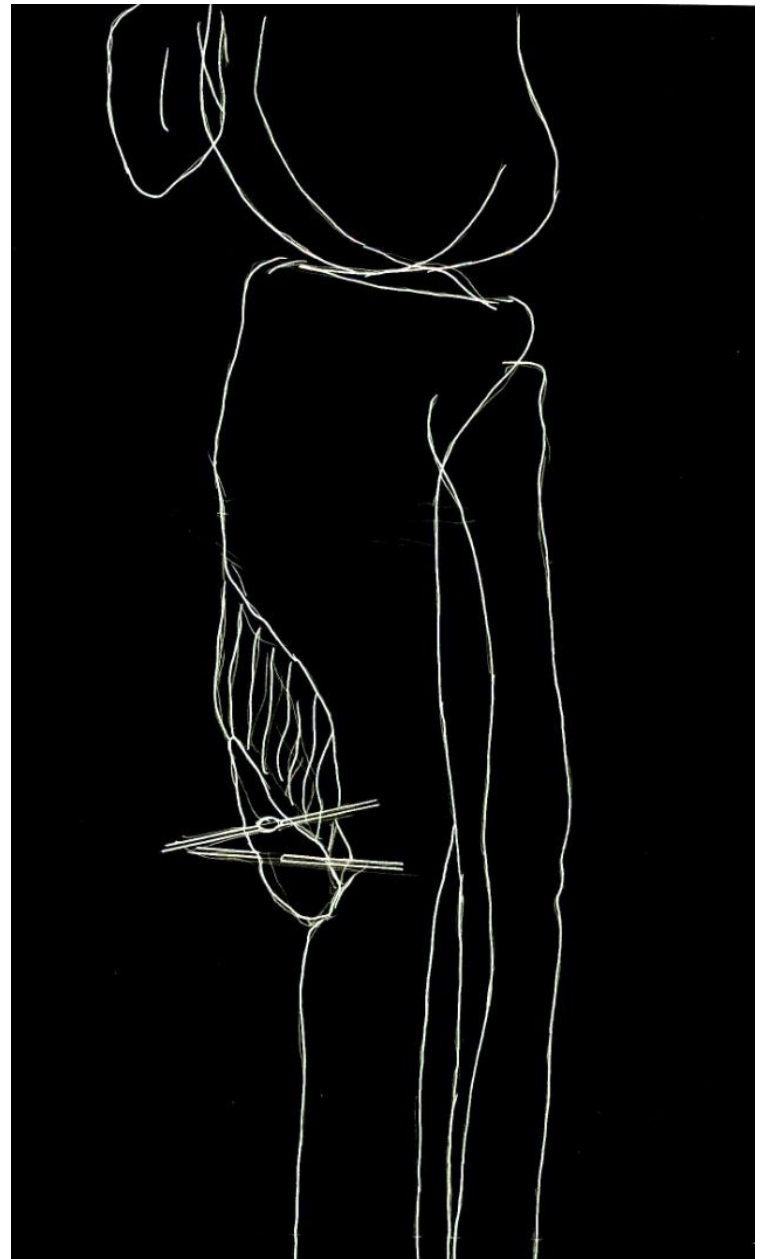
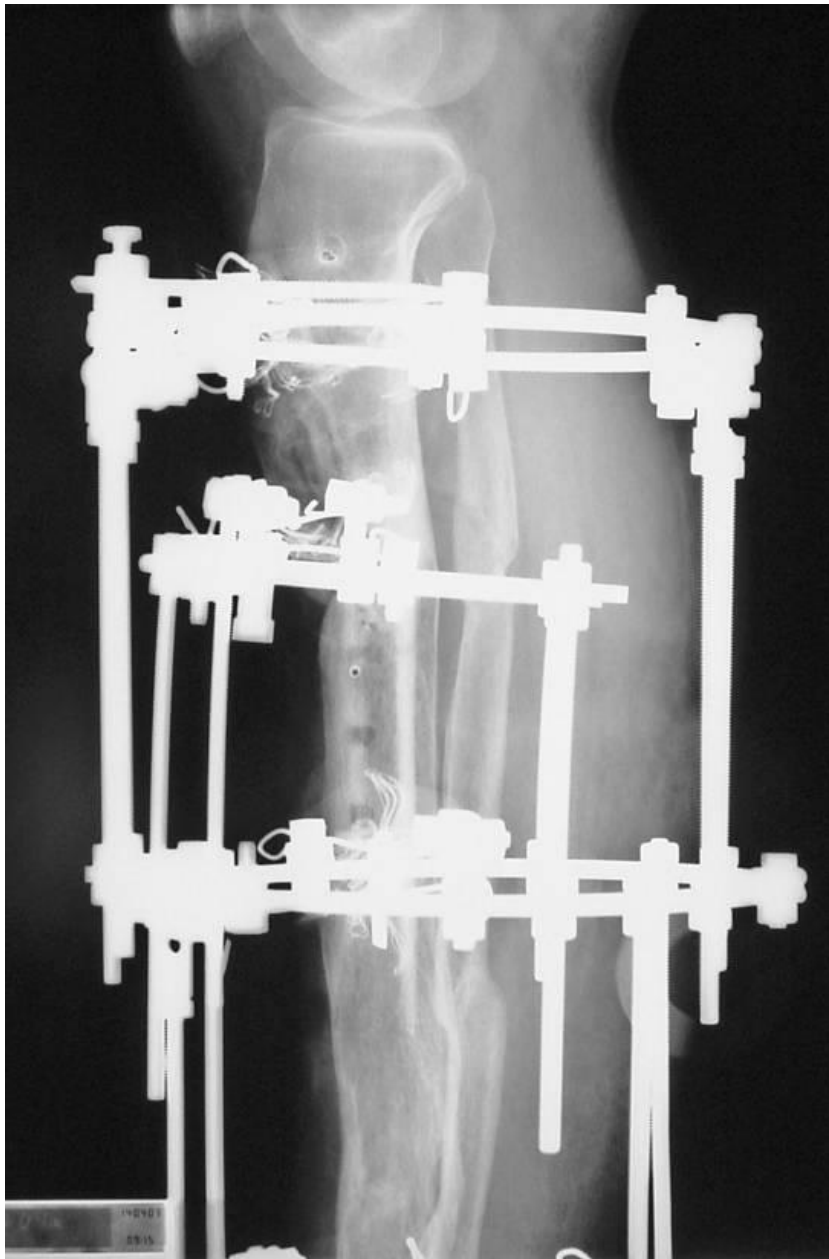


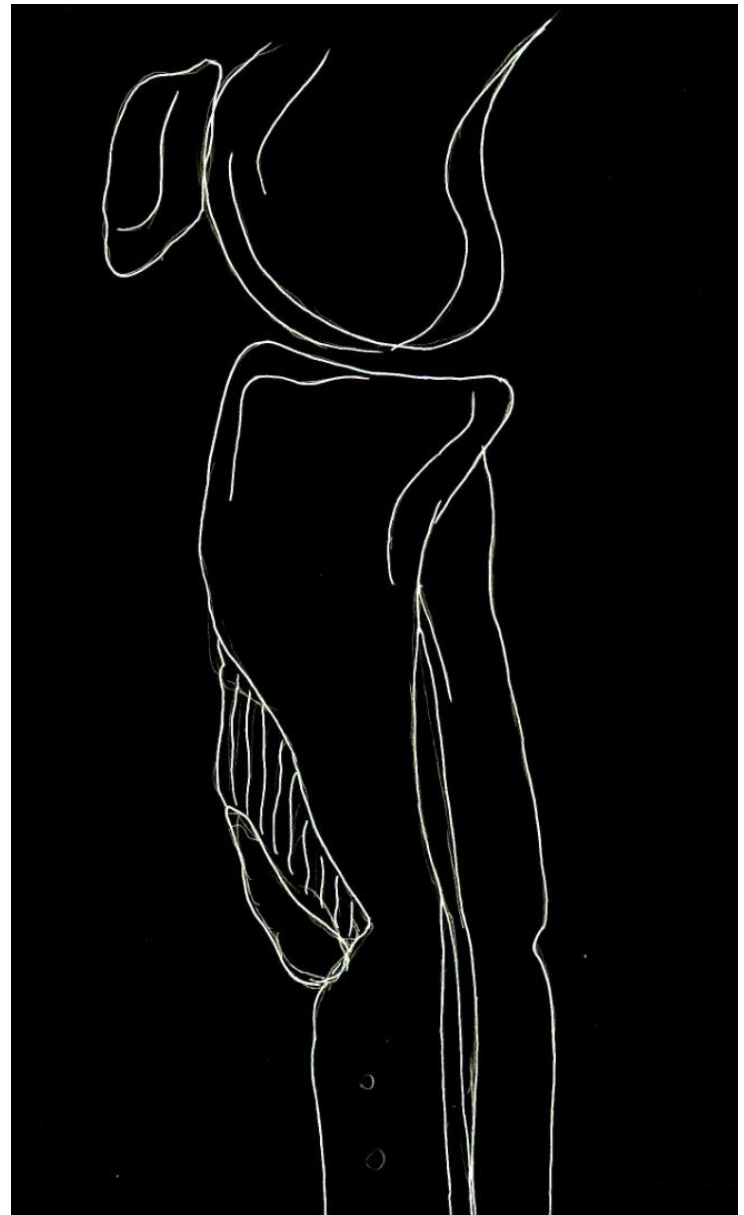
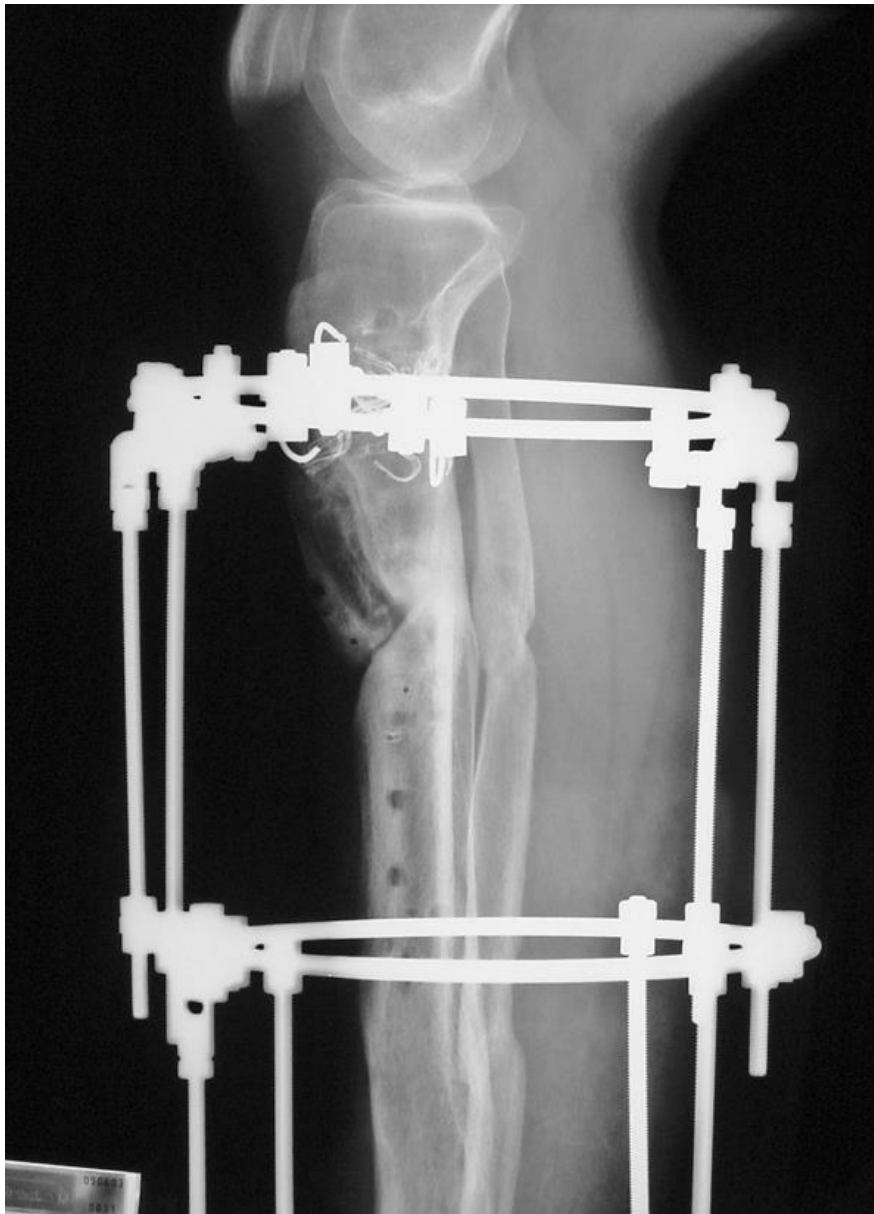
- What to do?

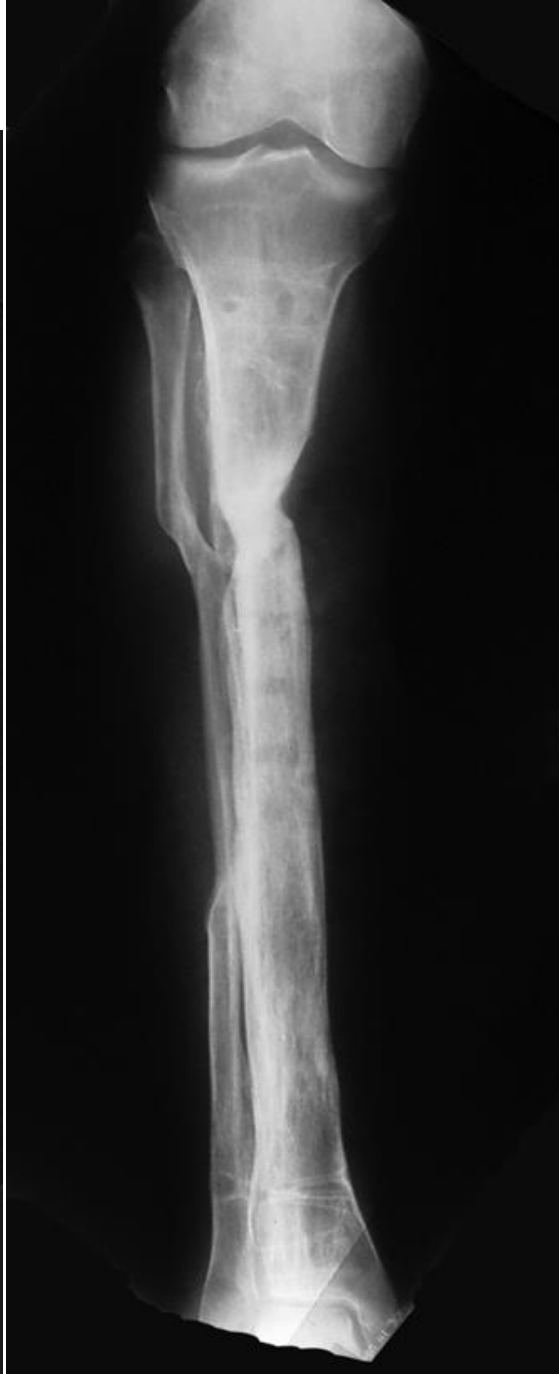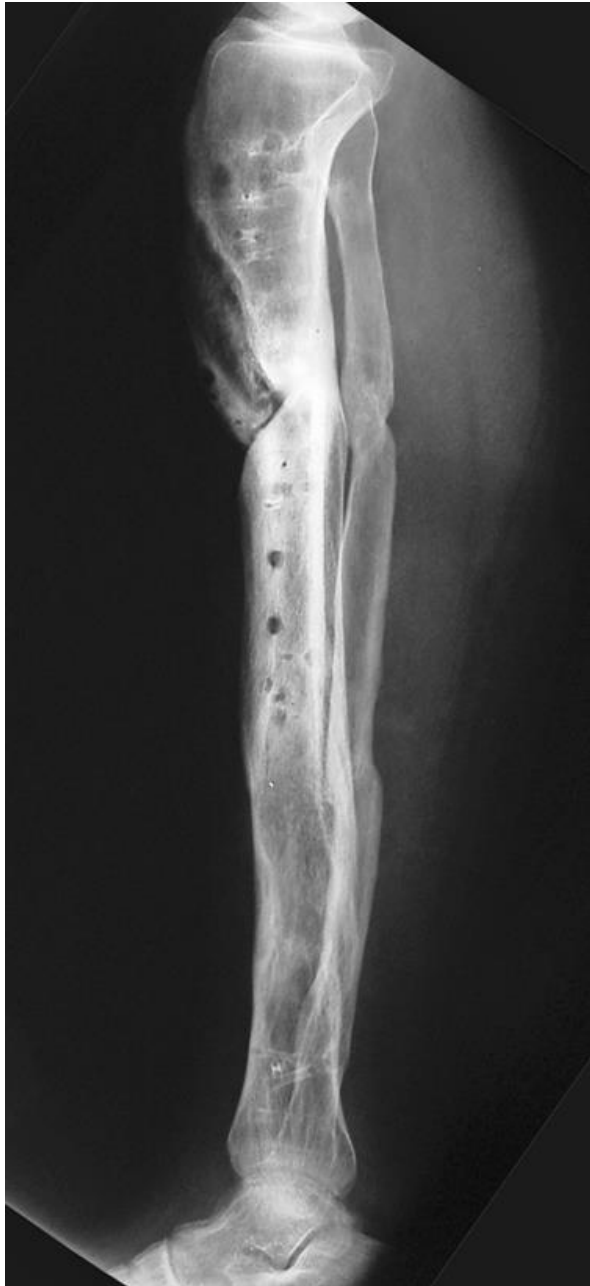Plan transport of cortical fragment for closing anterior difect





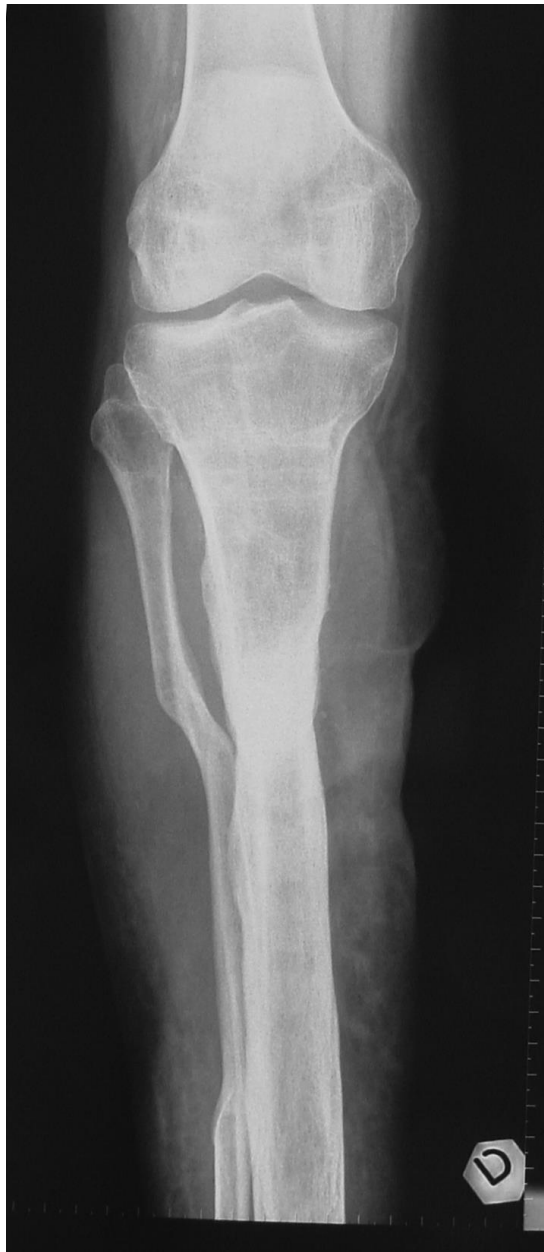
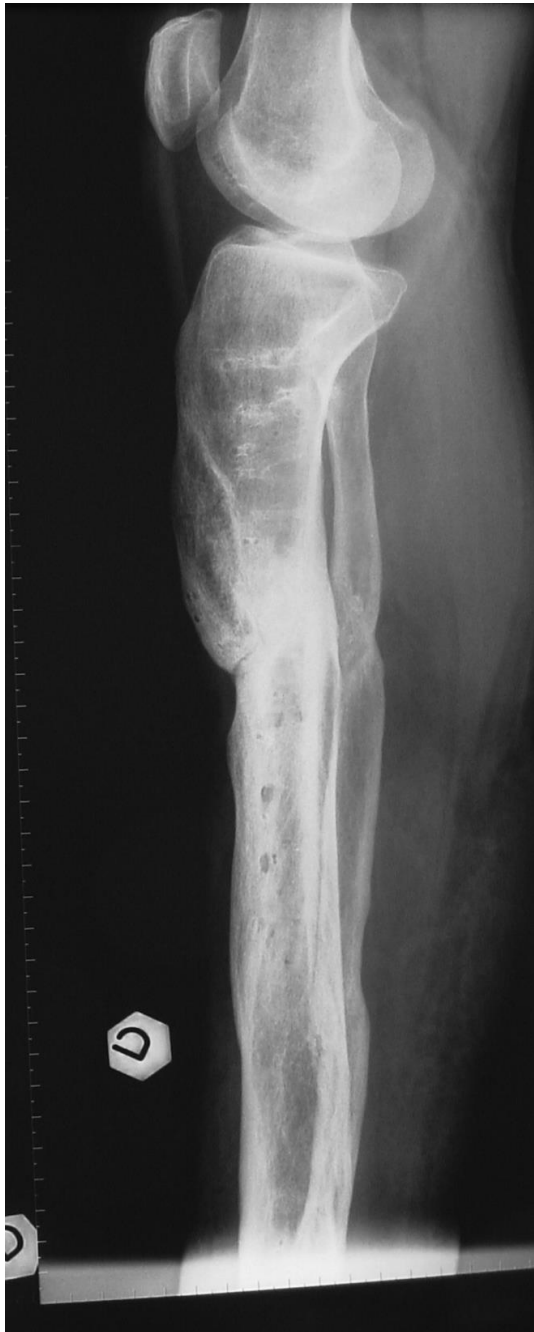




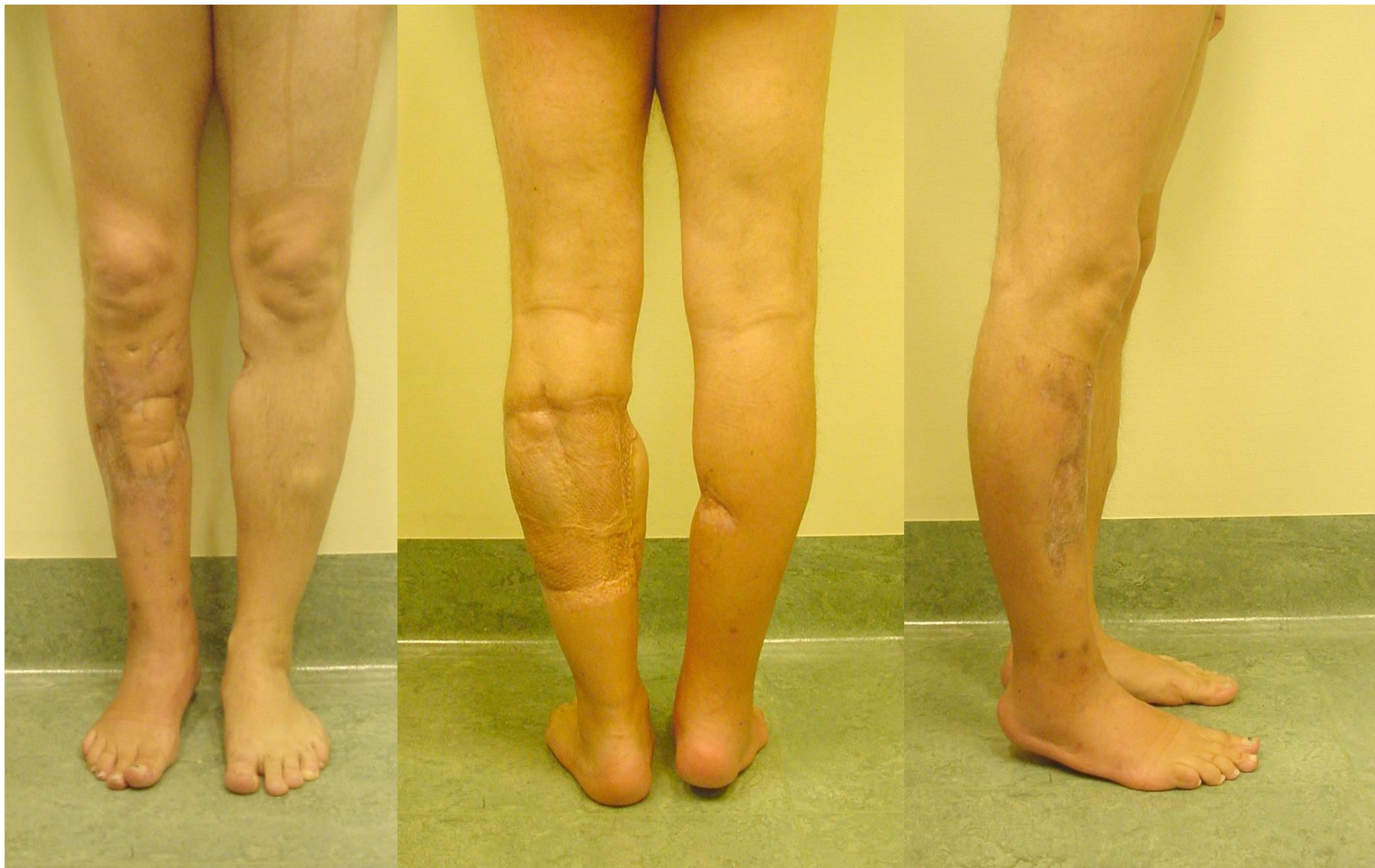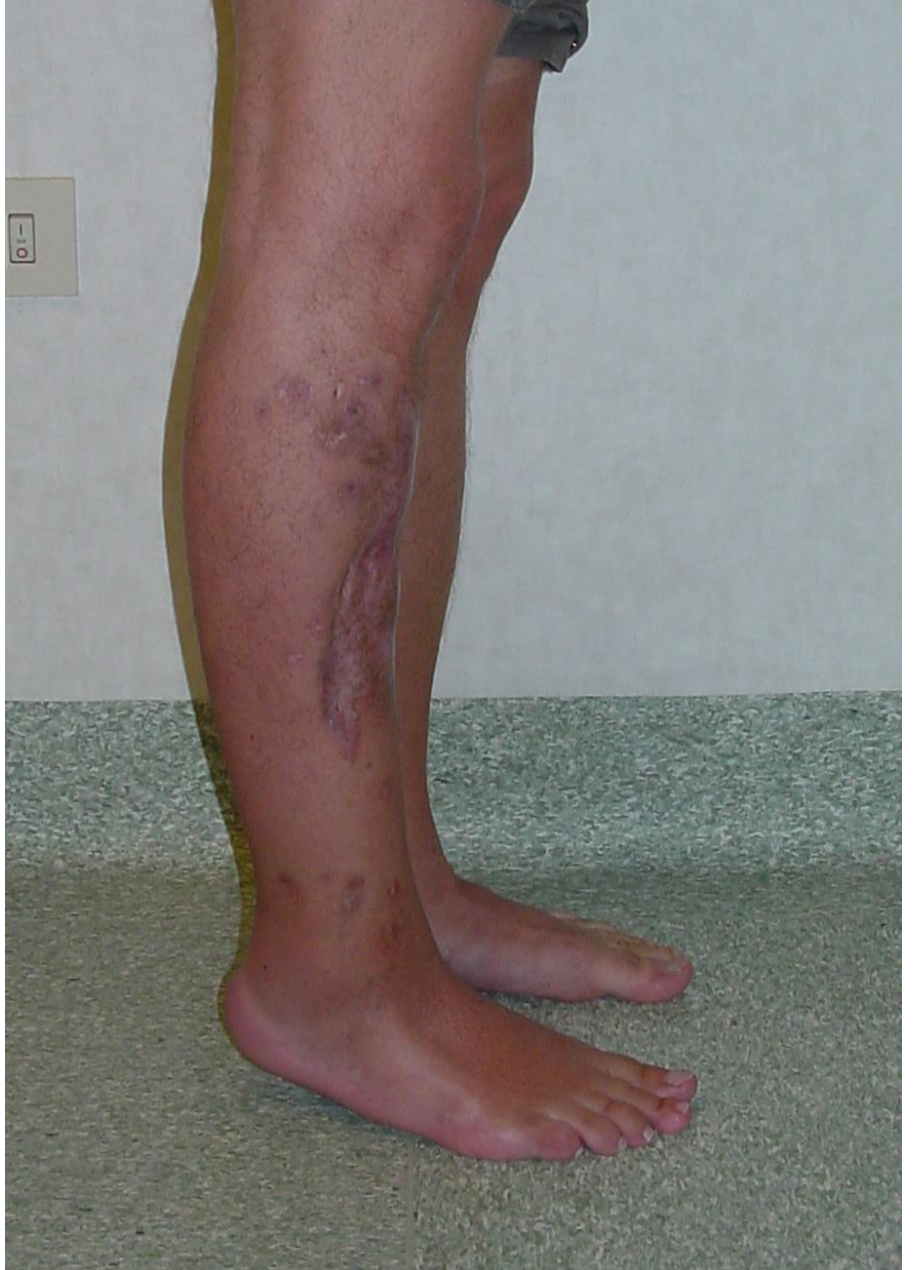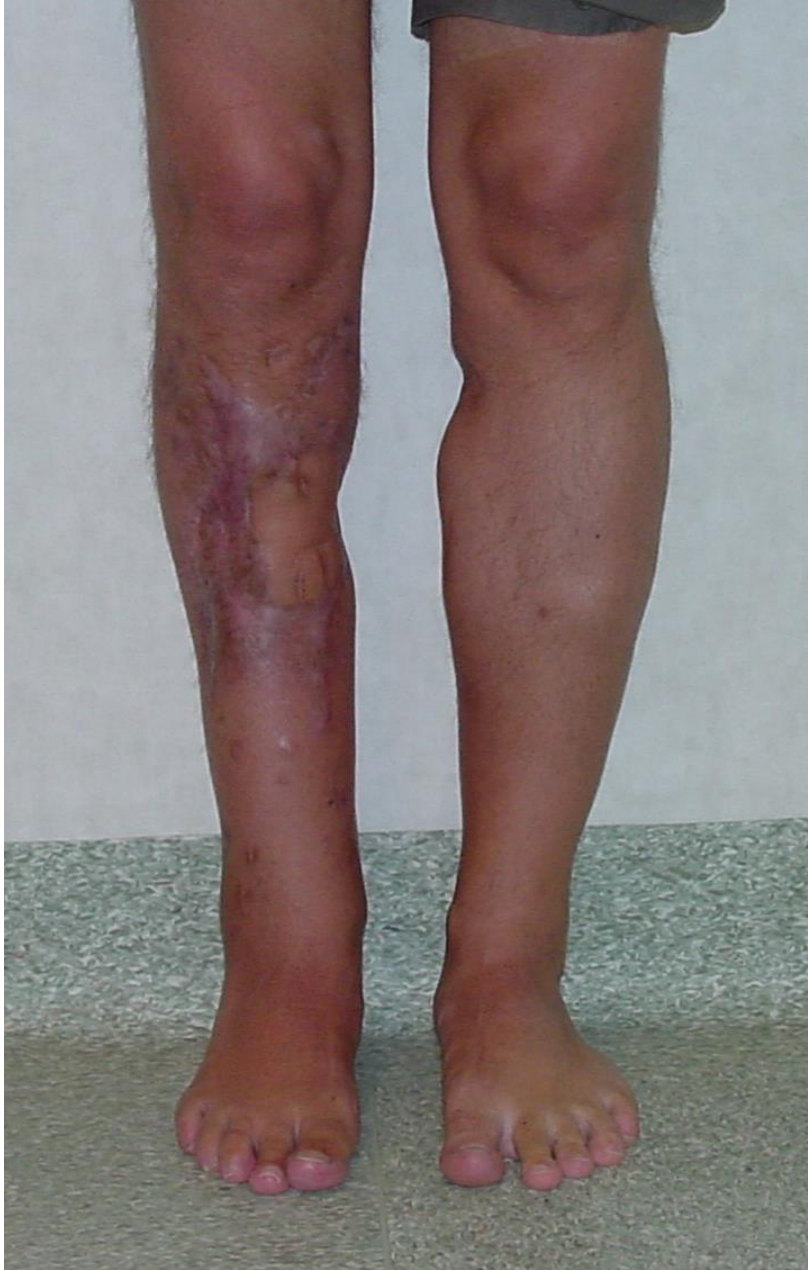2 month after
removal the frame

3 years
Follow up



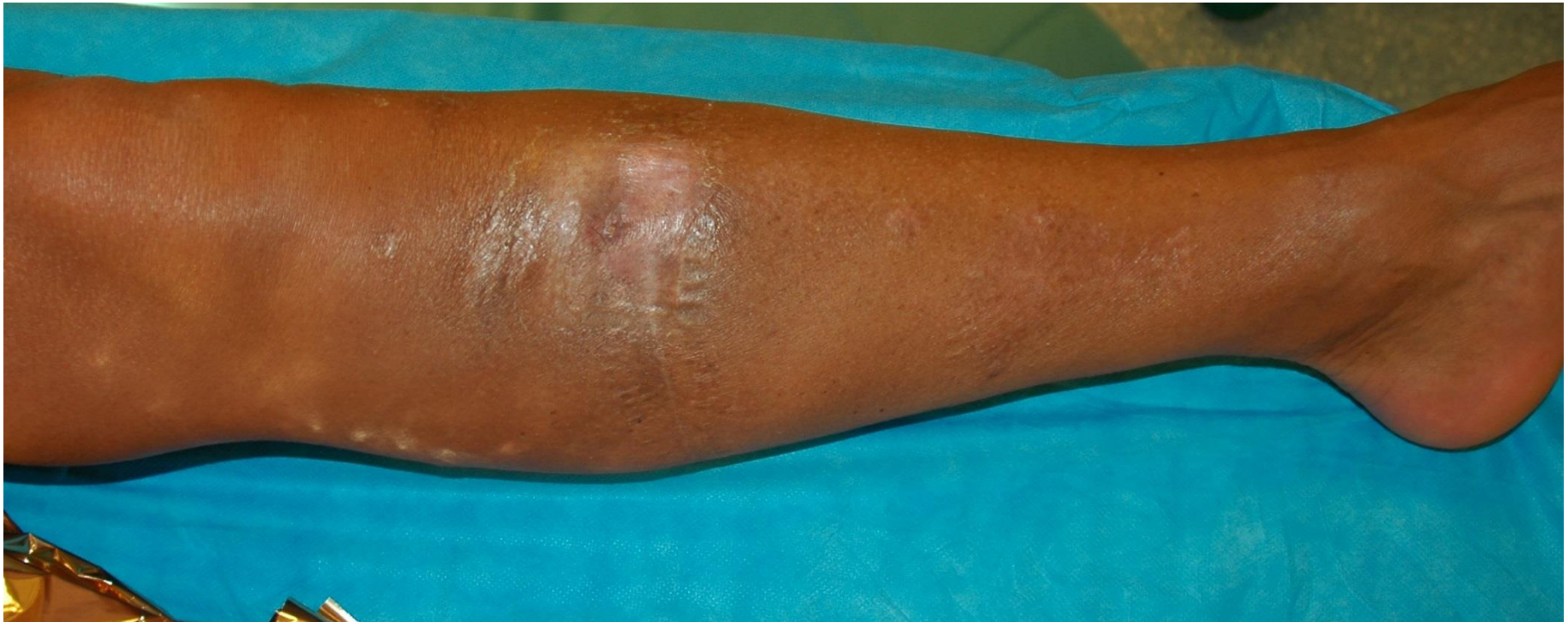3 years clinical result

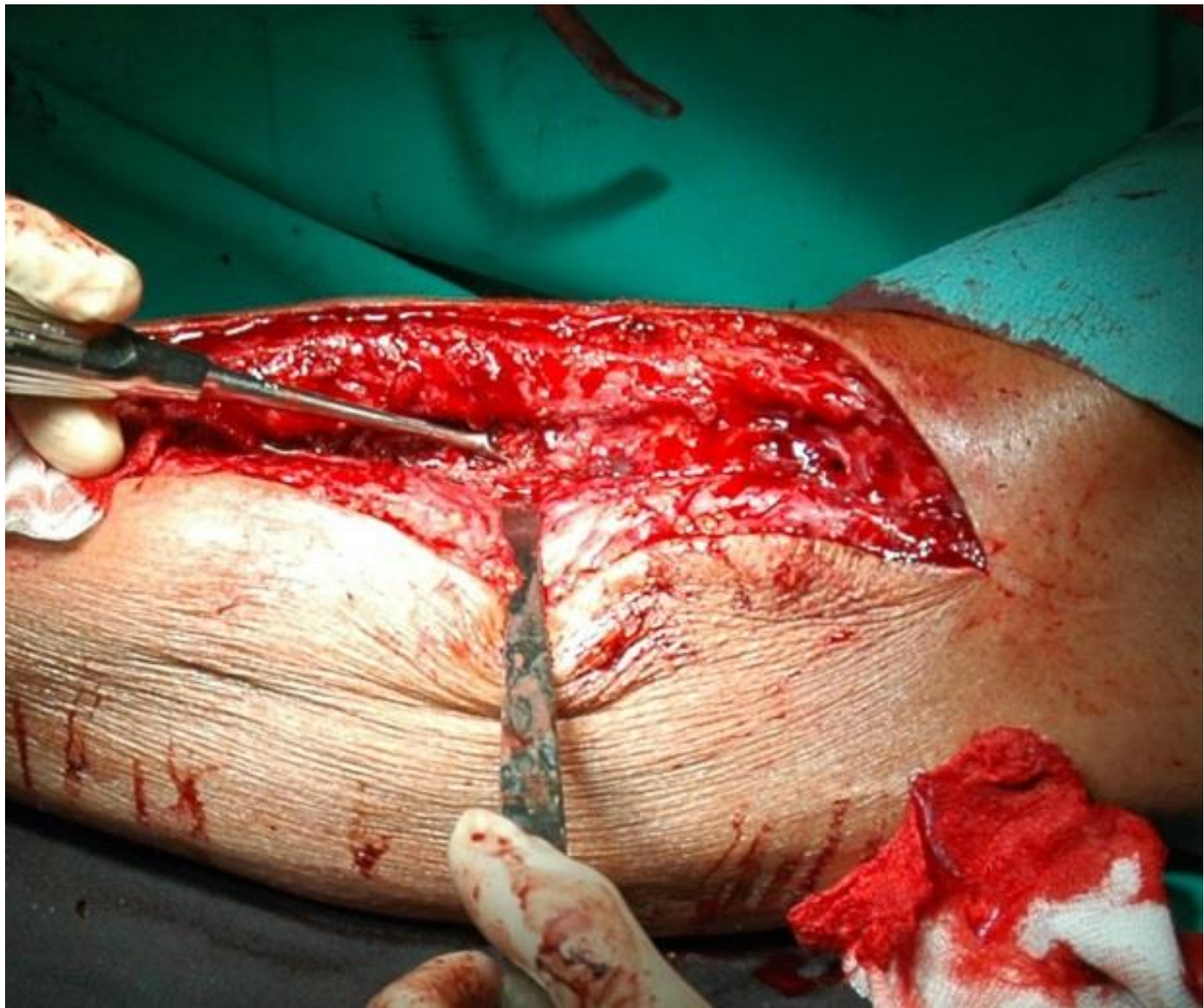


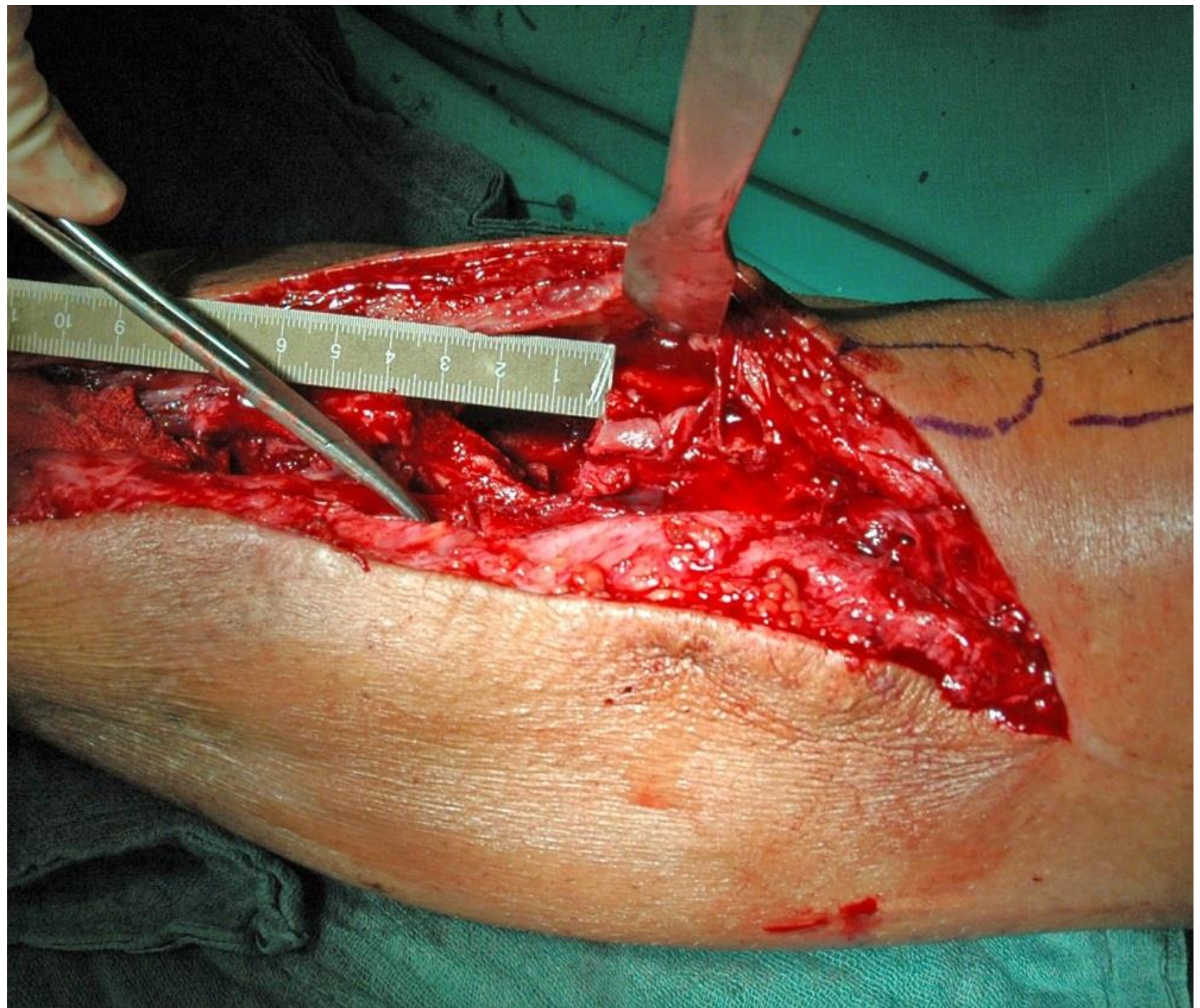
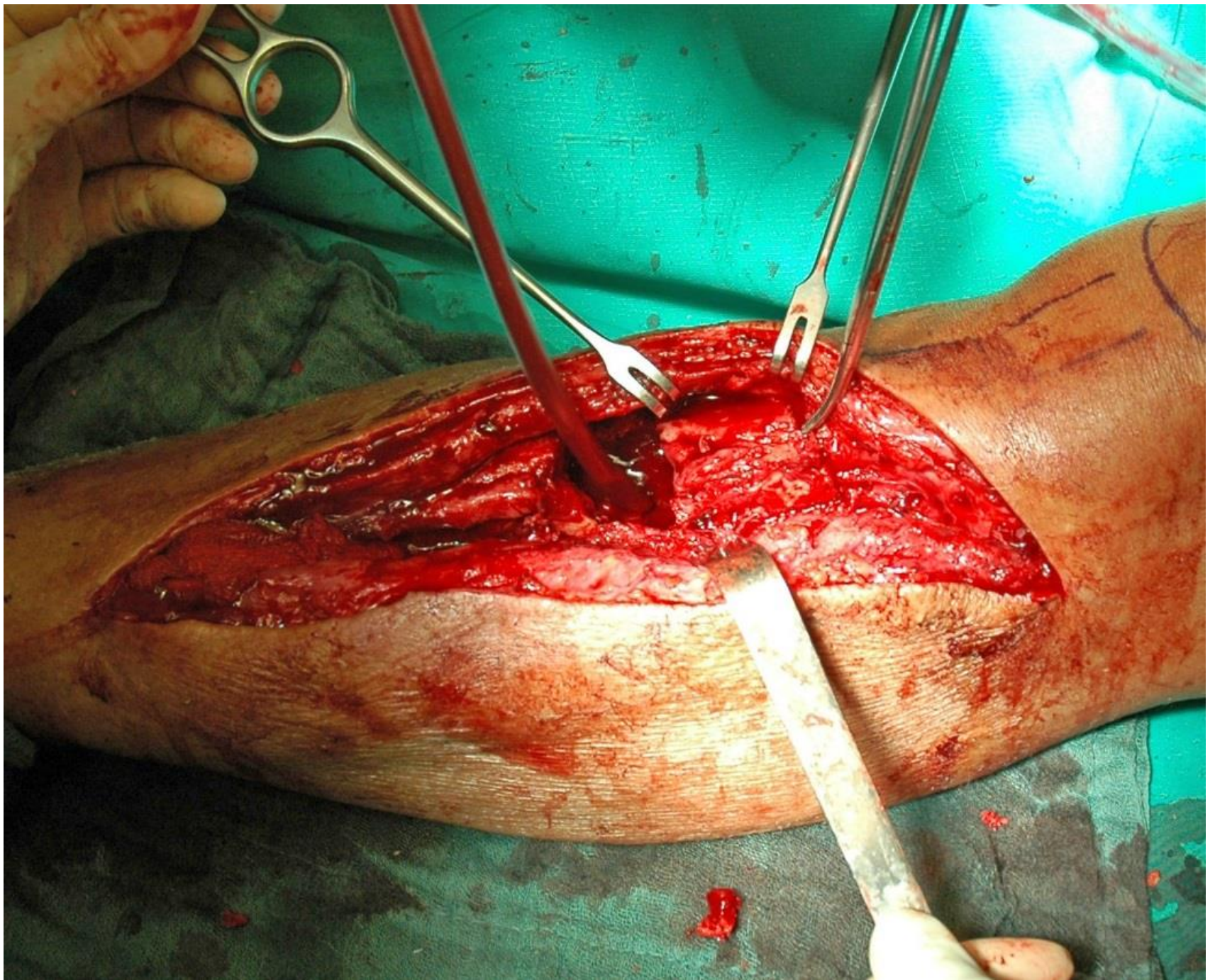M, 43 anni.

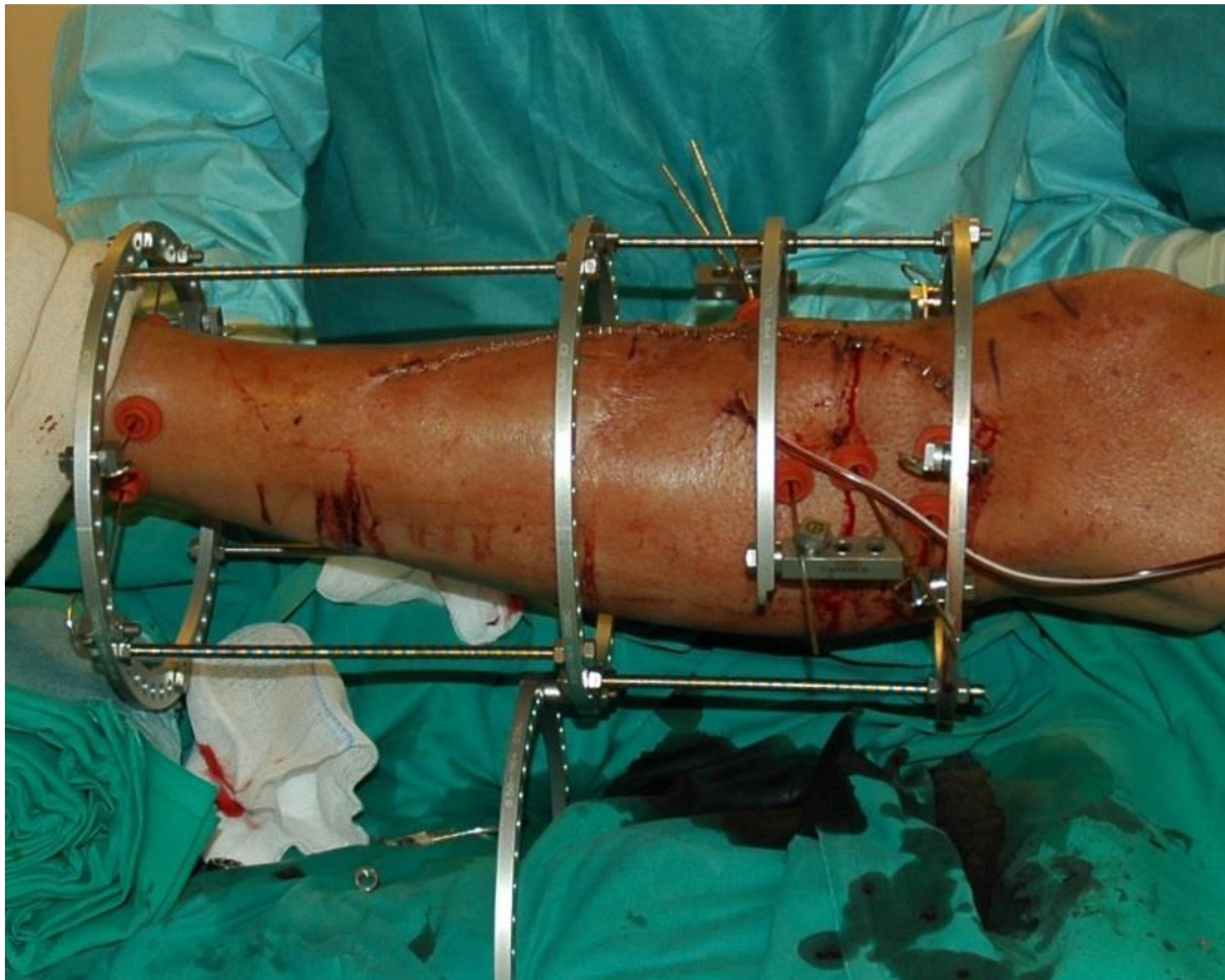fistola dopo rimozione mds in esiti post-traumatici

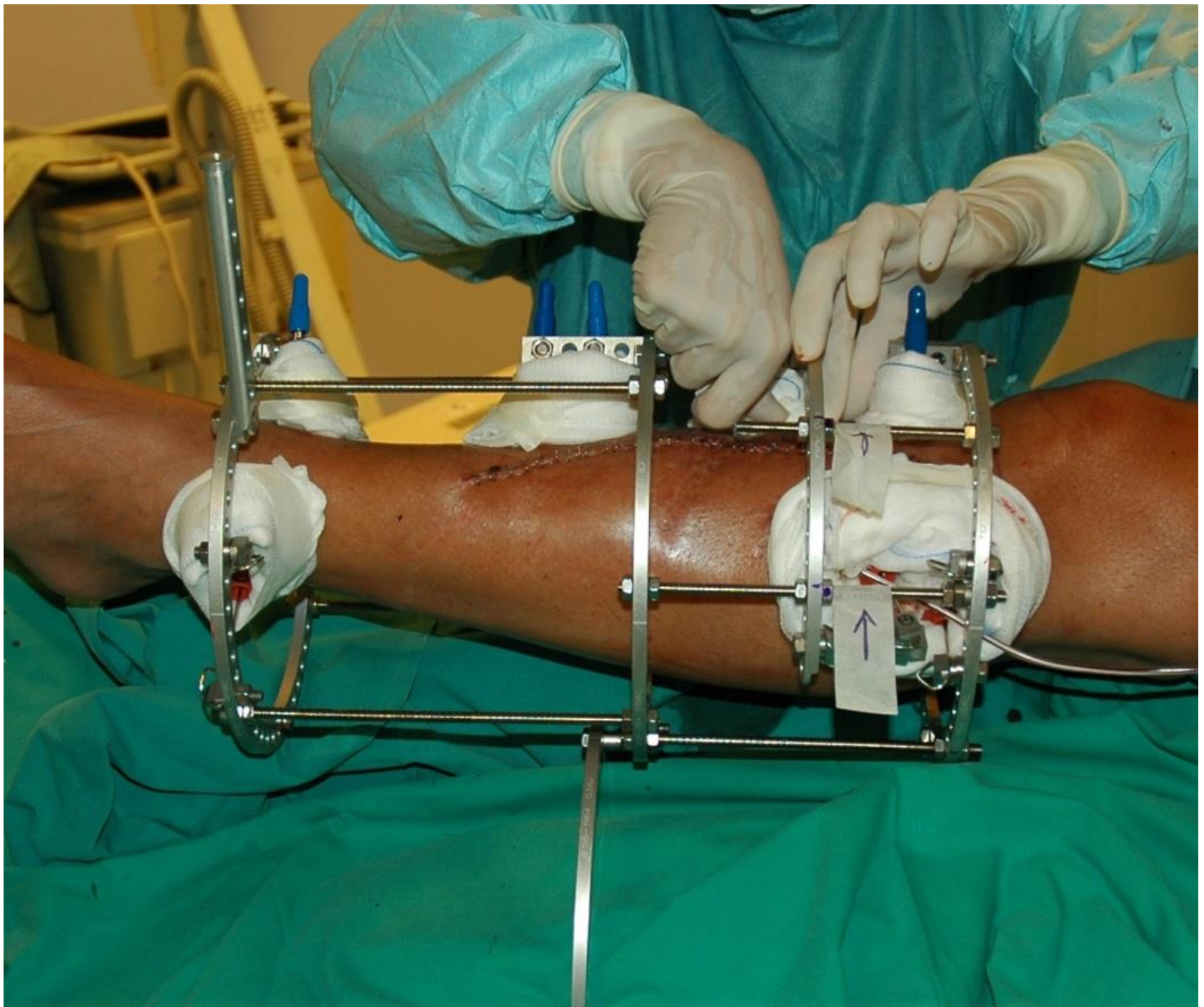

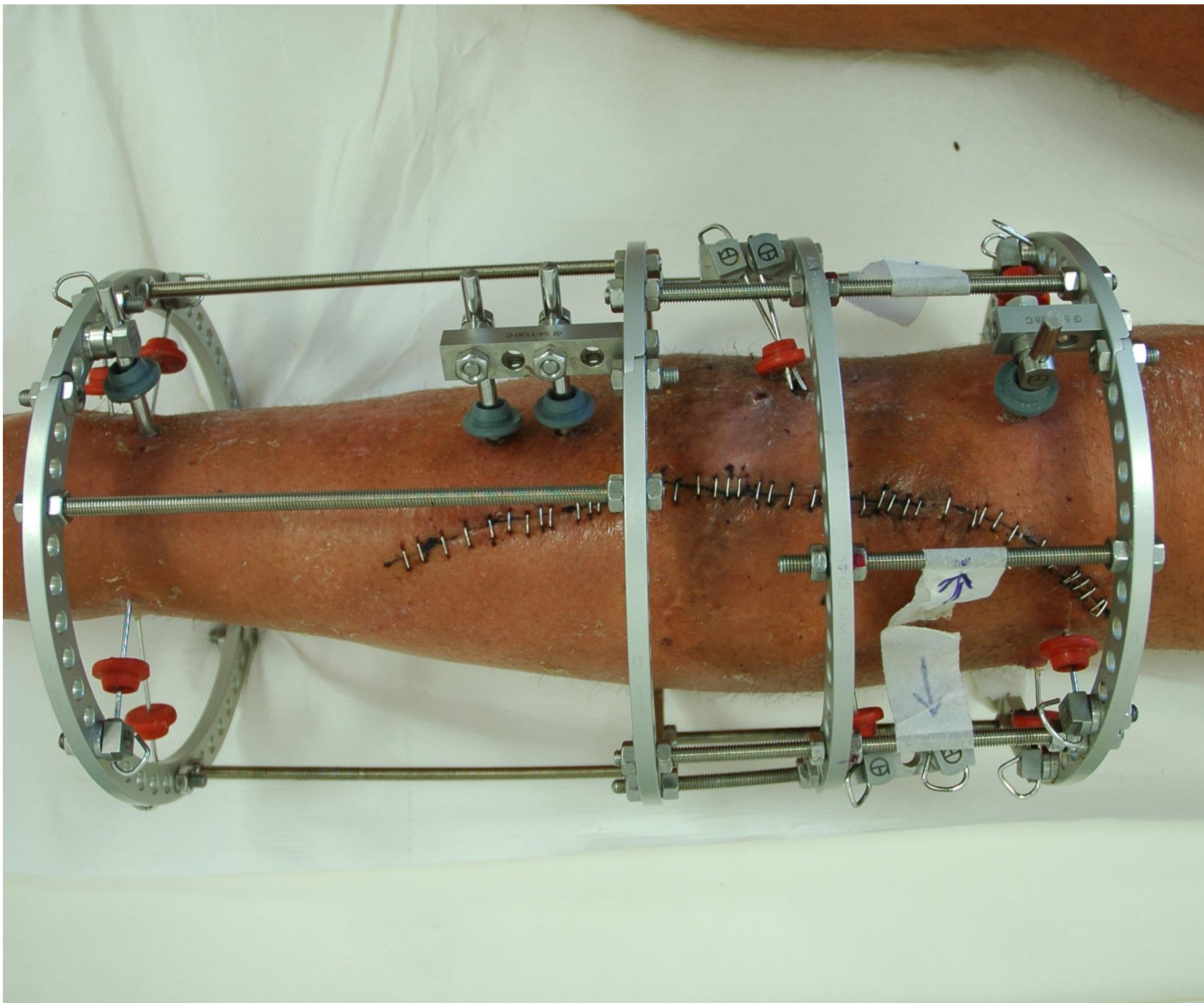





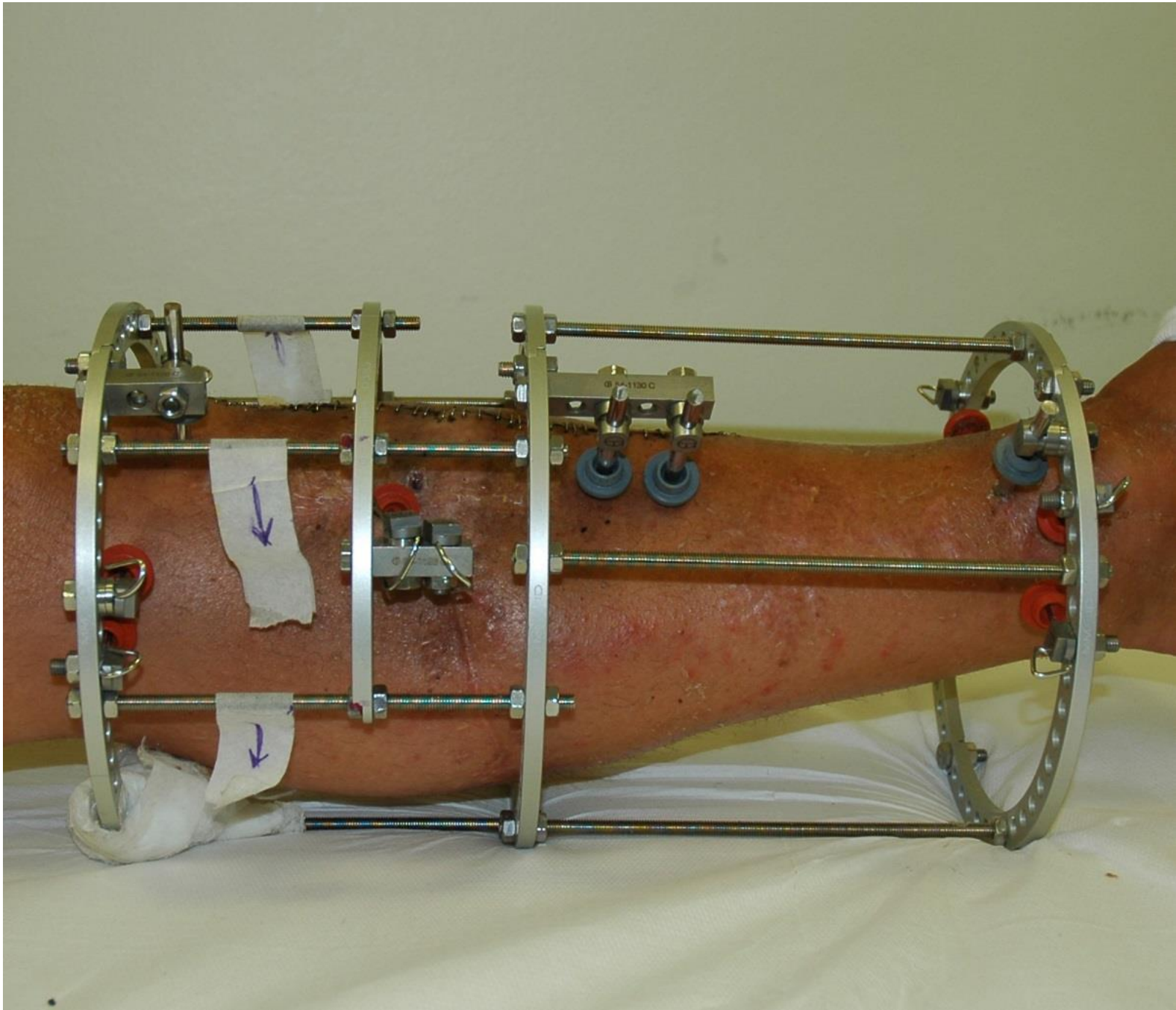










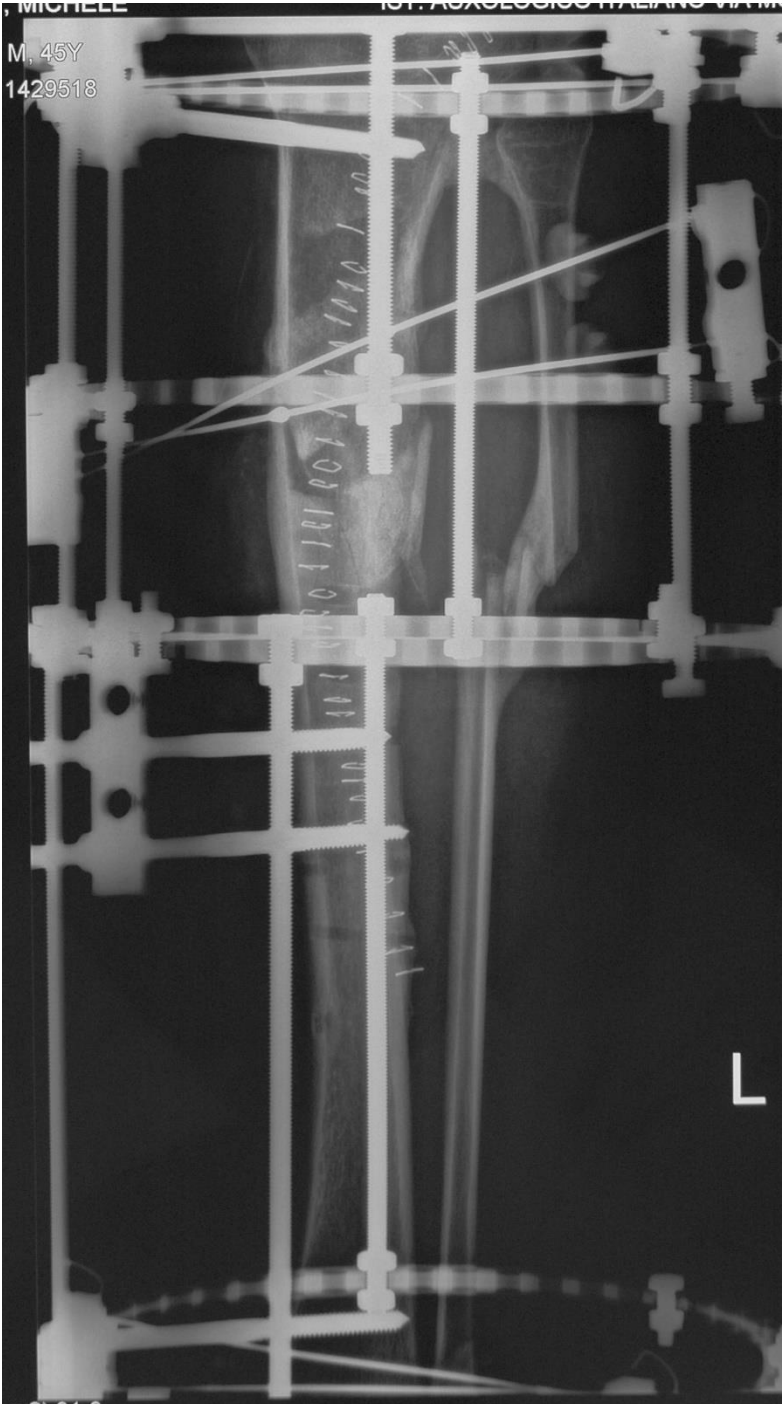




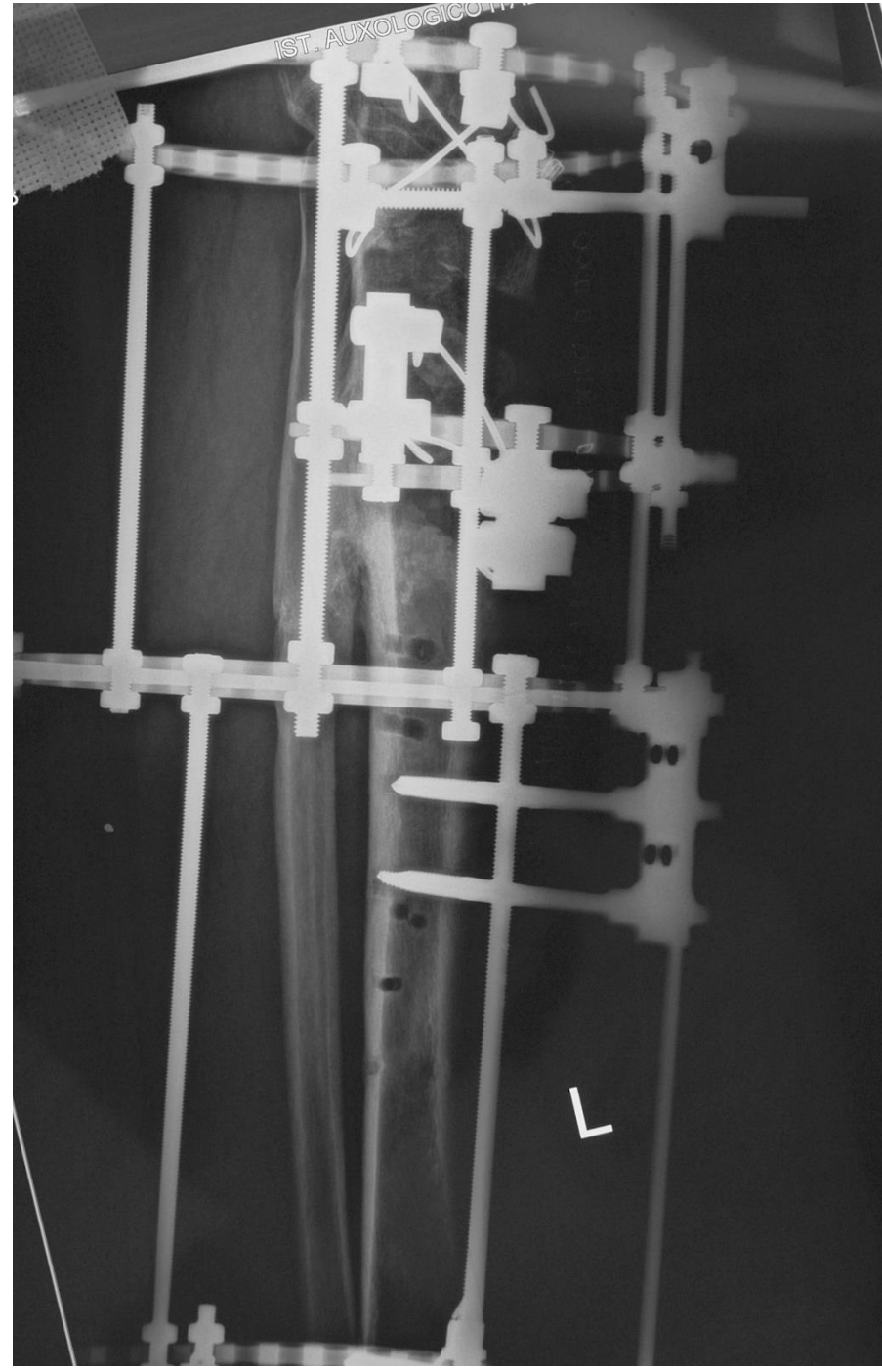
MICHELLE

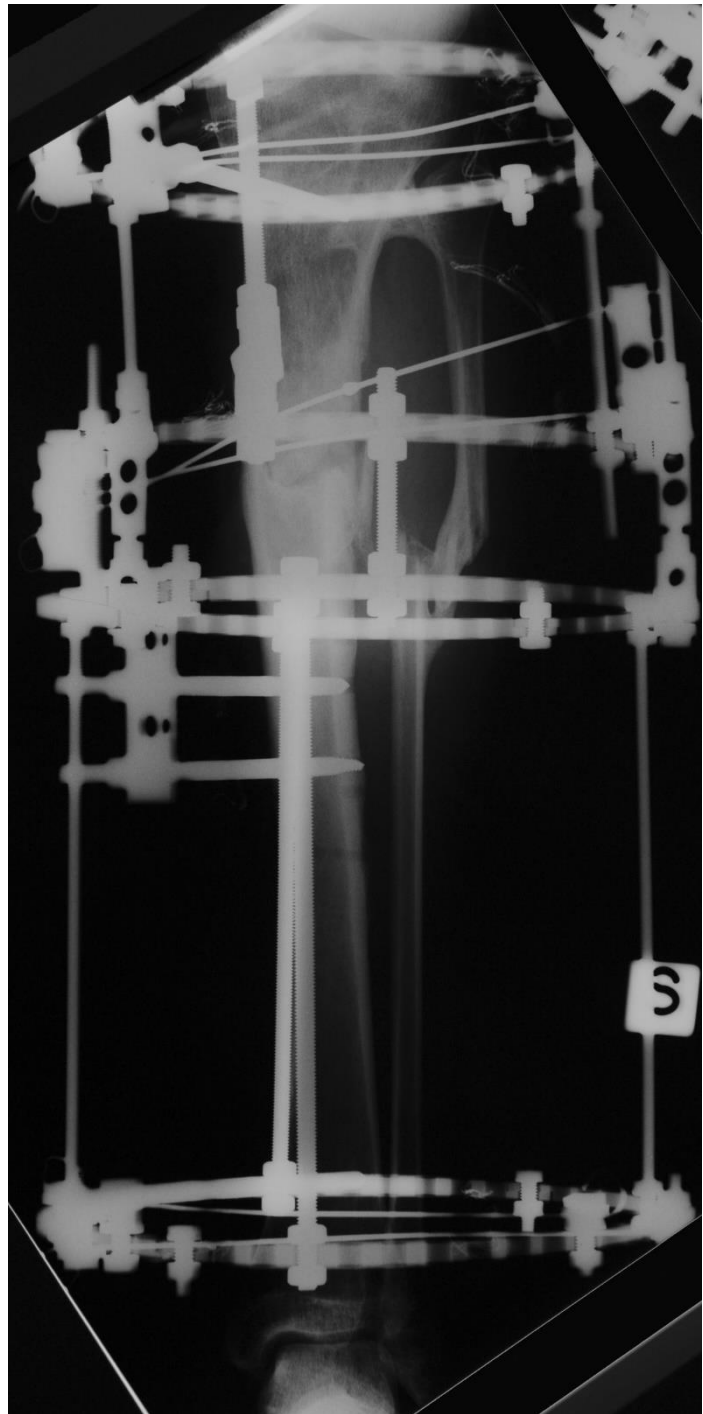
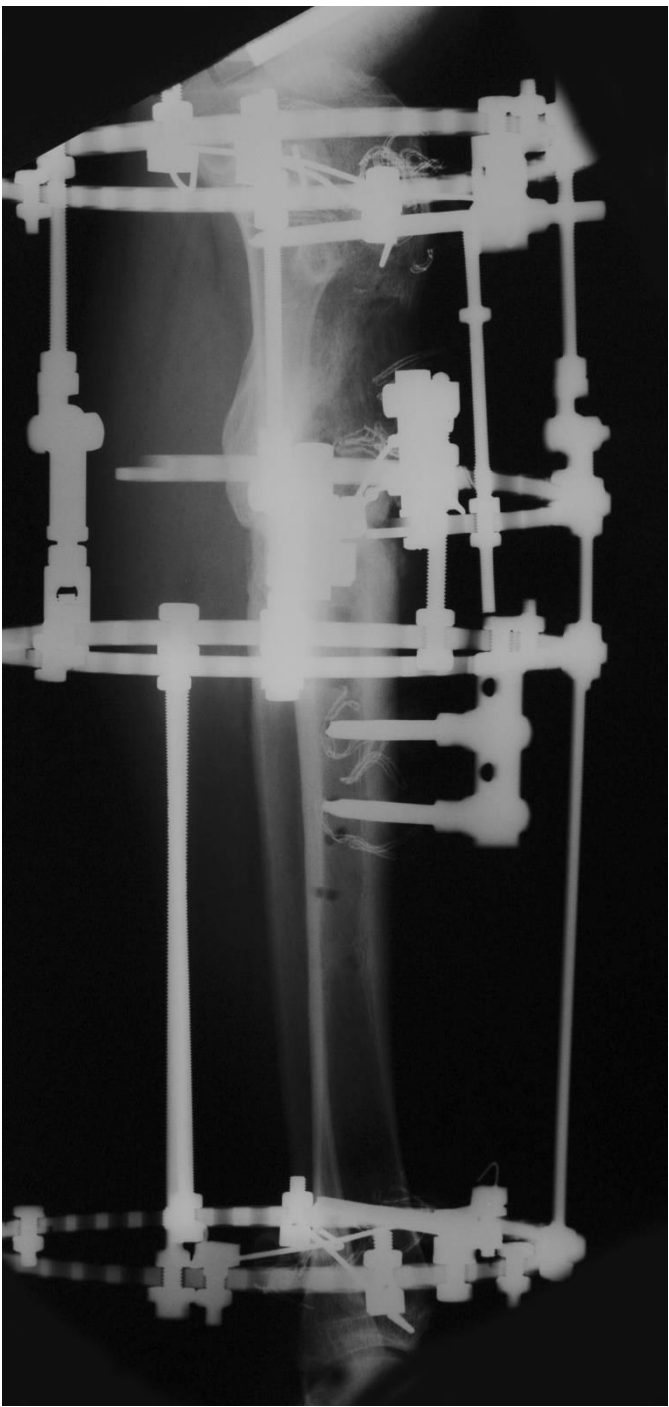
IST. AUCOLOGICO

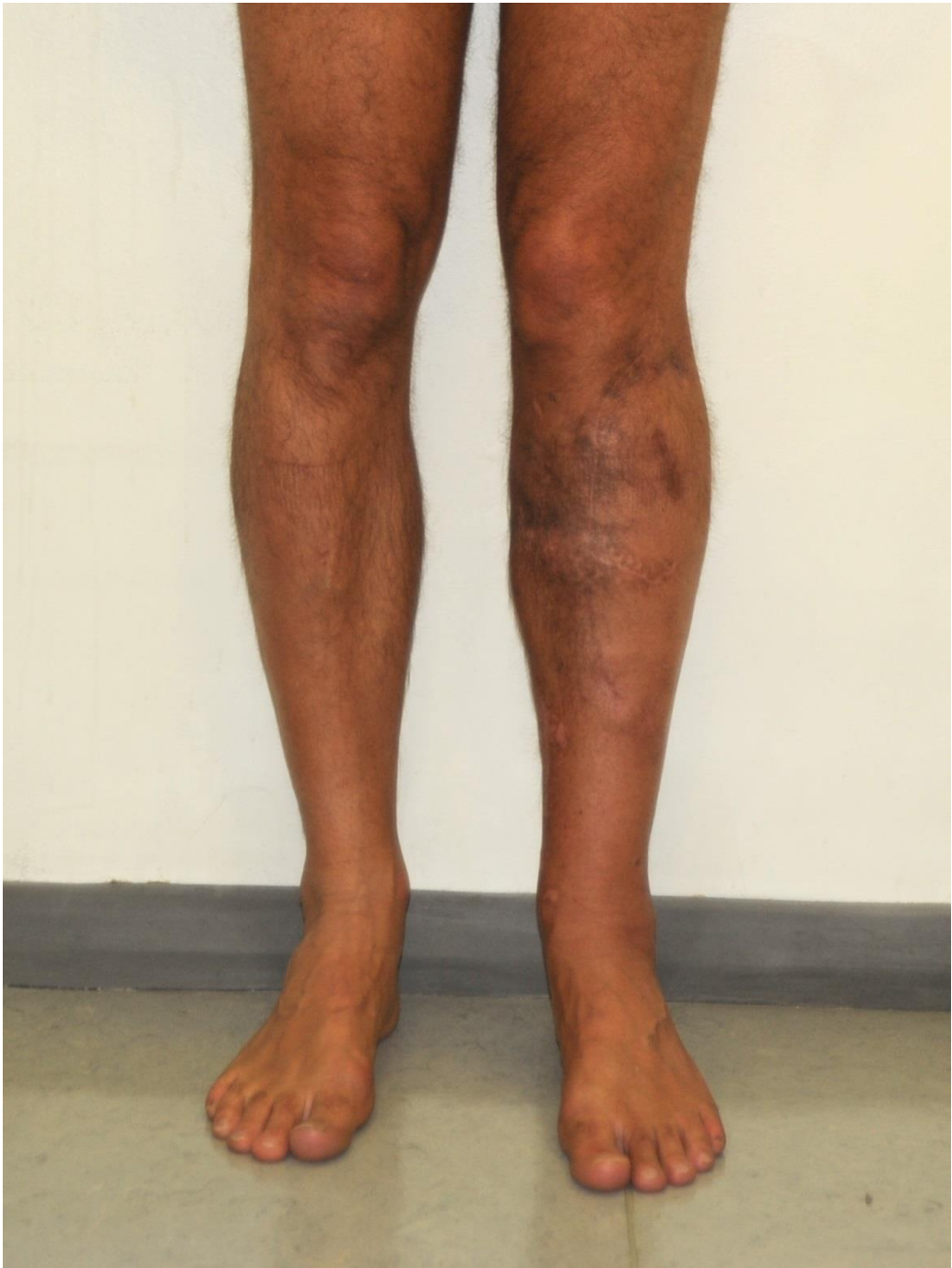M, 45Y
1429518

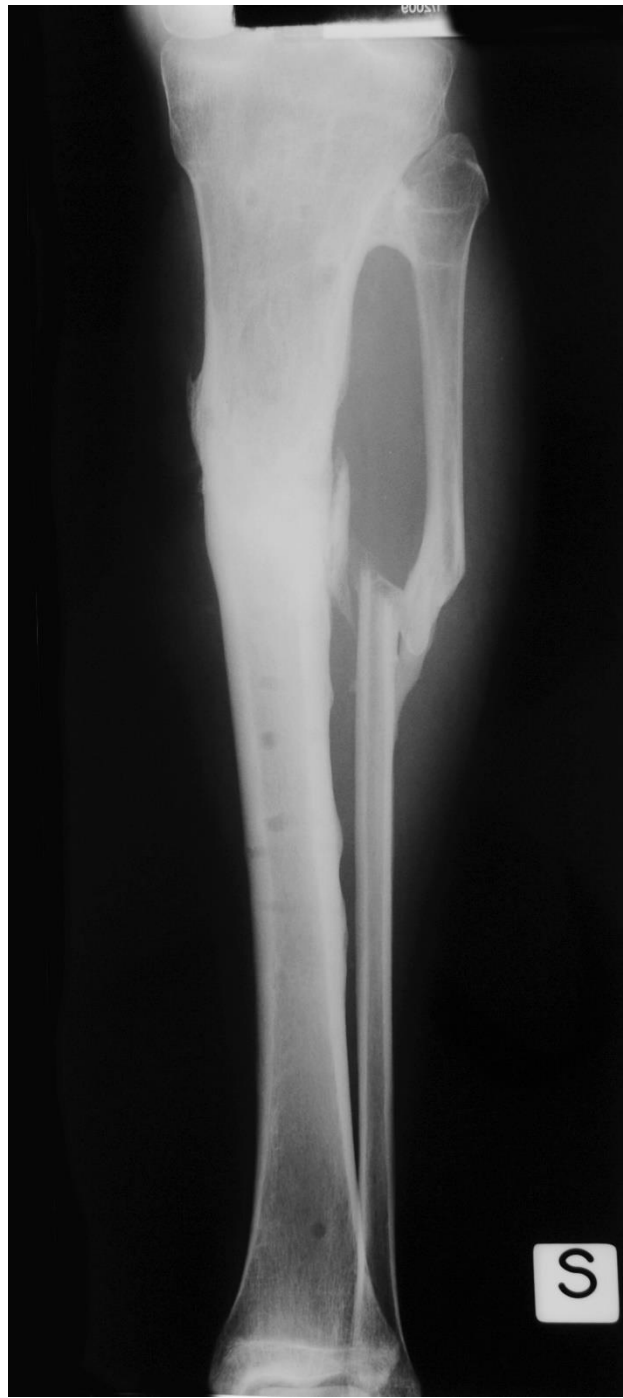
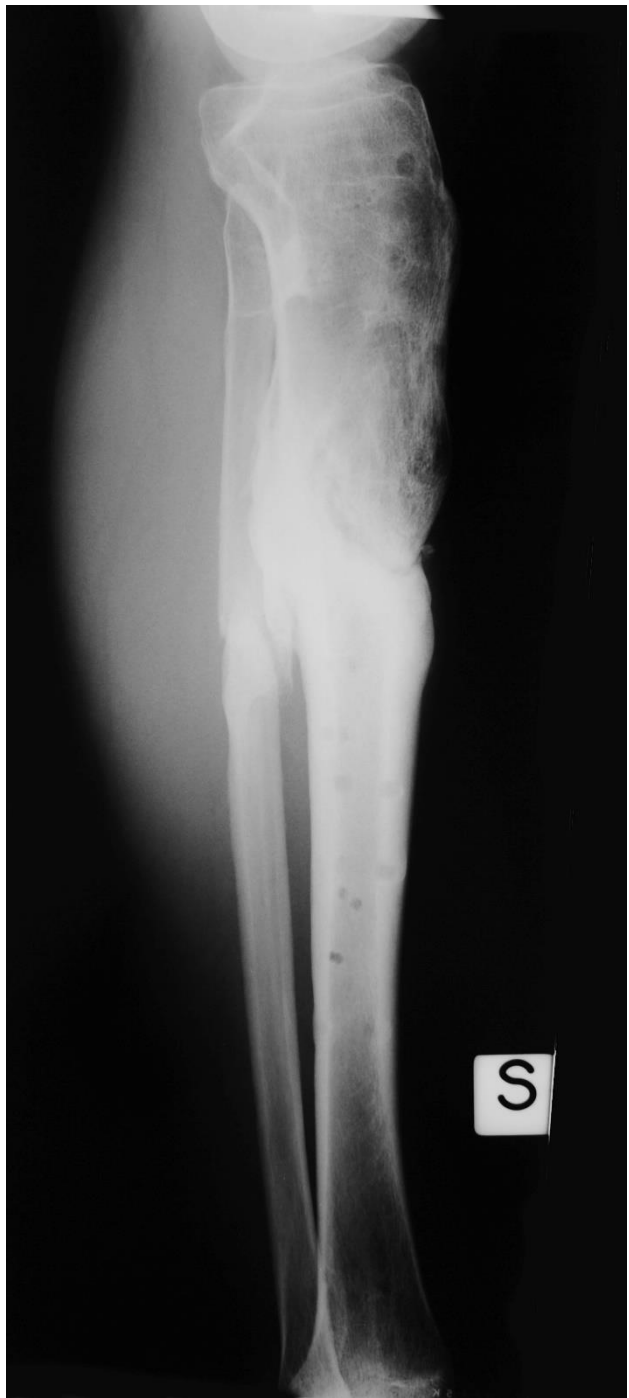
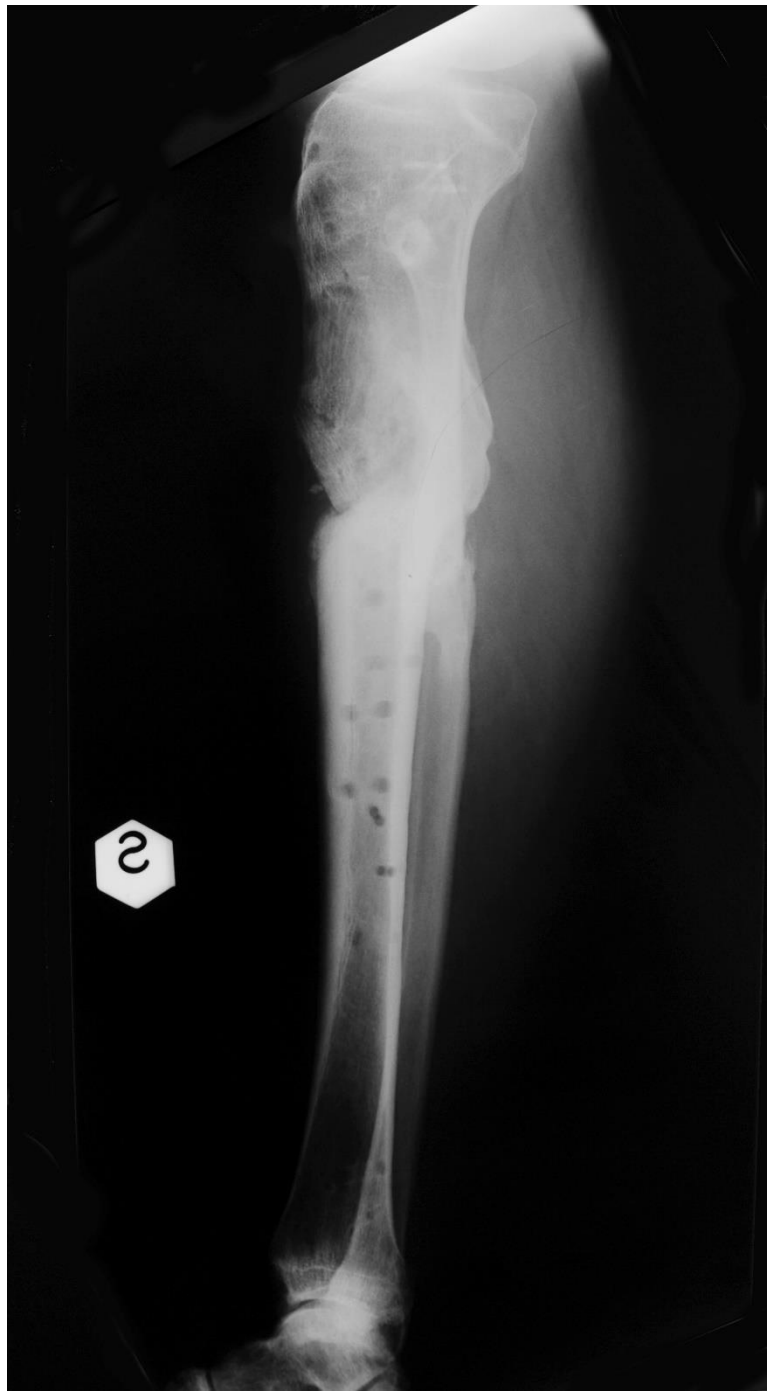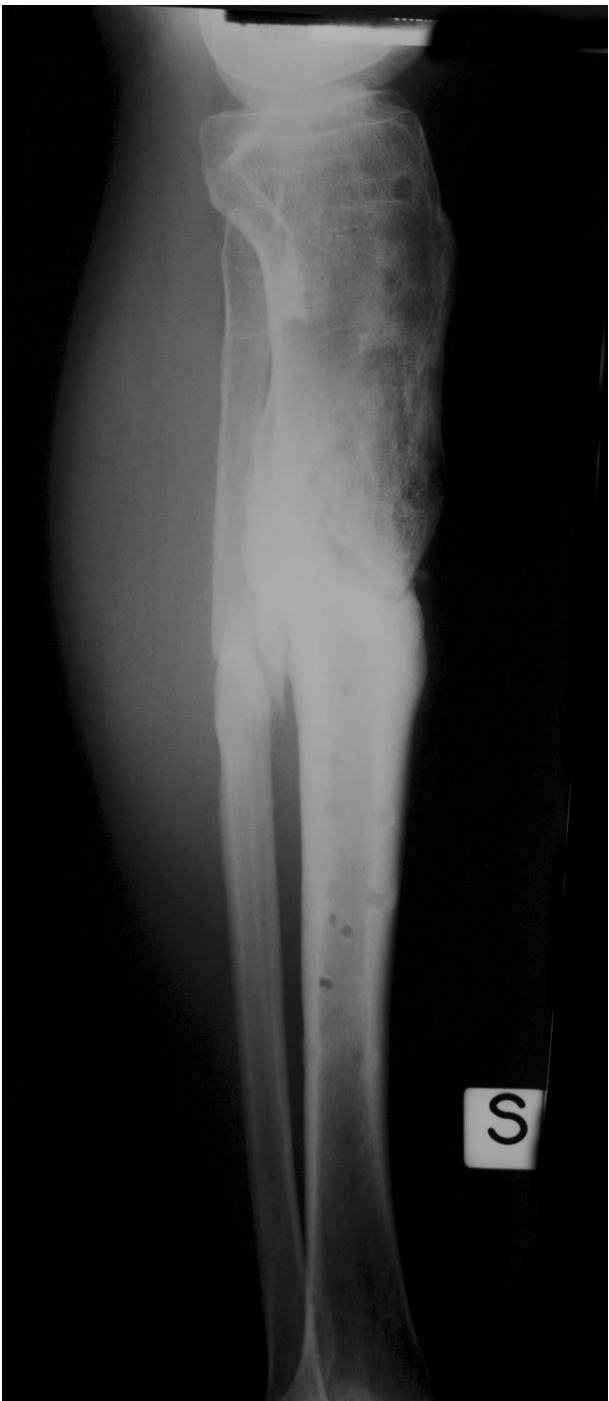IST. AUCOLOGICO

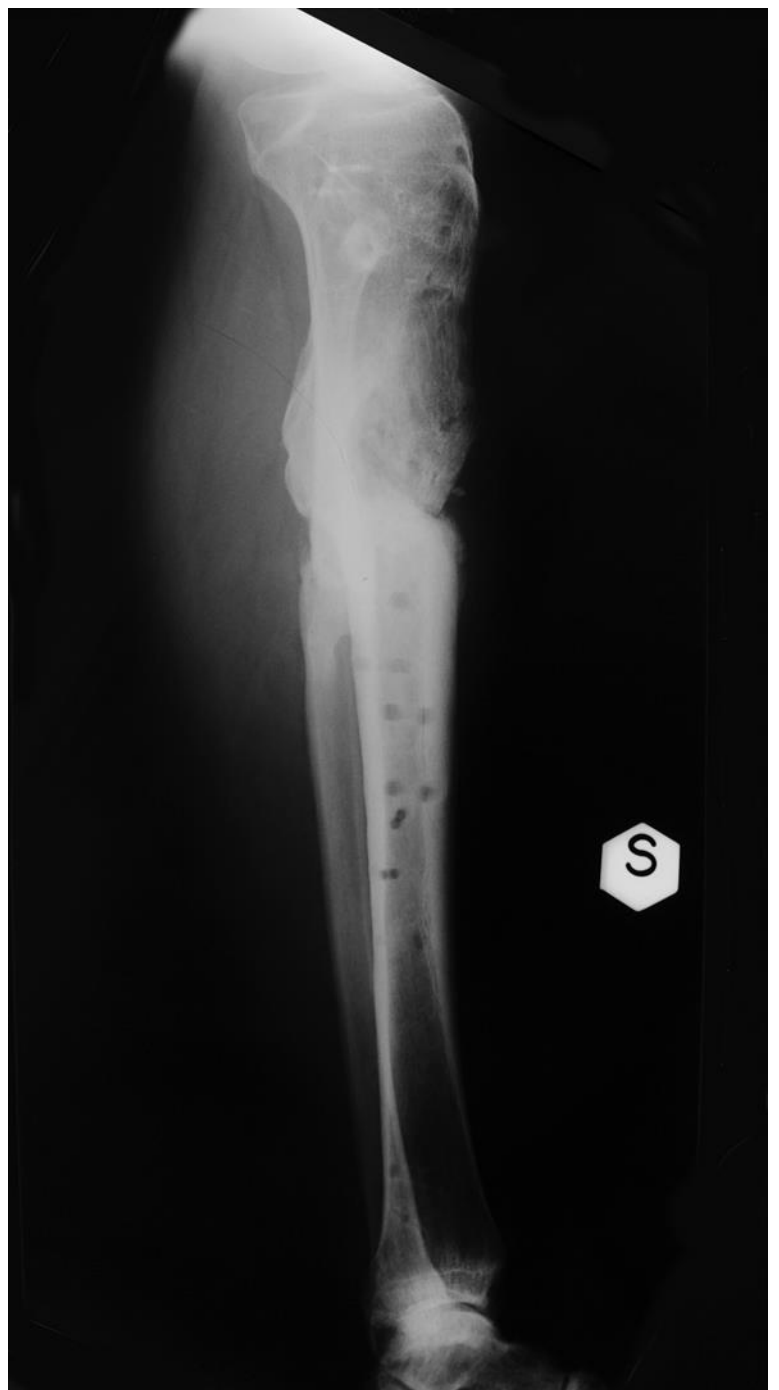
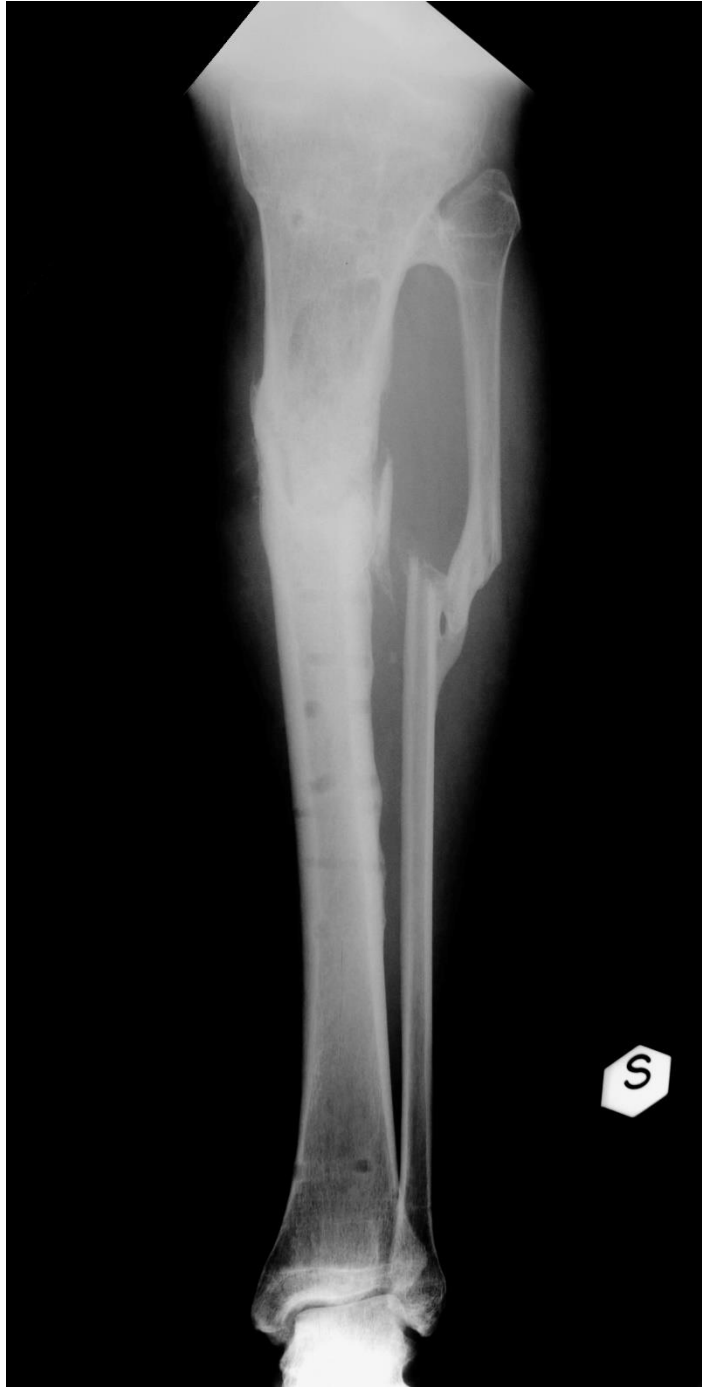


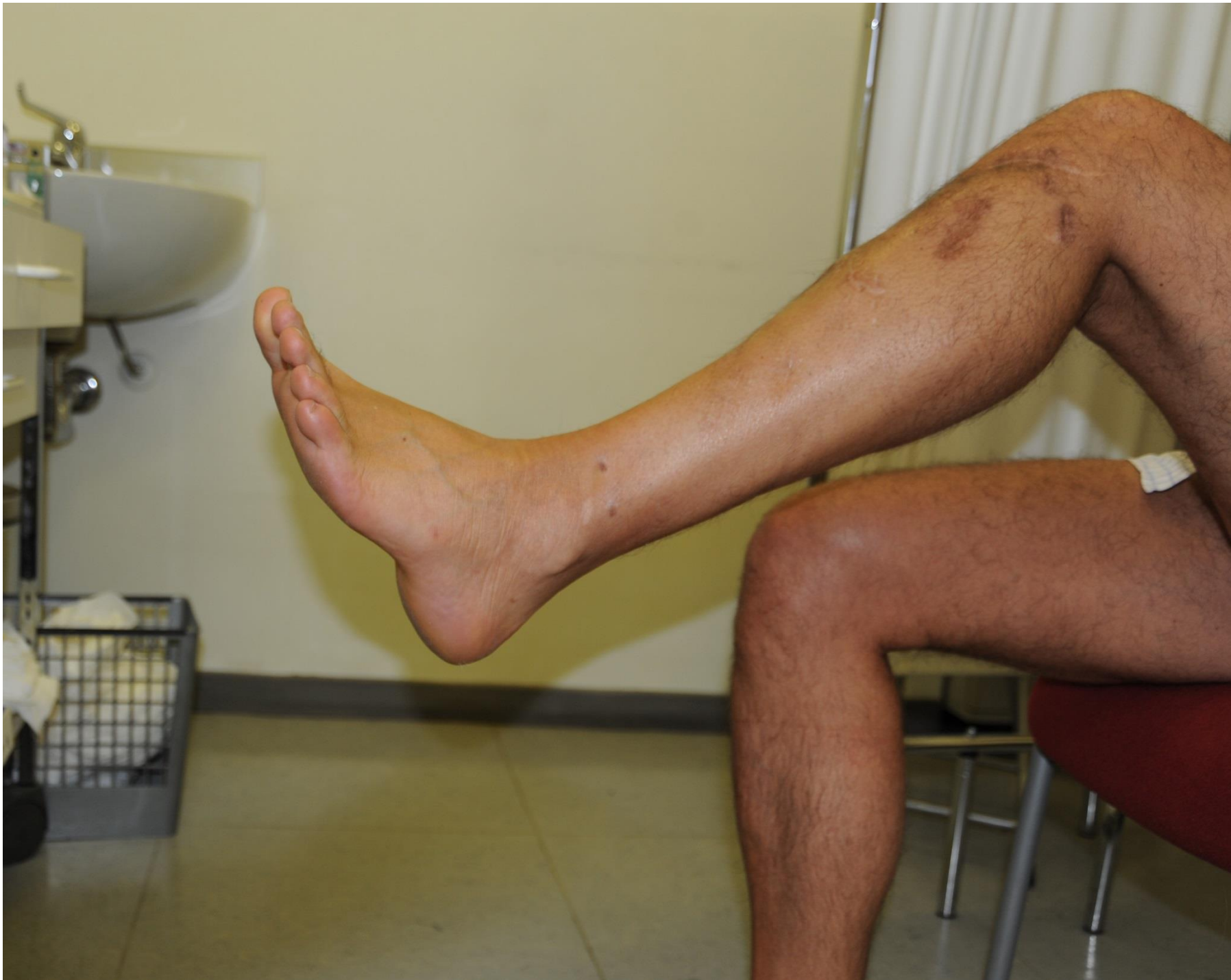


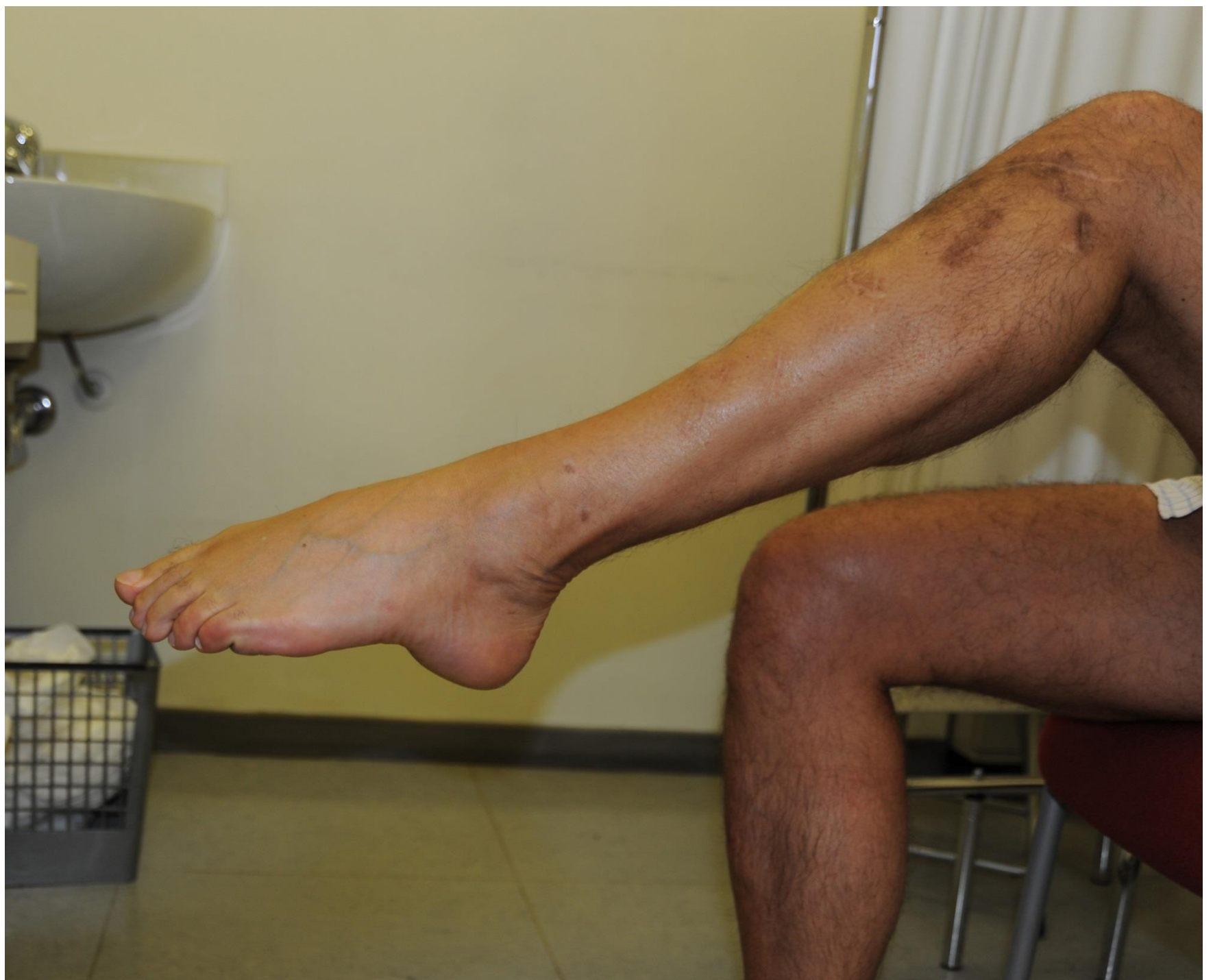








PAZIENTE MASCHIO 55 ANNI.

02.11.2021 INCIDENTE STRADALE PEDONE INVESTITO DA MOTO CON FRATTURA TIBIA SINISTRA CON SOFFERENZA DEI TESSUTI MOLLI, FLITTENE.

SINTESI INTERNA CON UNA PLACCA PER IL PIATTO TIBIALE E UNA PLACCA PER LA DIAFISI

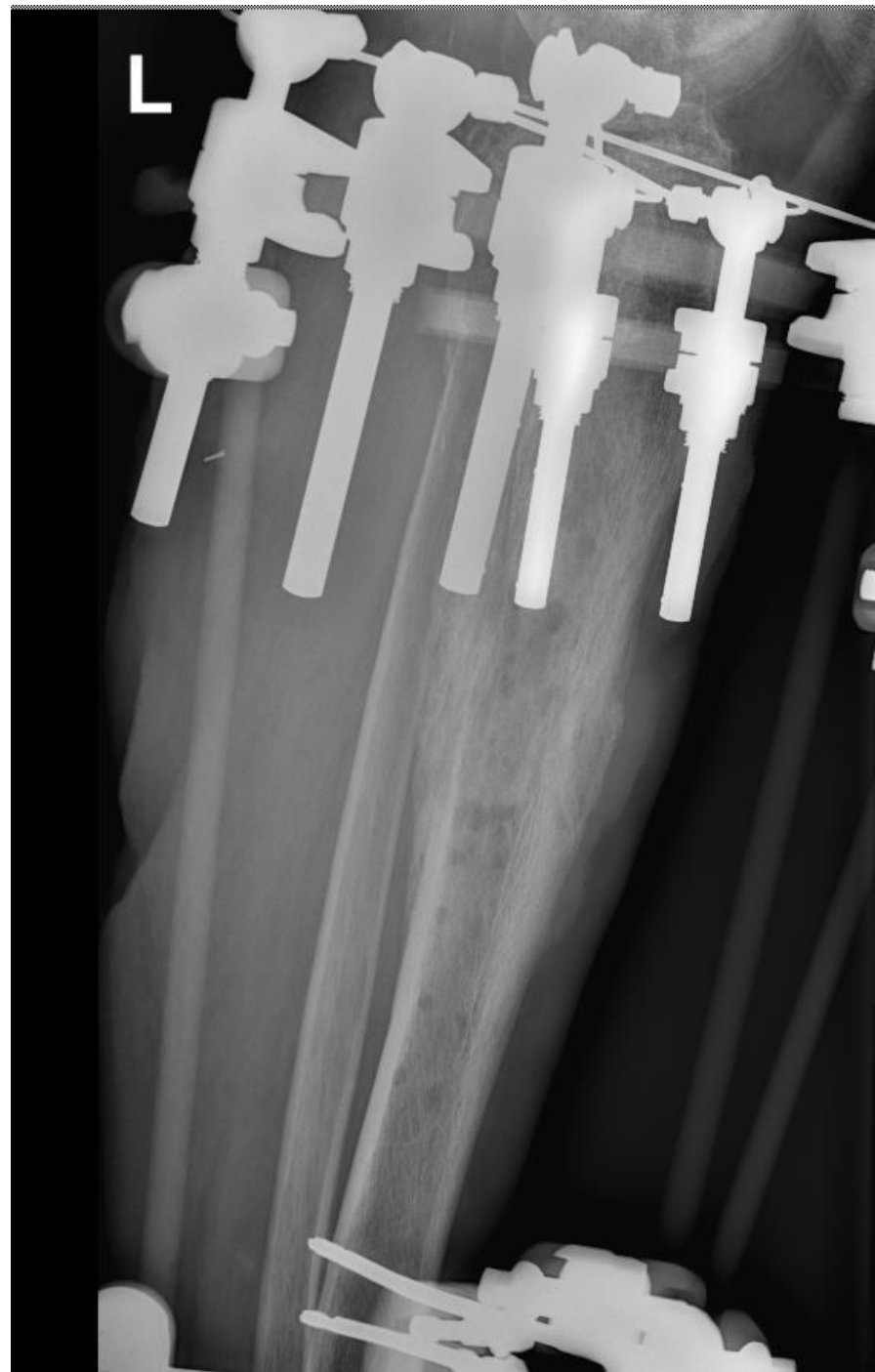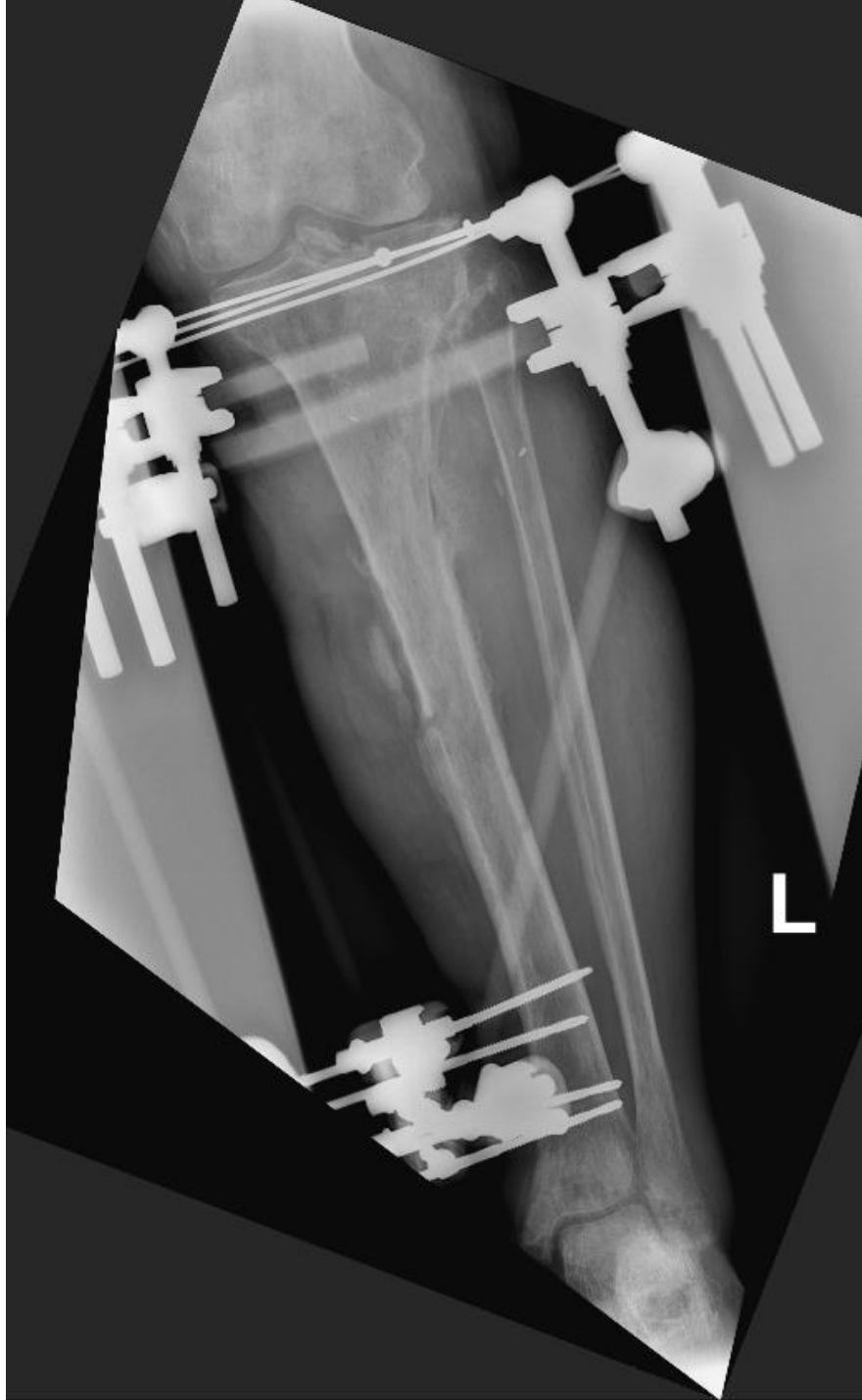
POI INFEZIONE, DEISCENZA DELLA FERITA, ESPOSIZIONE MEZZI DI SINTESI,

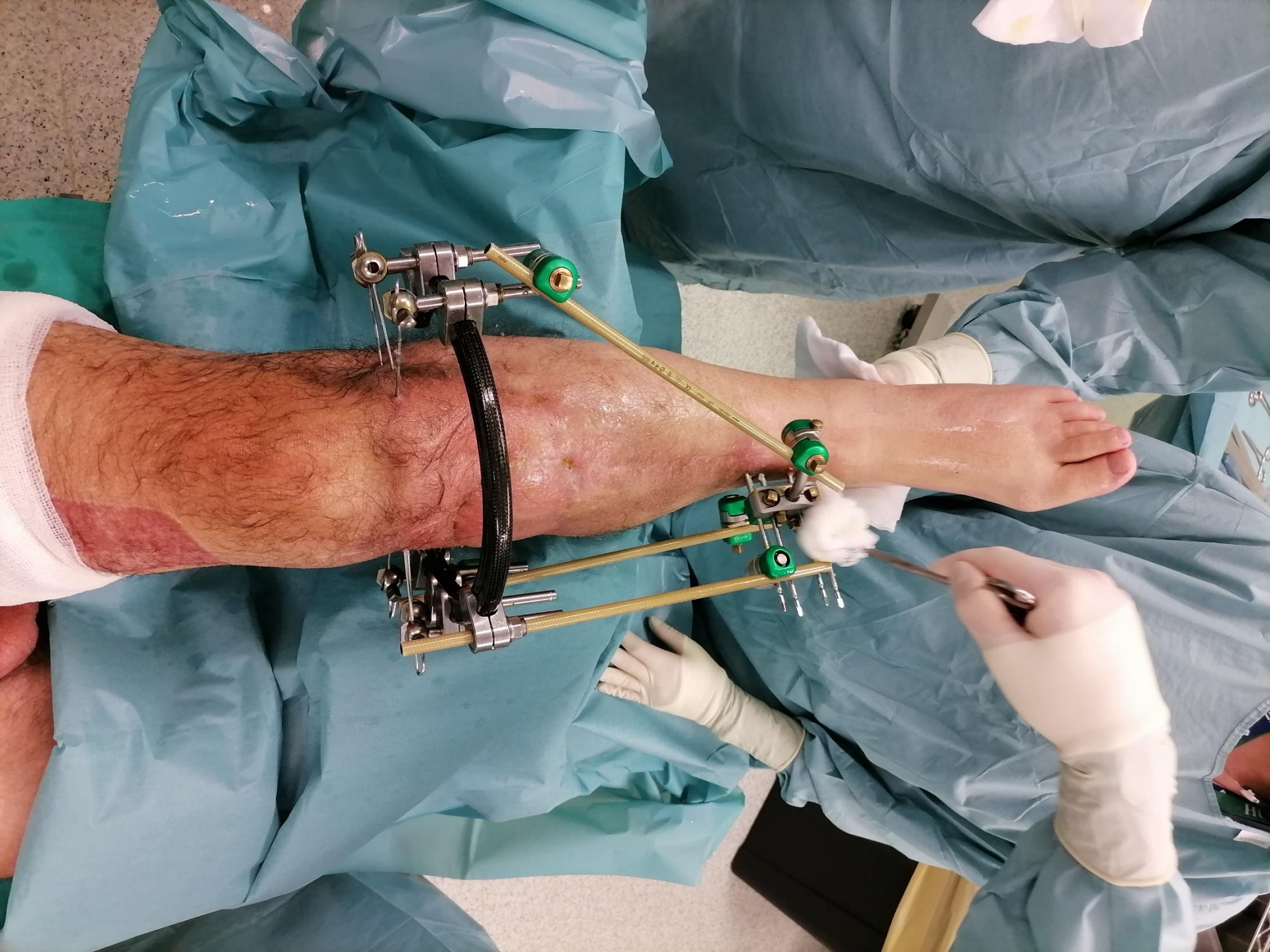
SINTESI CON FISSATORE IBRIDO

OSSO NECROTICO.

LEMBO DI COPERTURA

FISTOLA SECERNENTE PUS





11.05.2022

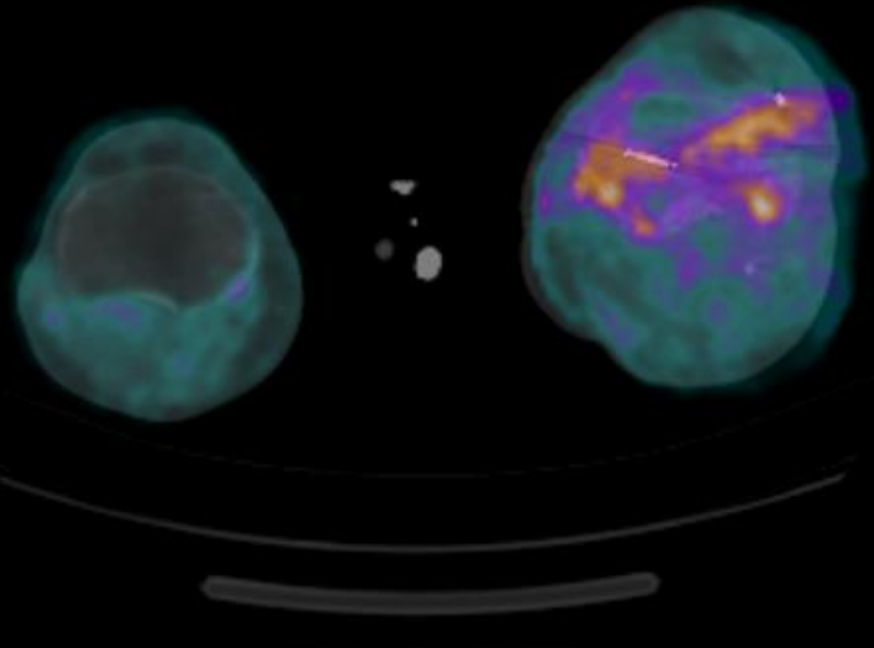

Ex: 00% 11.01.21 00% 11.01.21 11.05.22

Control: 11.05.22

Se: 12 / 3
S: 631.3

M 54 739635
DoB: Aug 28 1967
Ex: May 11 2022

DFDV 70.0 cm



50 % PET

2.80

1250/94

Reformat Volume 2/Volume 1

Ex: 50% 4791 / 50% 4791

S 880

BOTTONE BRUNO

Centro Aktis

M 54 739635

DoB: Aug 28 1967

Ex: May 11 2022

Se: 12 / 3

P: 37.4

DFOV 70.0 cm

4.43

0.00

50 % PET

2.73

2.8mm / 2.80sp

01:09:35 PM

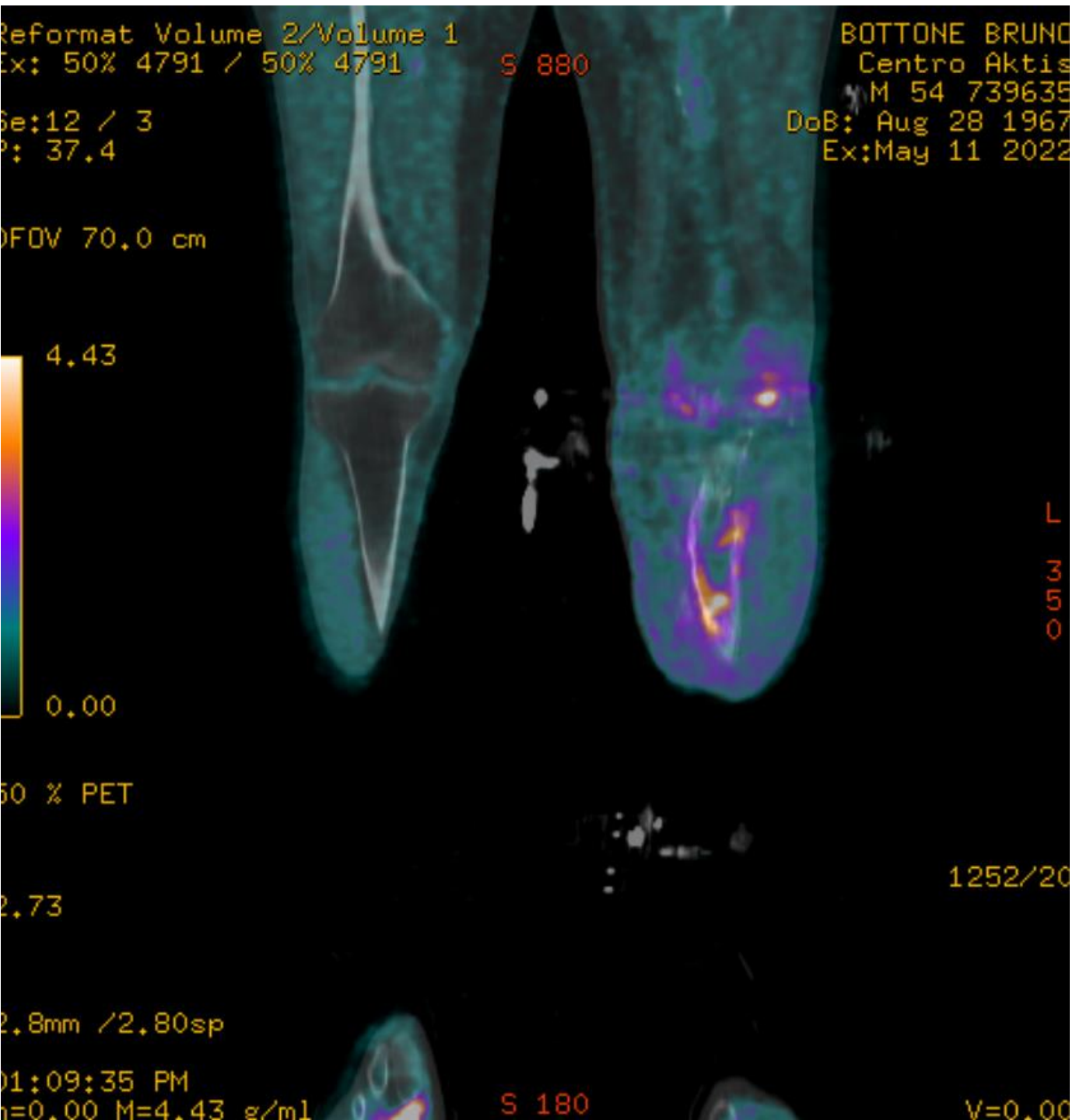
h=0.00 M=4.43 g/ml

S 180

1252/20

V=0.00

L
3
5
0




Reformat Volume 2/Volume 1
Ex: 50% 4791 / 50% 4791

S 880

BOTTONE BRUNO
Centro Aktis
M 54 739635
DoB: Aug 28 1967
Ex: May 11 2022

Se: 12 / 3
L: 106.3

DFOV 70.0 cm



50 % PET

2.73

2.8mm / 2.80sp

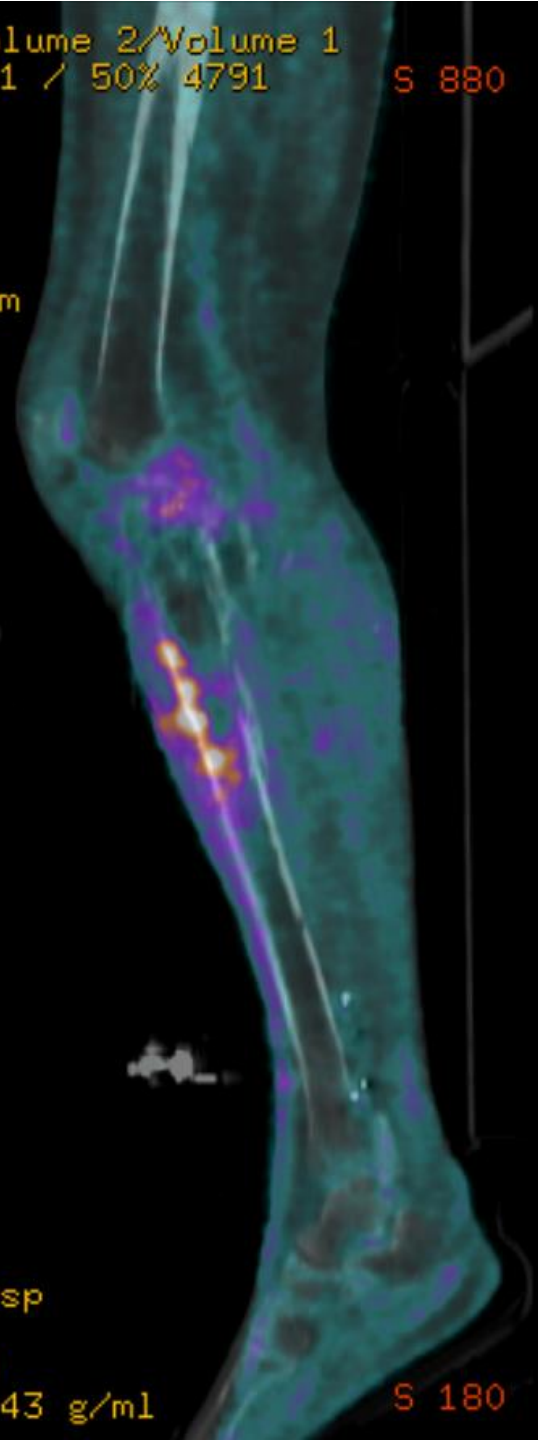
01:09:35 PM
m=0.00 M=4.43 g/ml

S 180

P
4
9
7

1253/16

V=0.00




Reformat Volume 2/Volume 1
Ex: 50% 4791 / 50% 4791

S 880

BOTTONE BRUNO
Centro Aktis
M 54 739635
DoB: Aug 28 1967
Ex: May 11 2022

Se: 12 / 3
L: 114.3

DFOV 70.0 cm



50 % PET

2.73

2.8mm /2.80sp

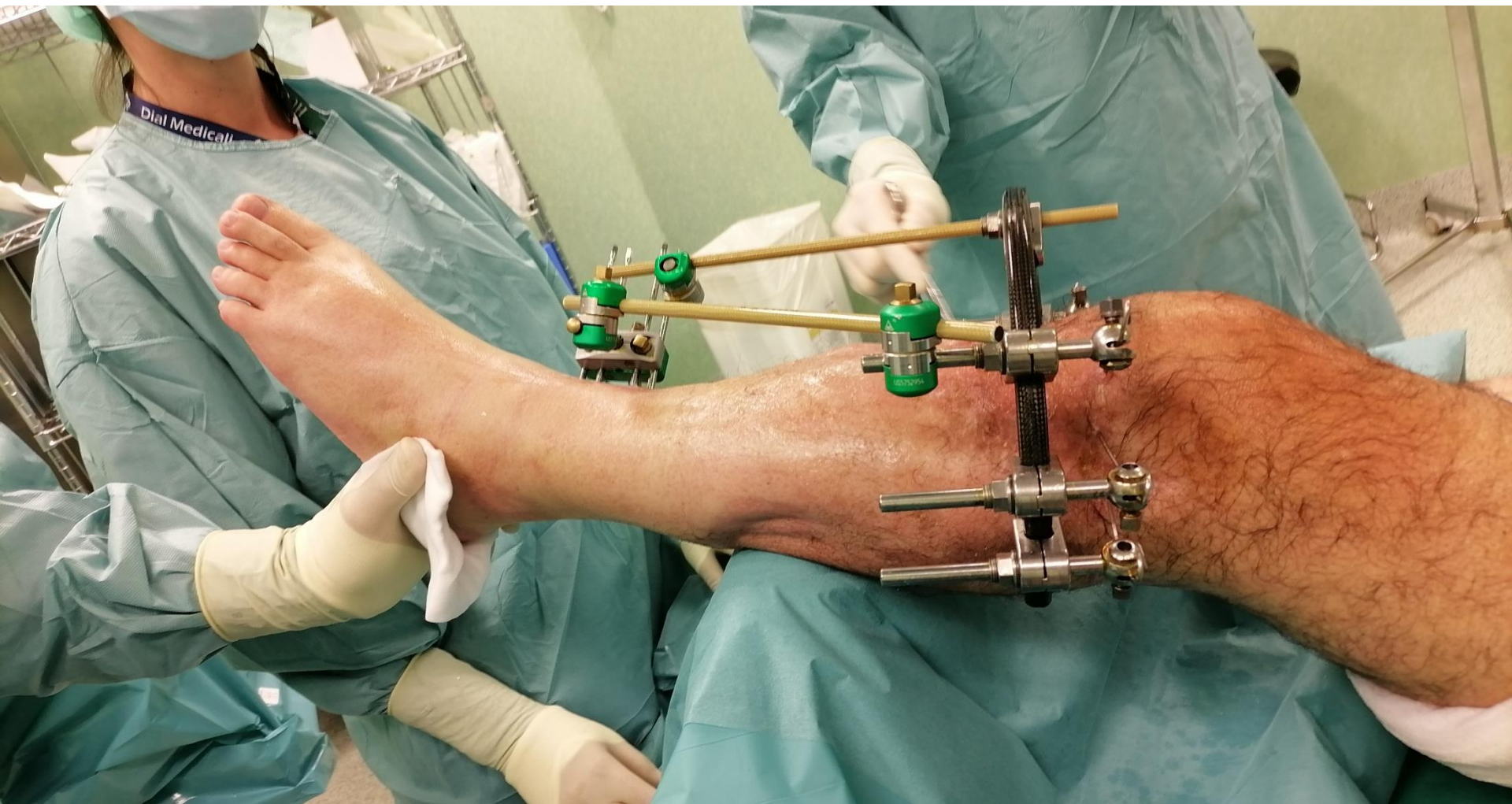01:09:35 PM
m=0.00 M=4.43 g/ml

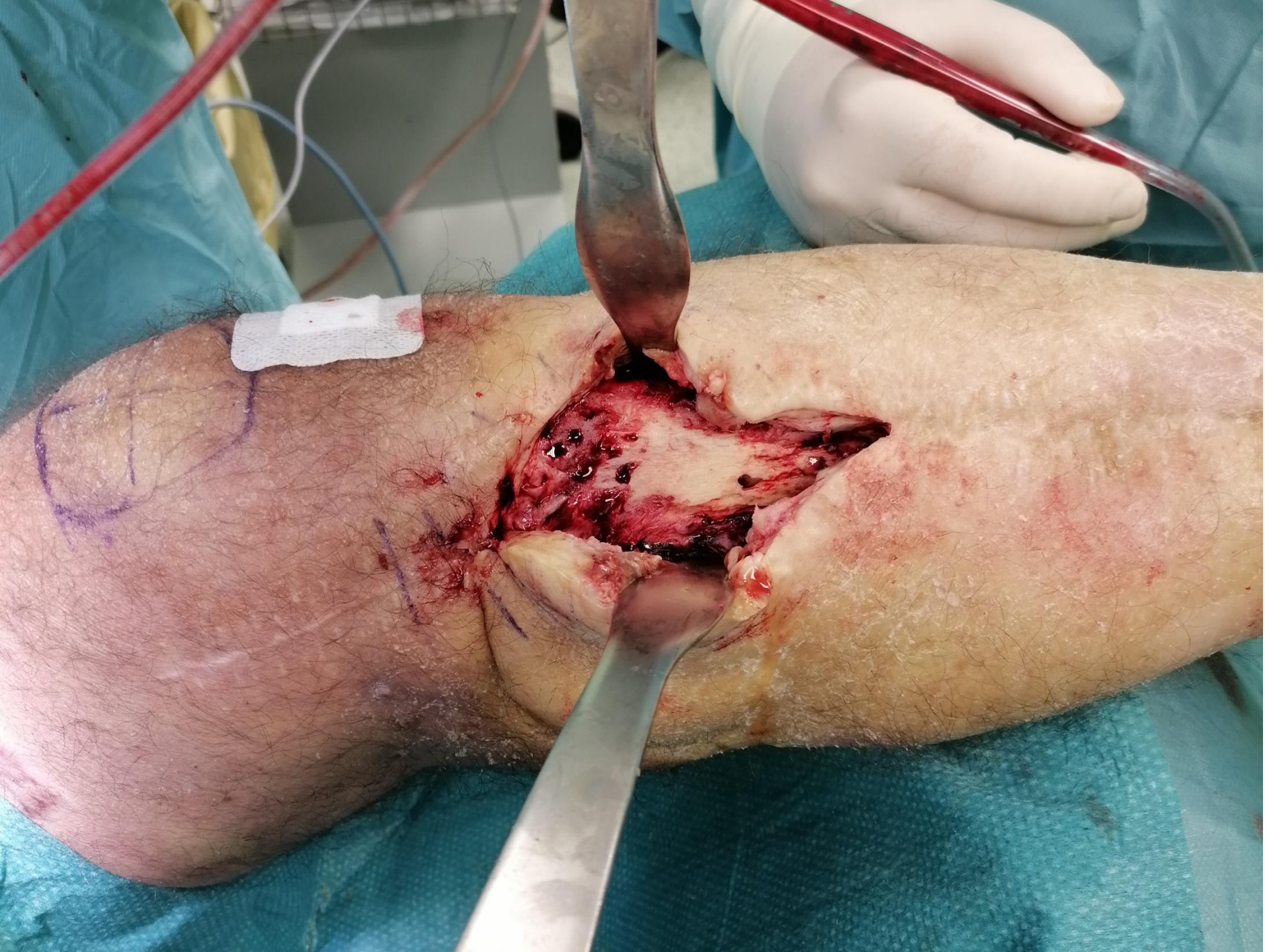S 180

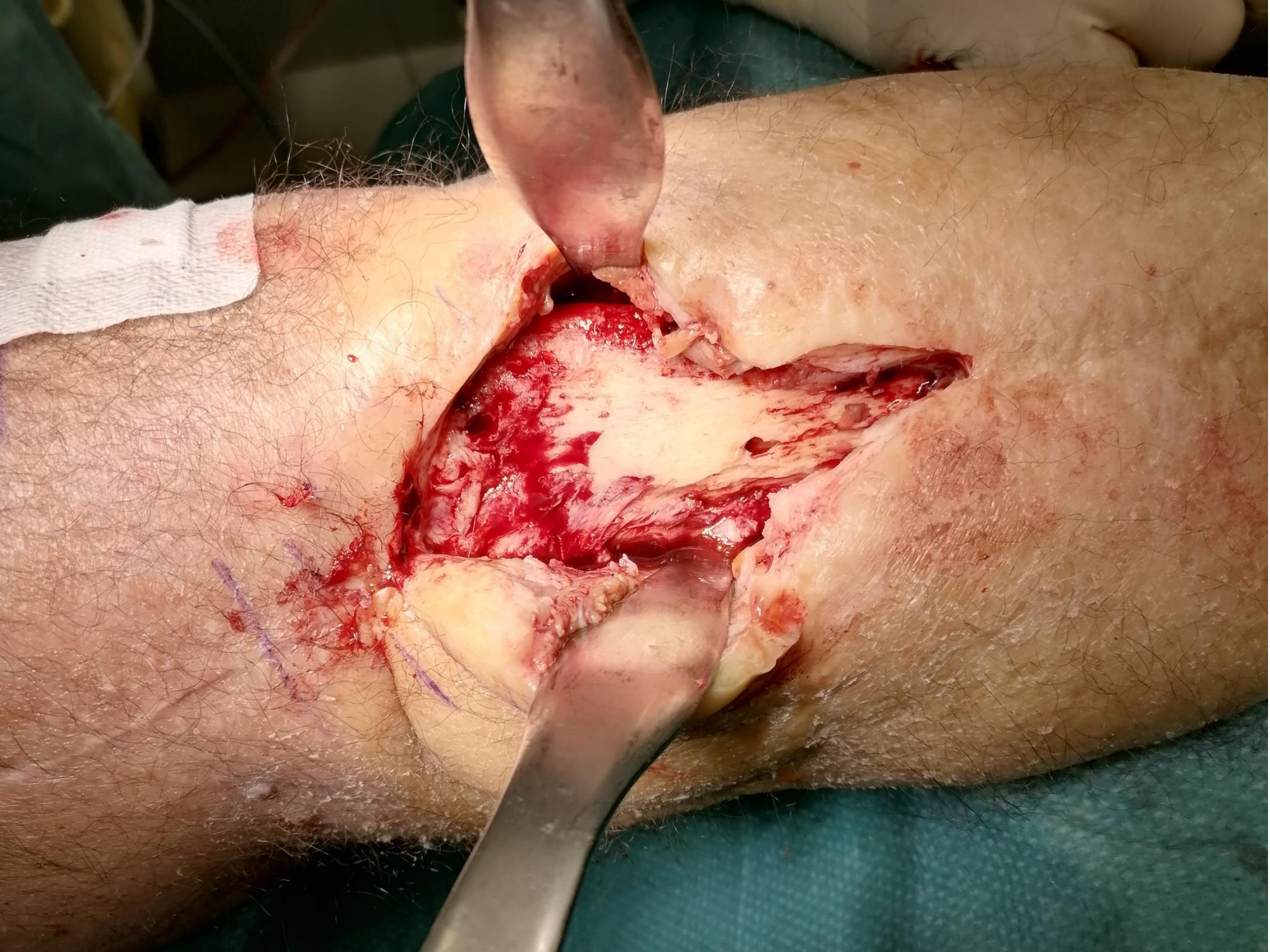P
4
9
7

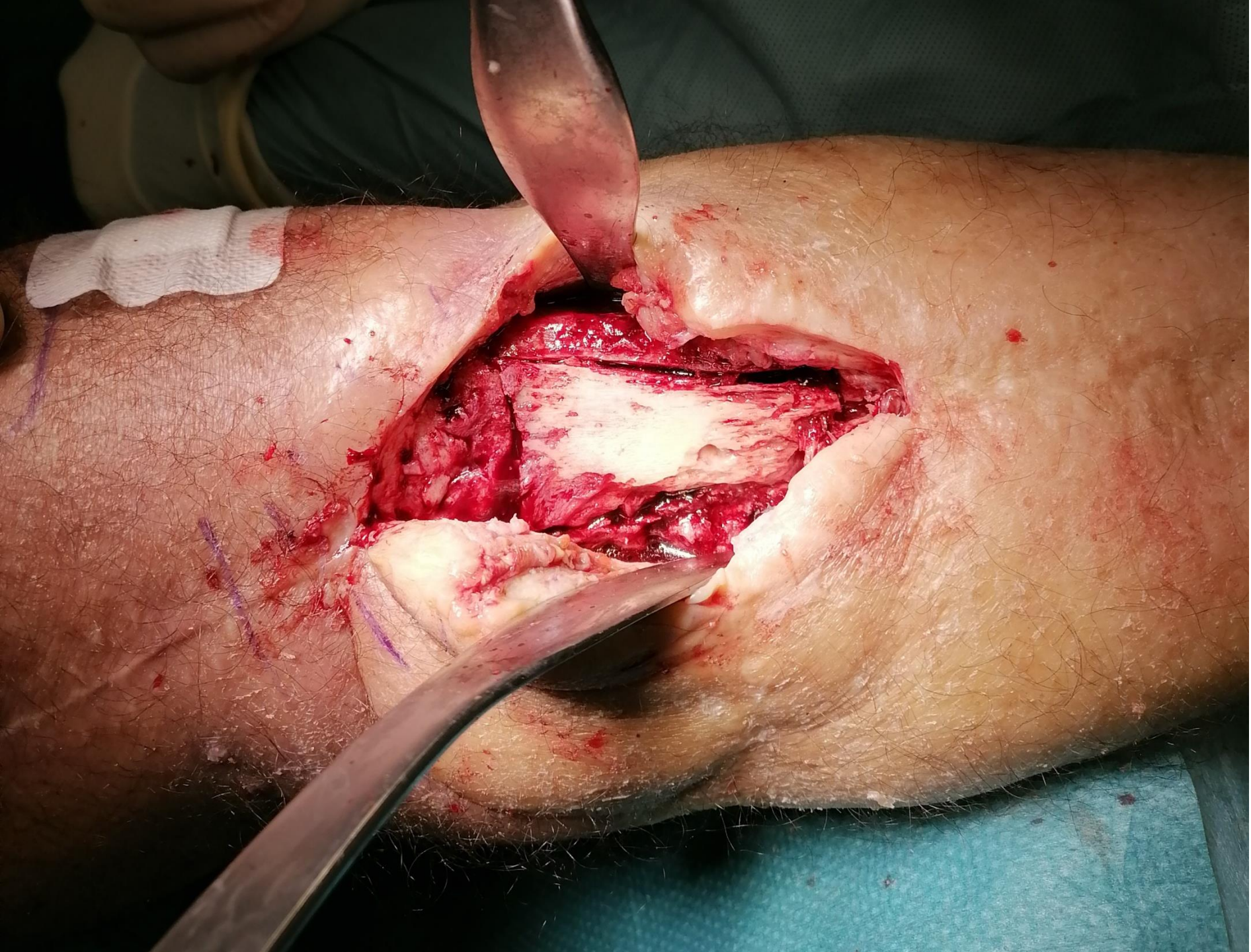1253/15

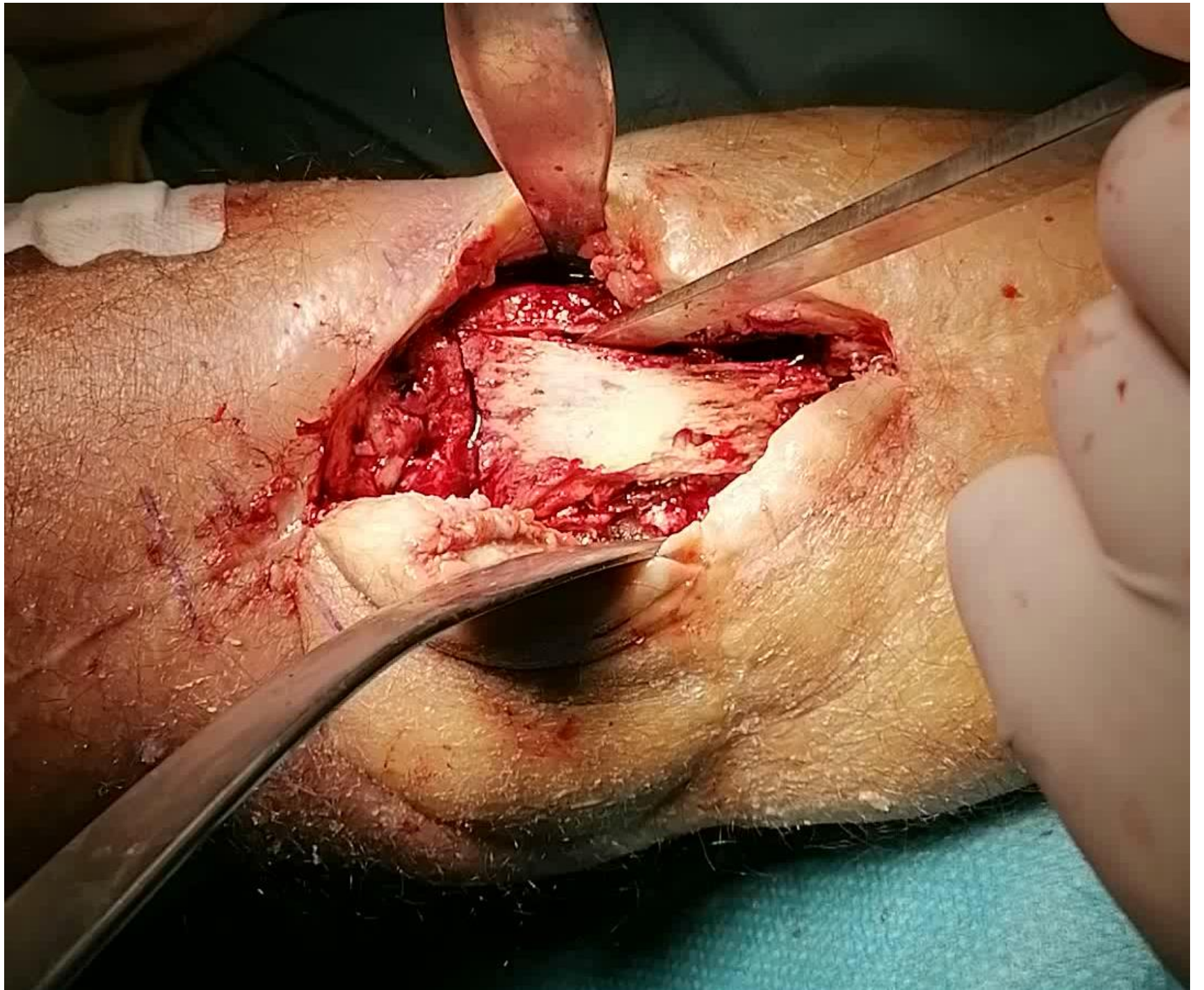
V=0.00

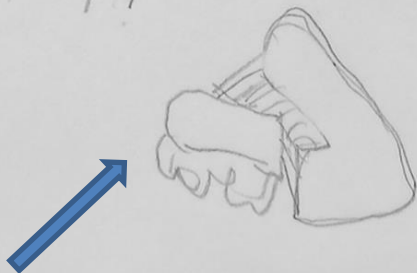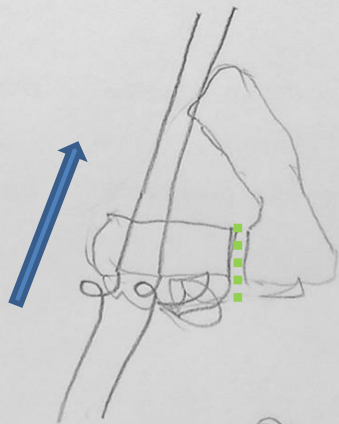
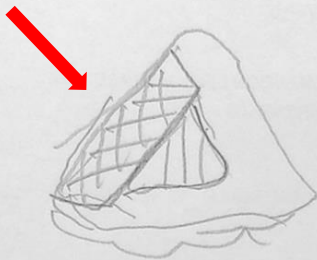

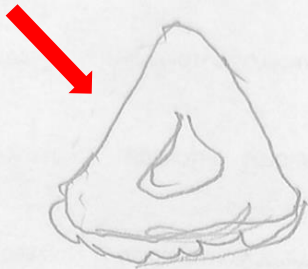
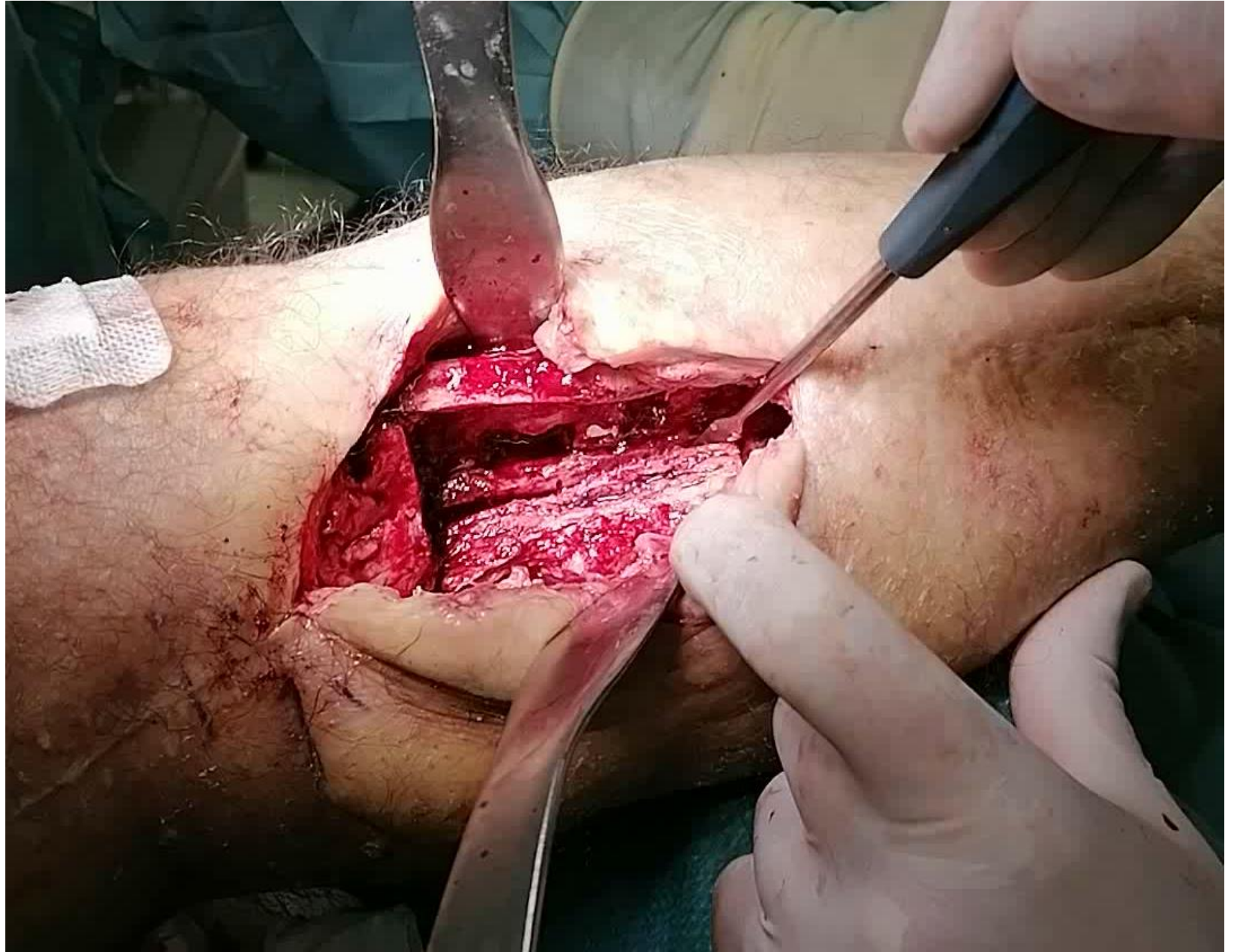




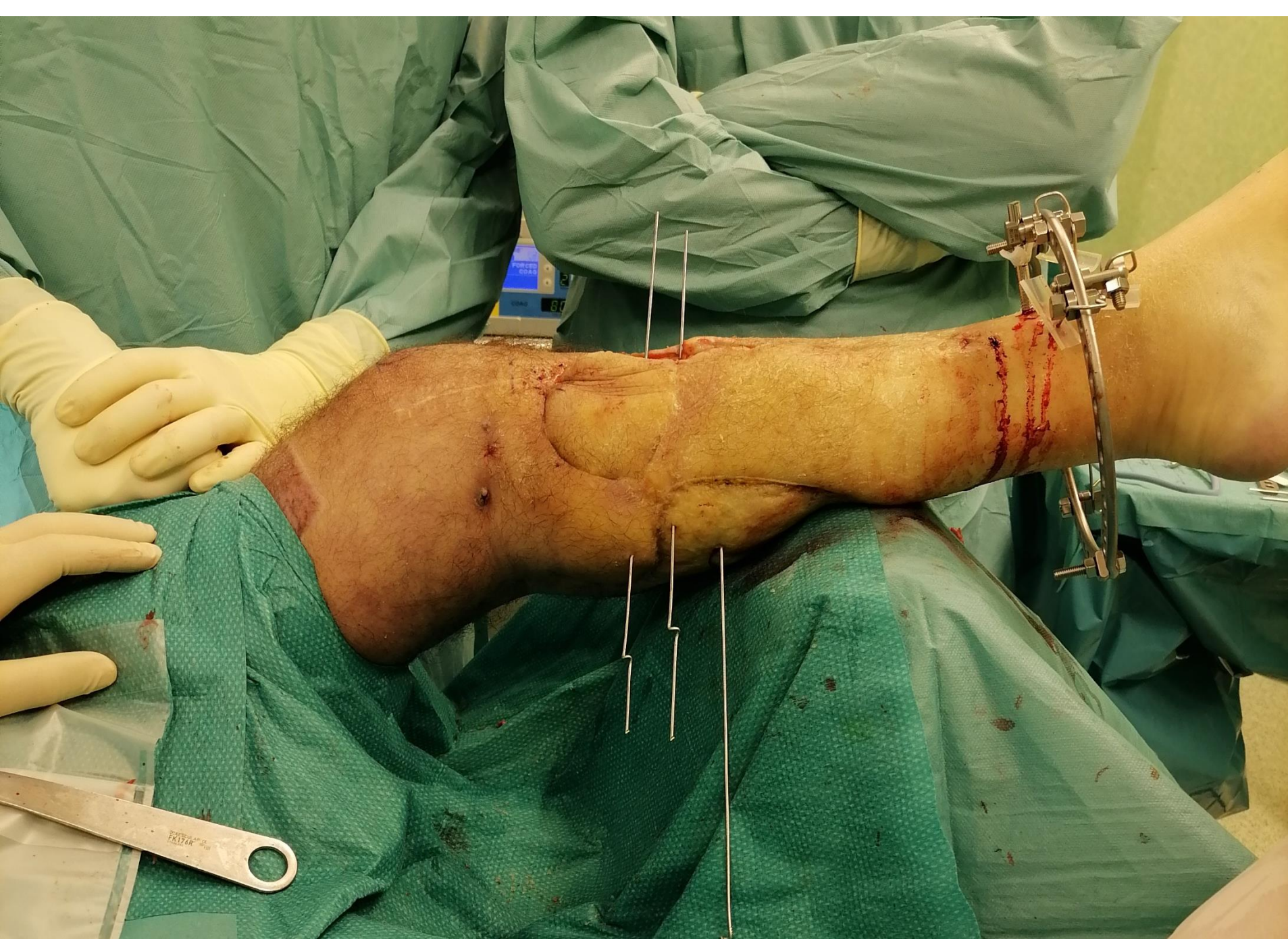


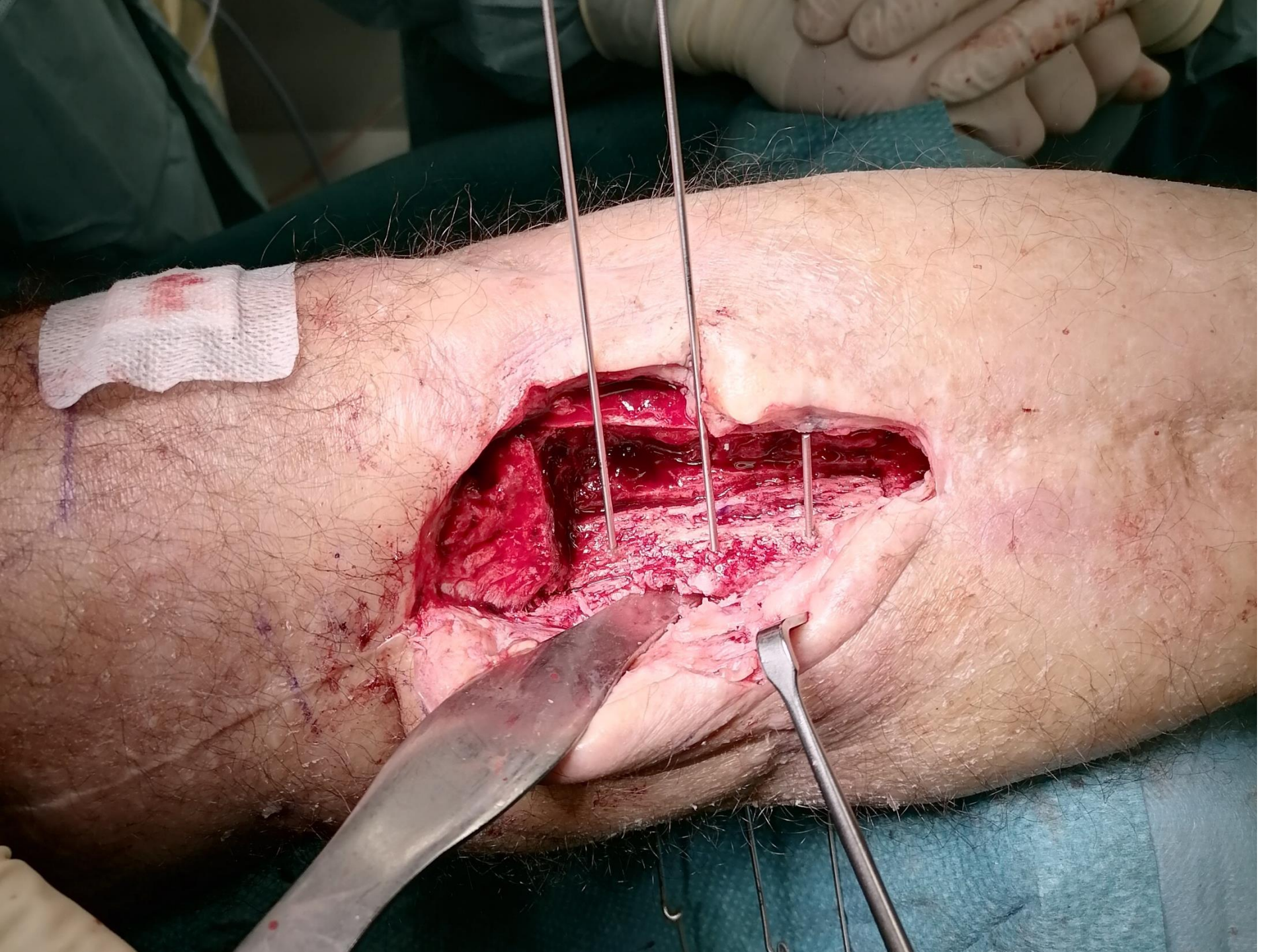


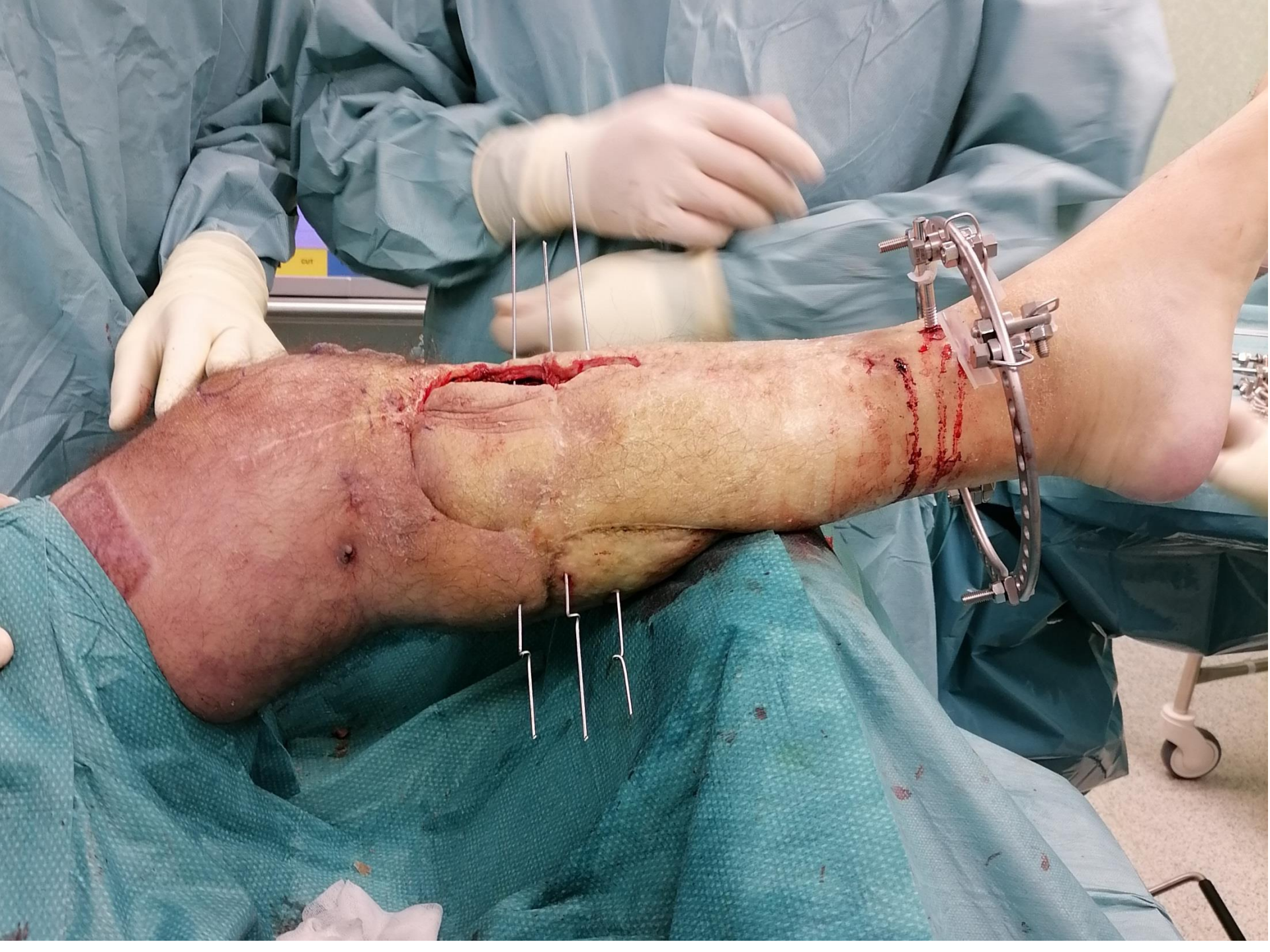

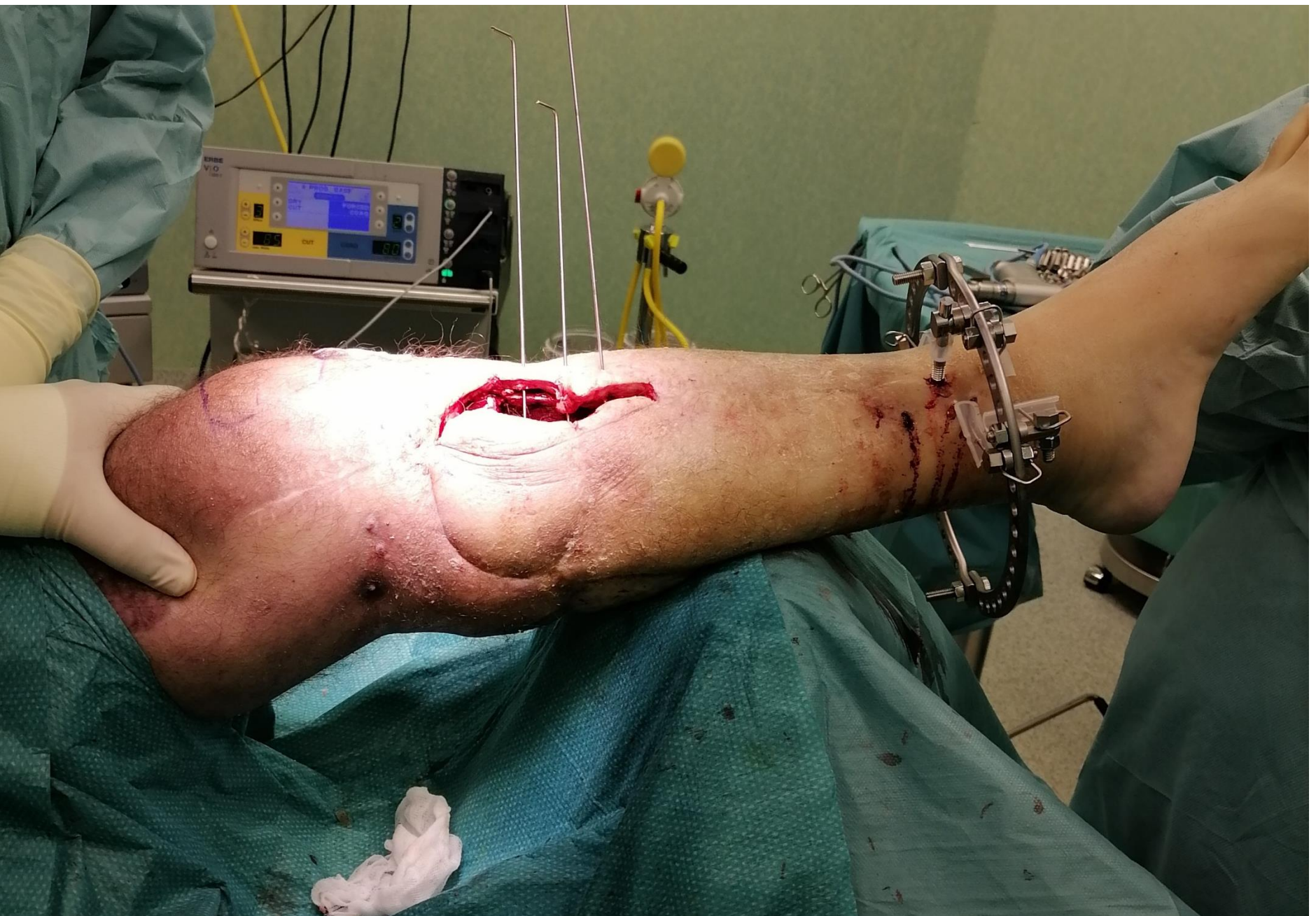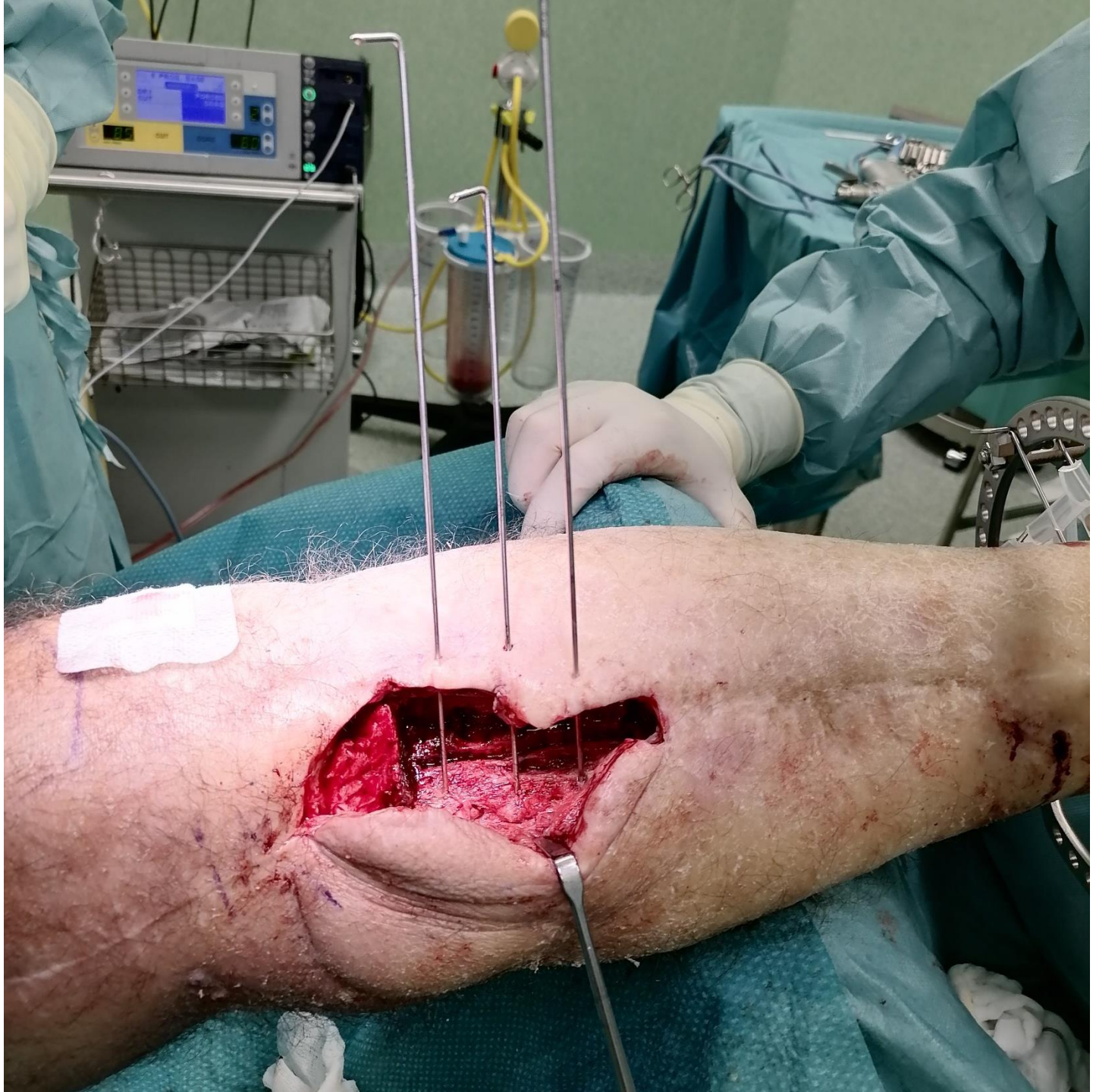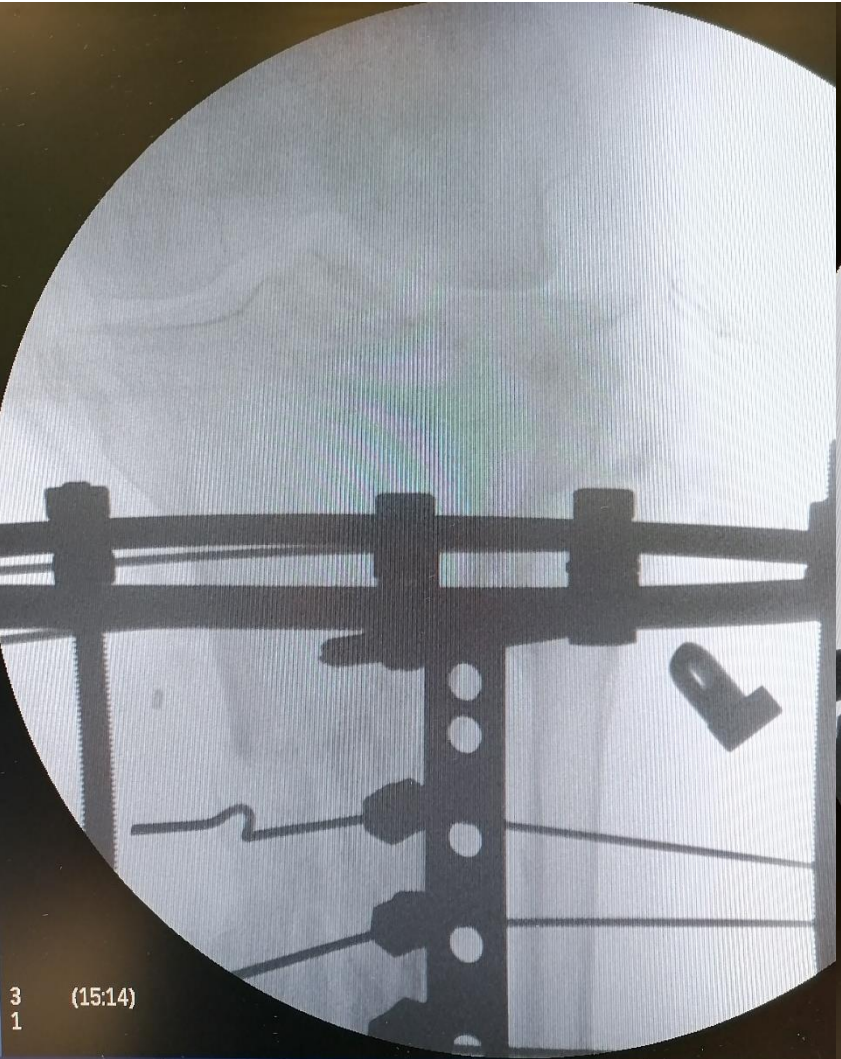




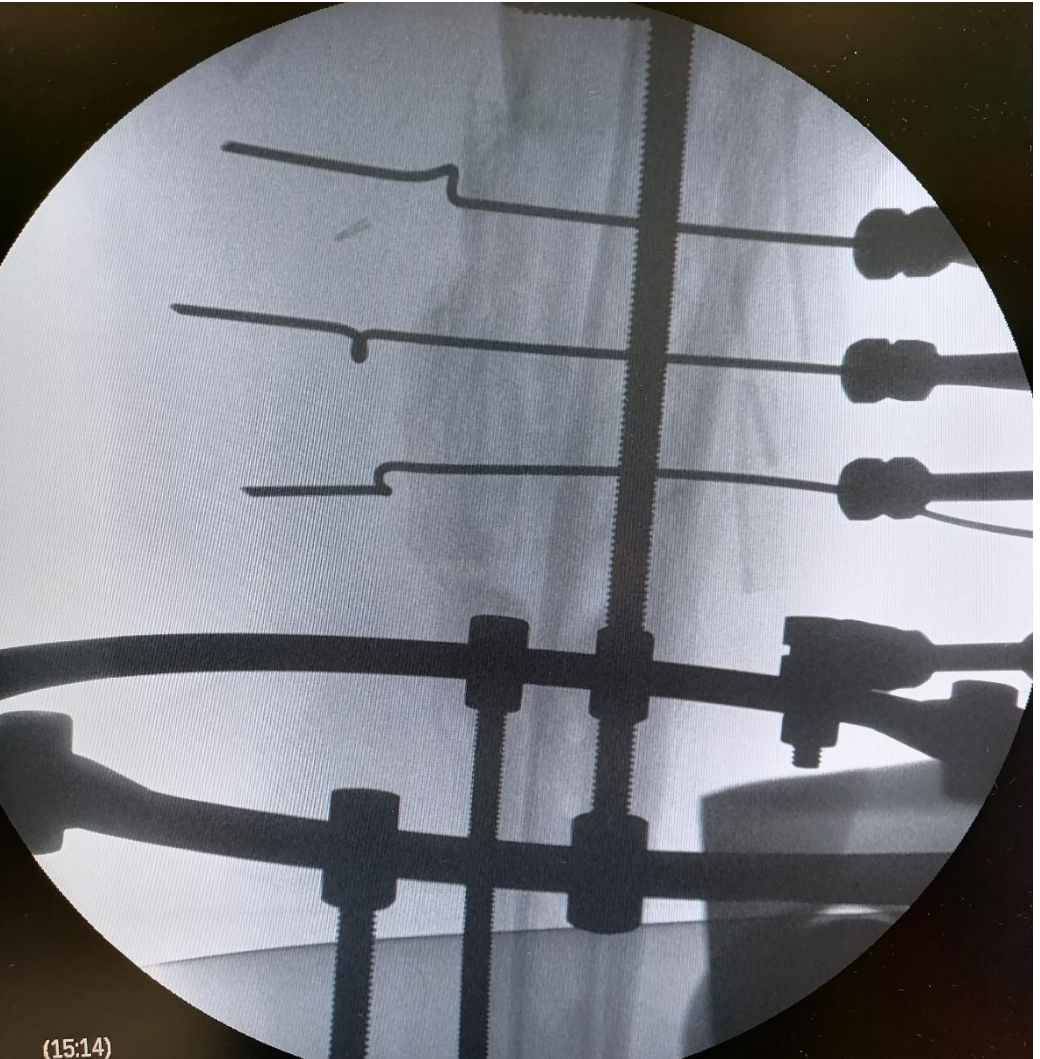






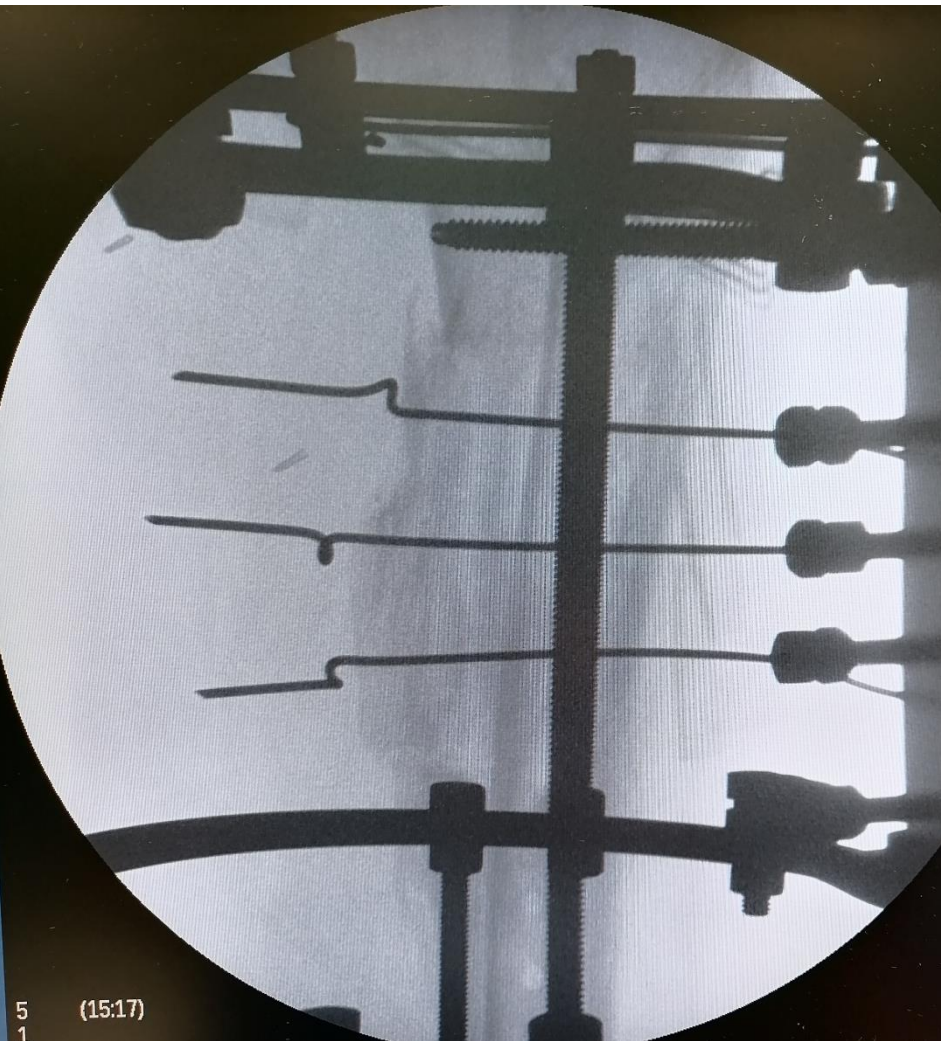


(15:14)



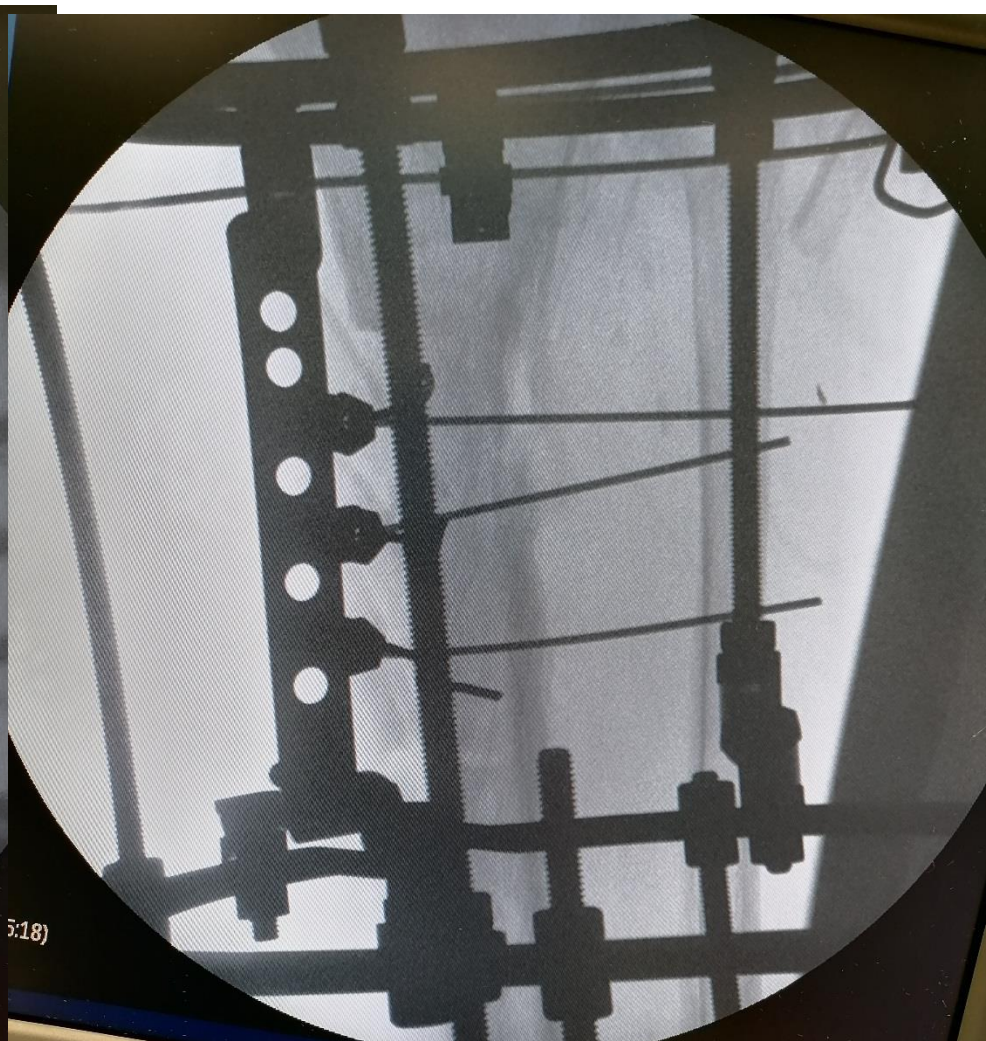
(15:14)

3
1

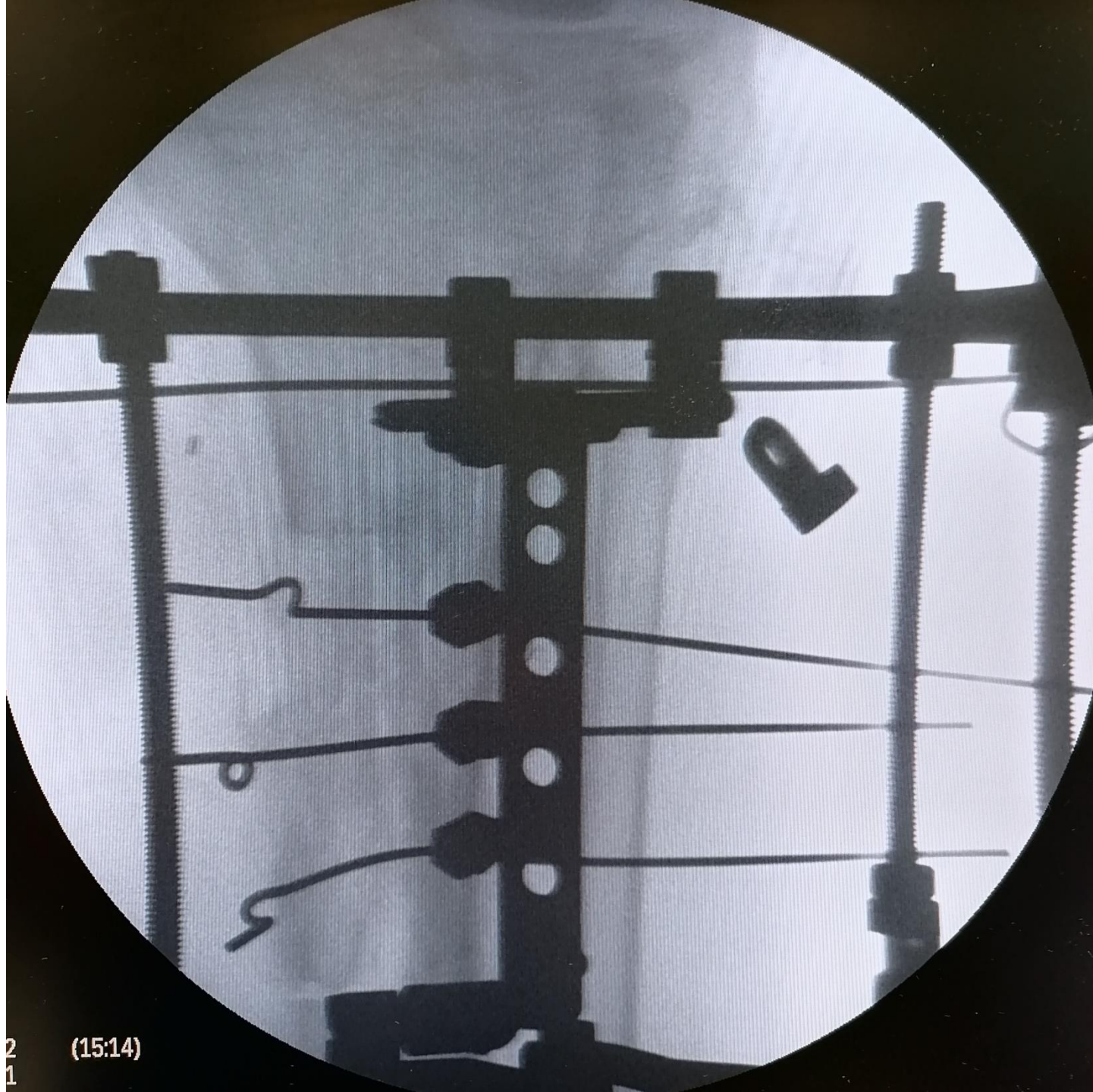


5
1

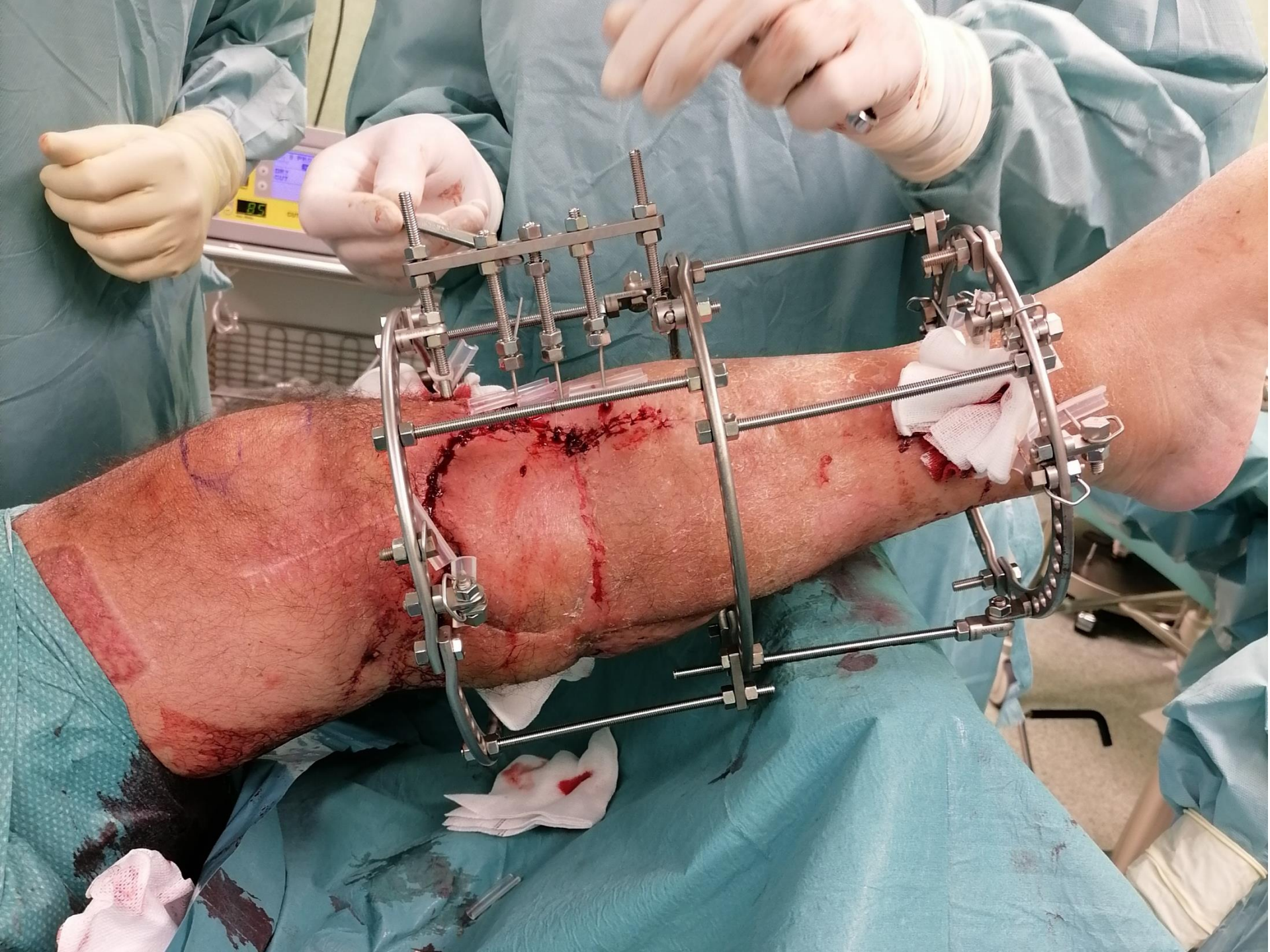
(15:17)

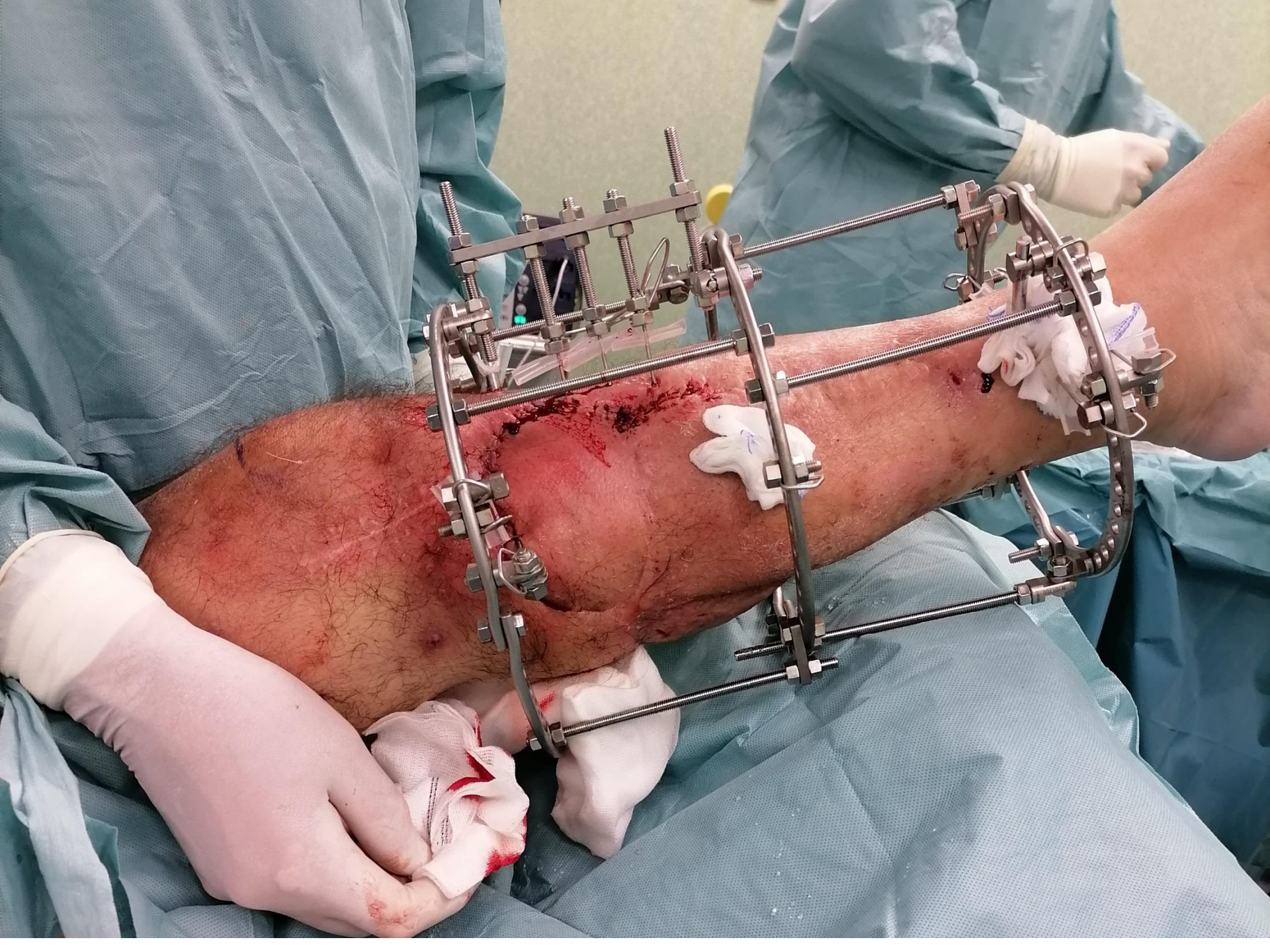


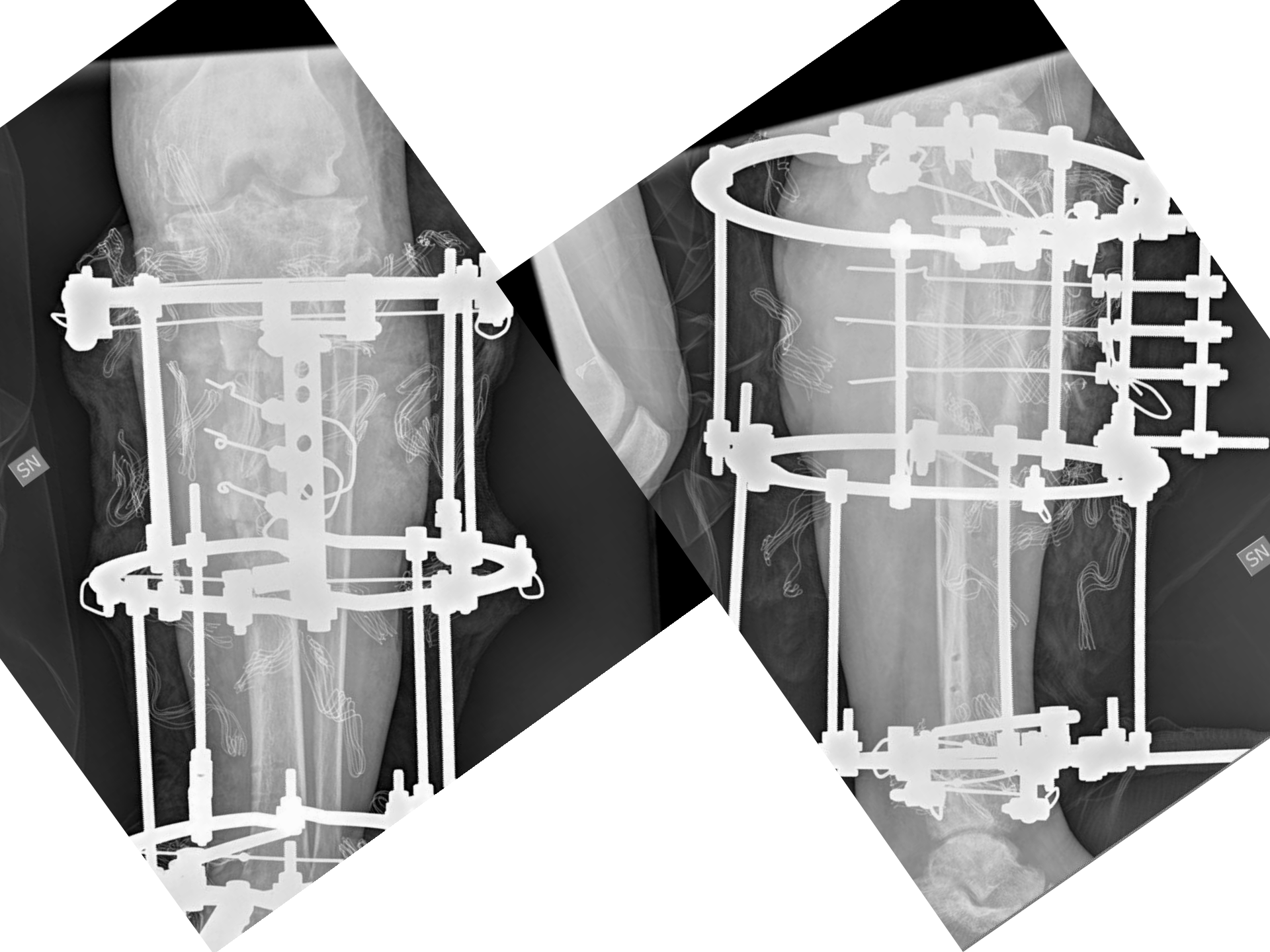
5:18)

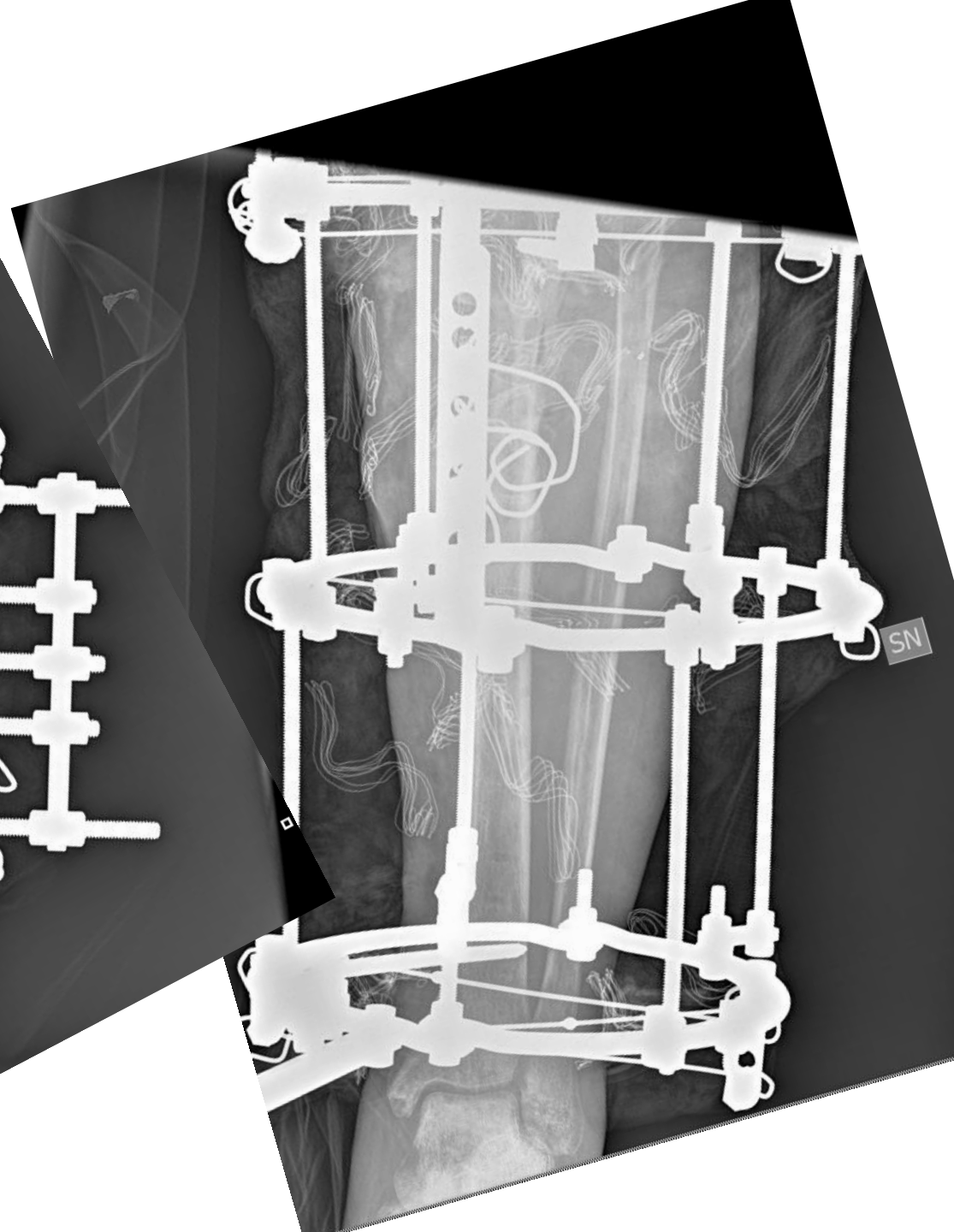
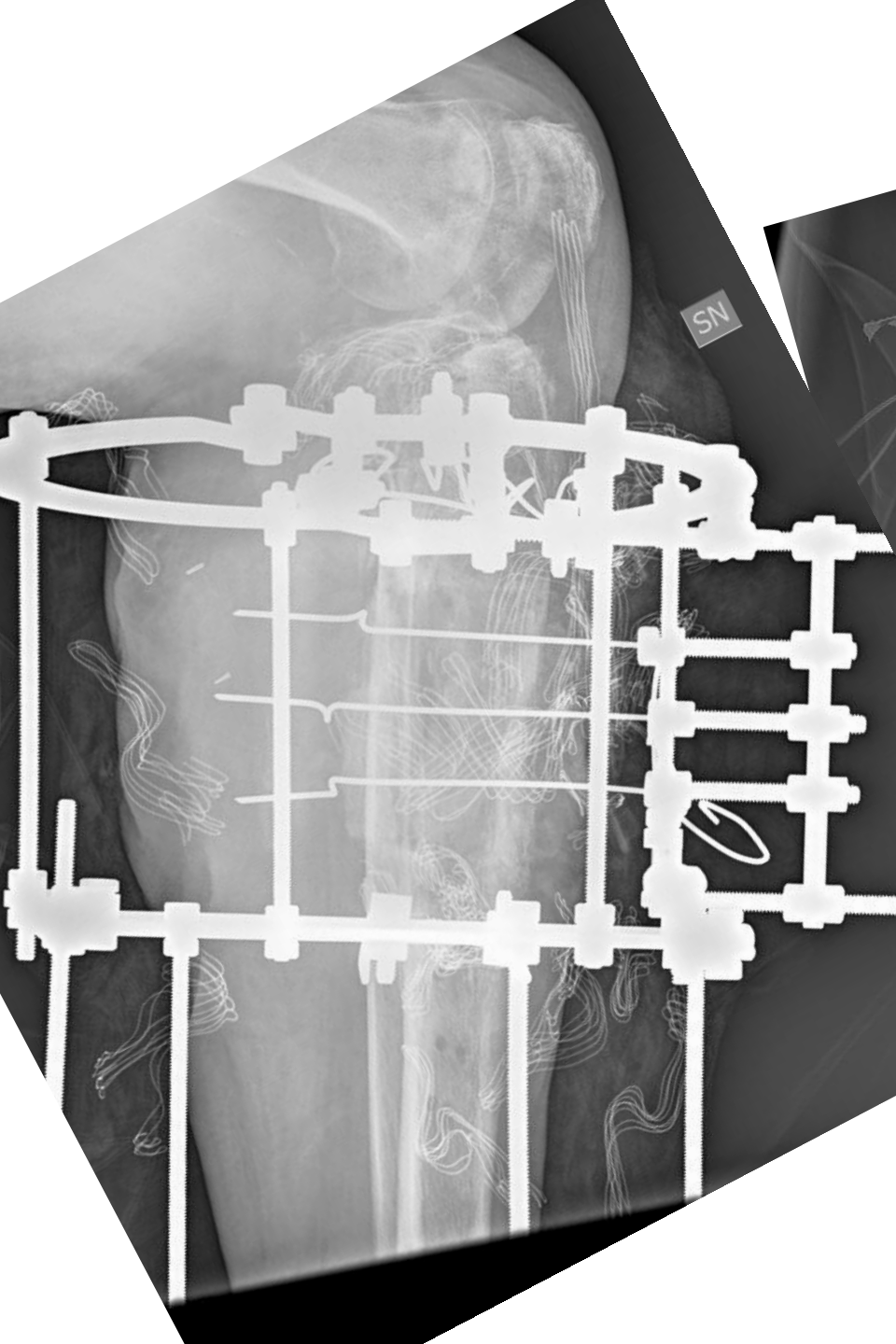


(15:14)










18/10/2022



L

