

I fallimenti della fissazione esterna: Conversione alla fissazione interna

Marco Berlusconi
Istituto Ortopedico Gaetano Pini - Milano

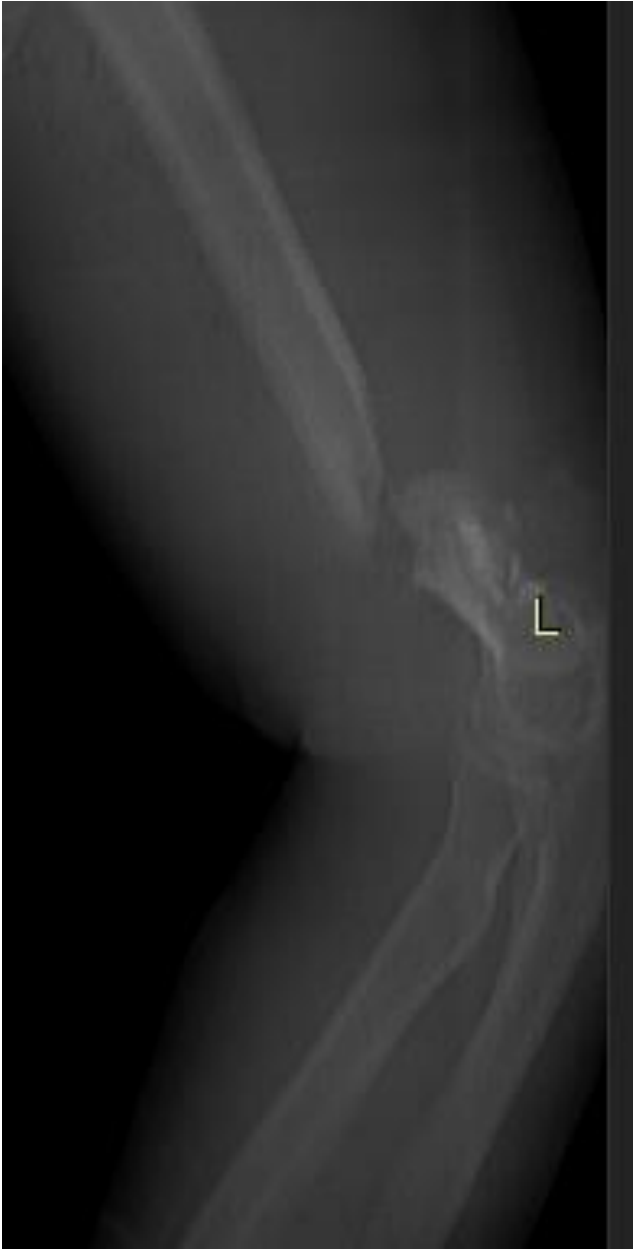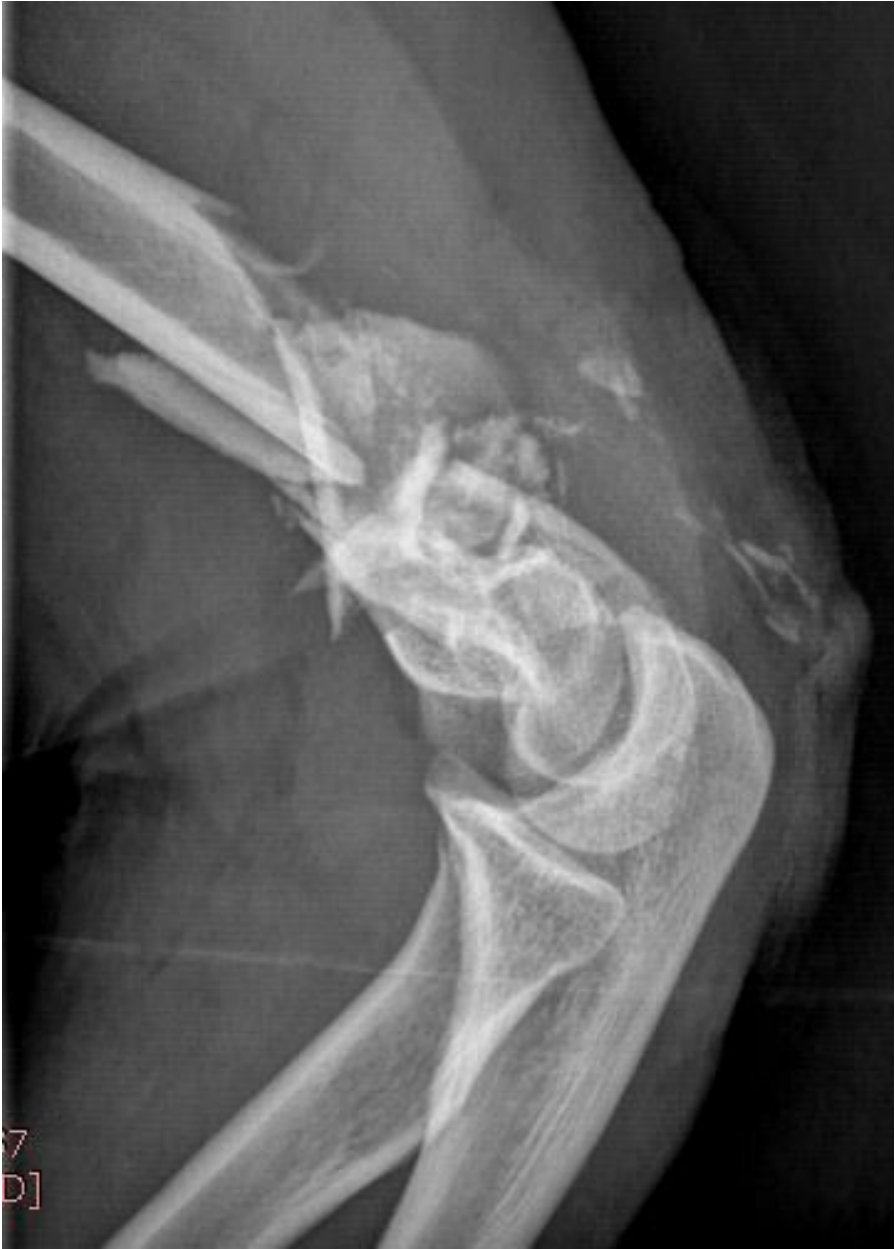Chair AO Trauma Europe and South Africa
marcoberlusconi62@gmail.com

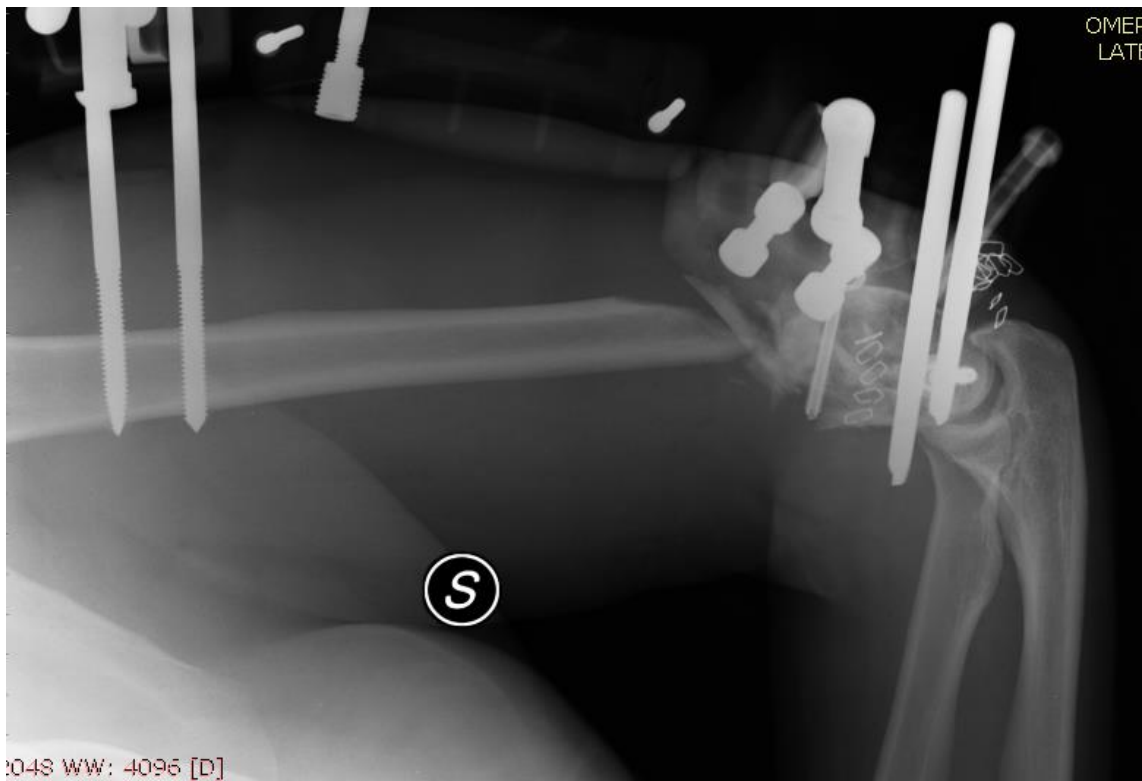
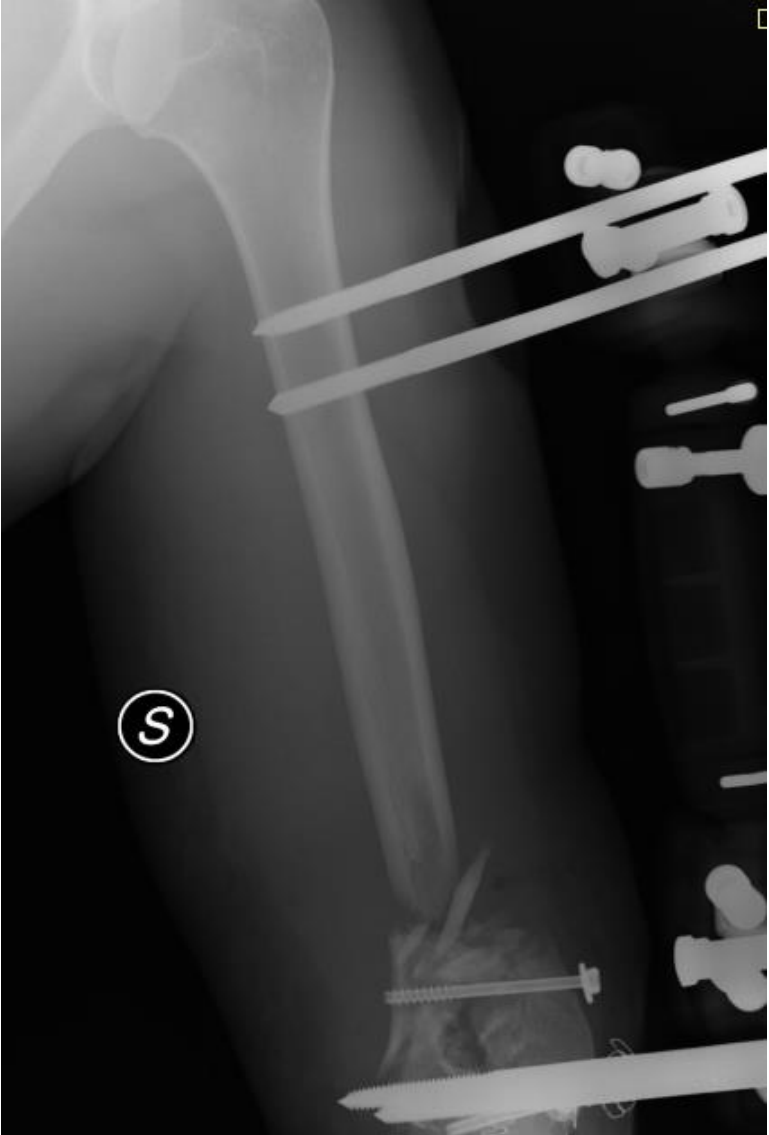SIFE ottobre 2023
Milano

1. Principi
2. Tecnica
3. Complicazioni

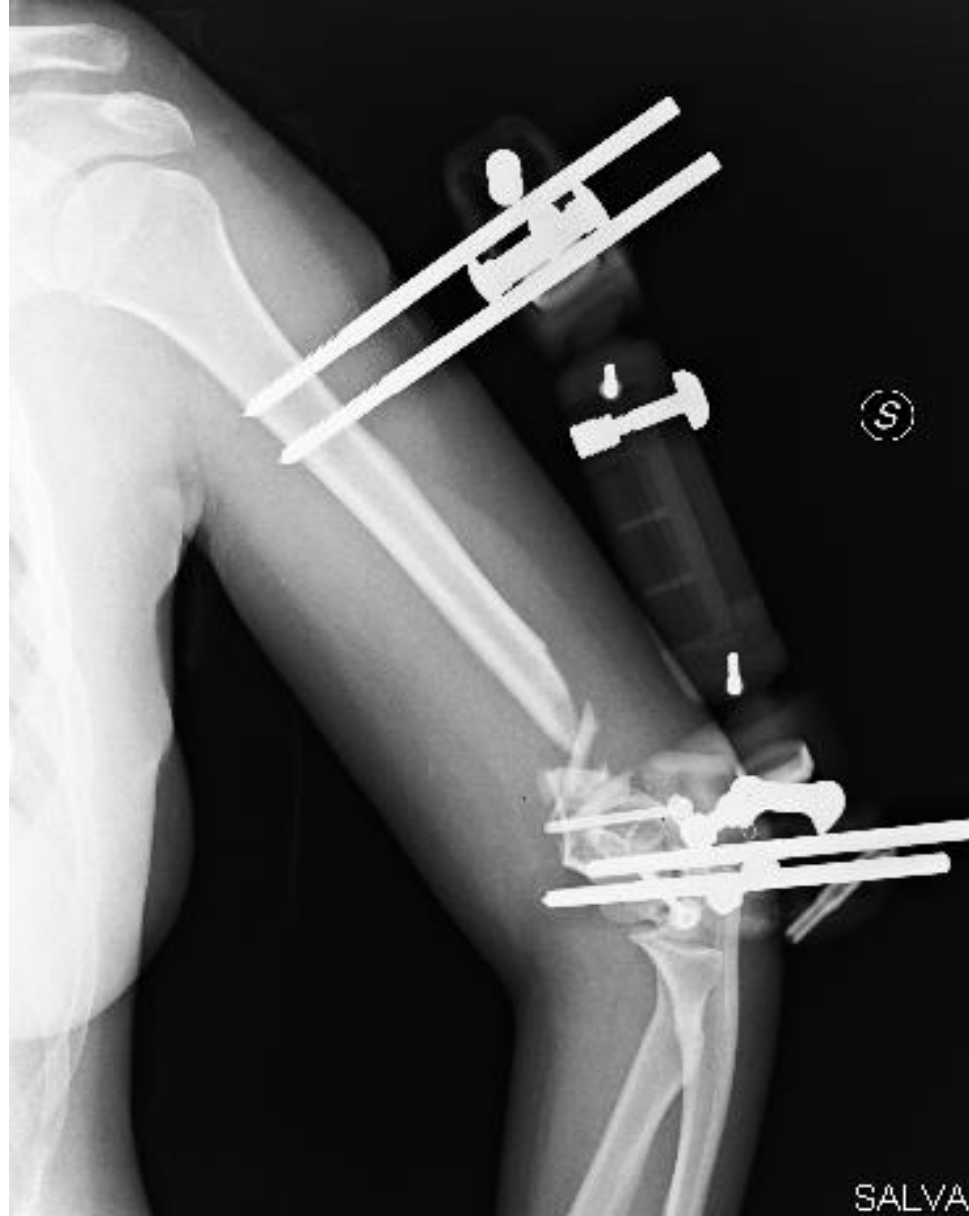Principi

DONNA AA26 GENNAIO 2011 CADUTA IN MONTAGNA
esposta 2

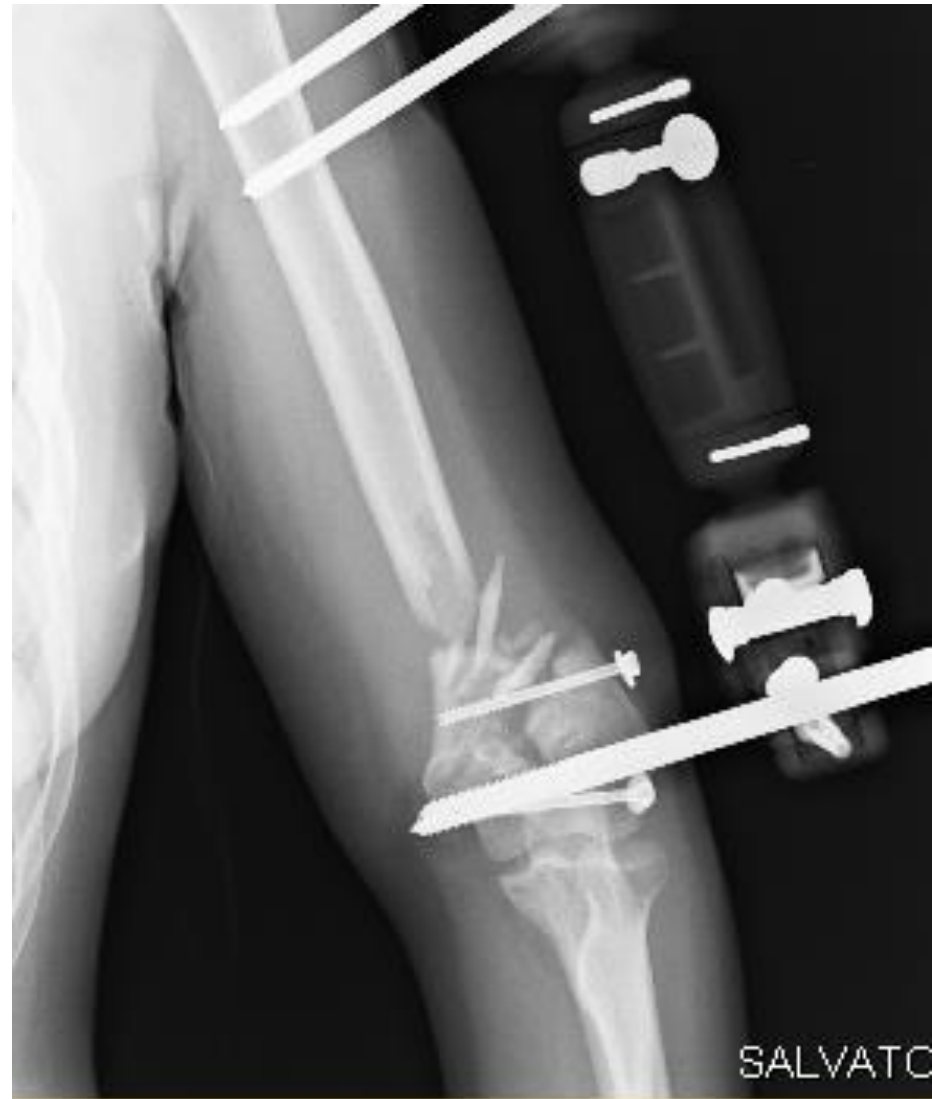



2048 WW: 4096 [D]

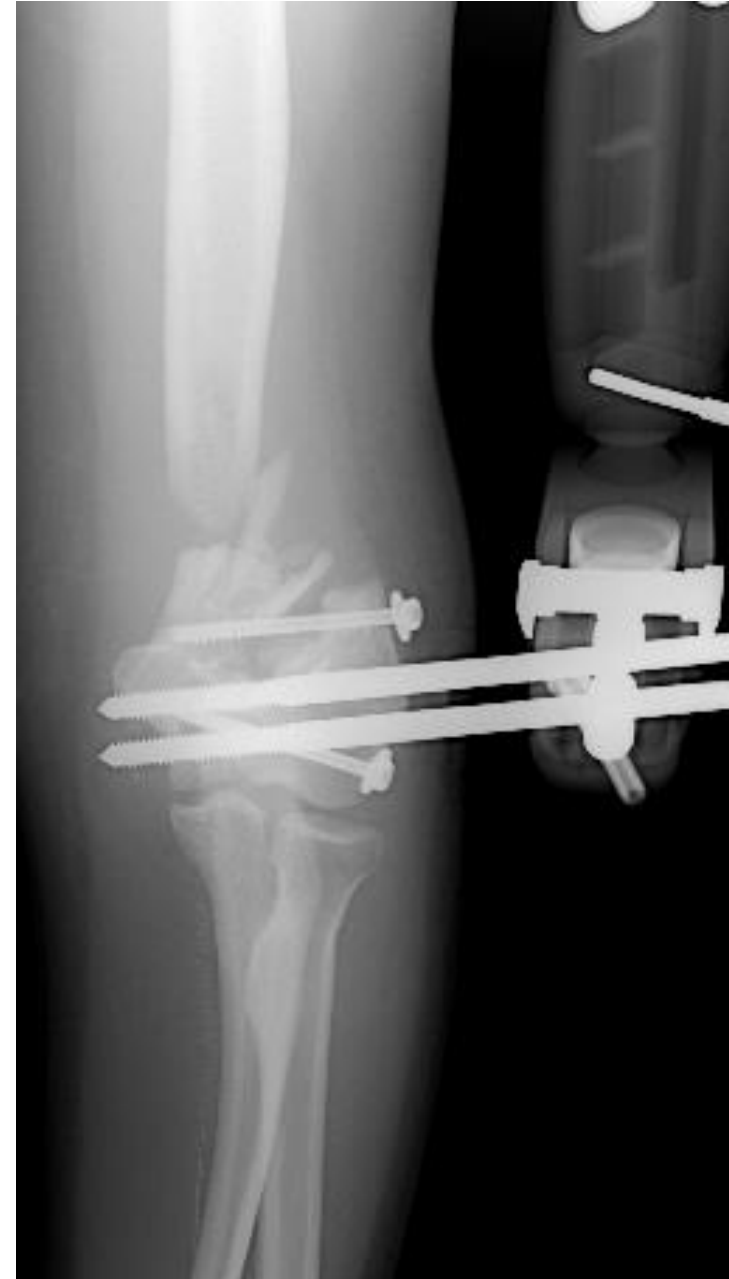
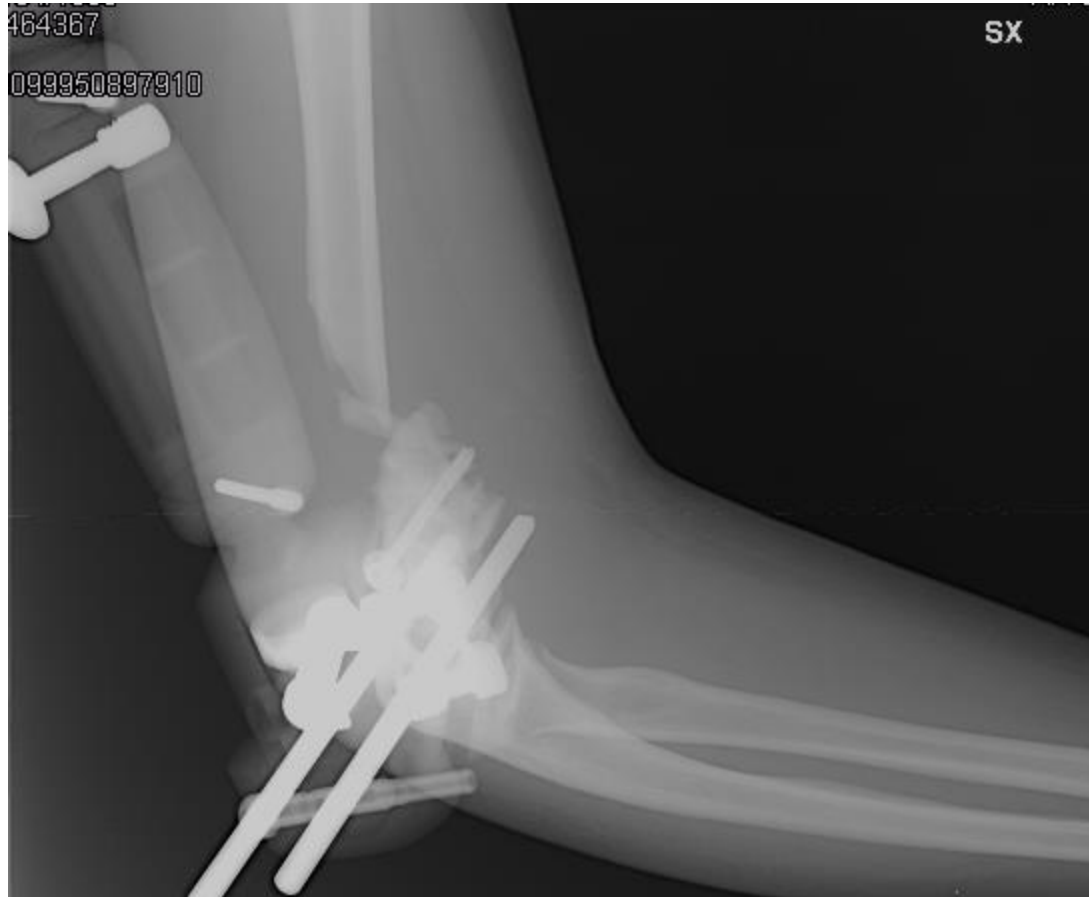
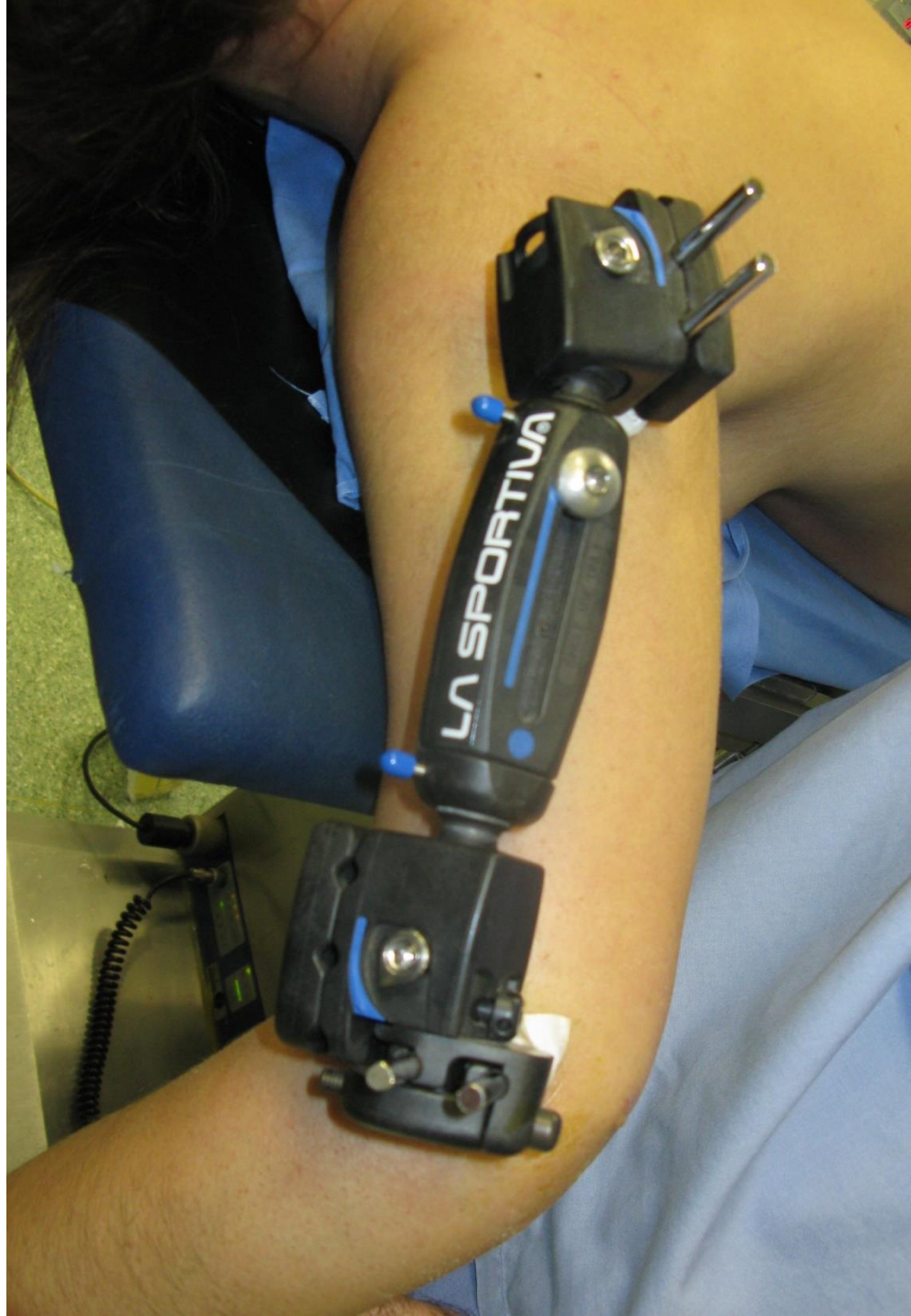
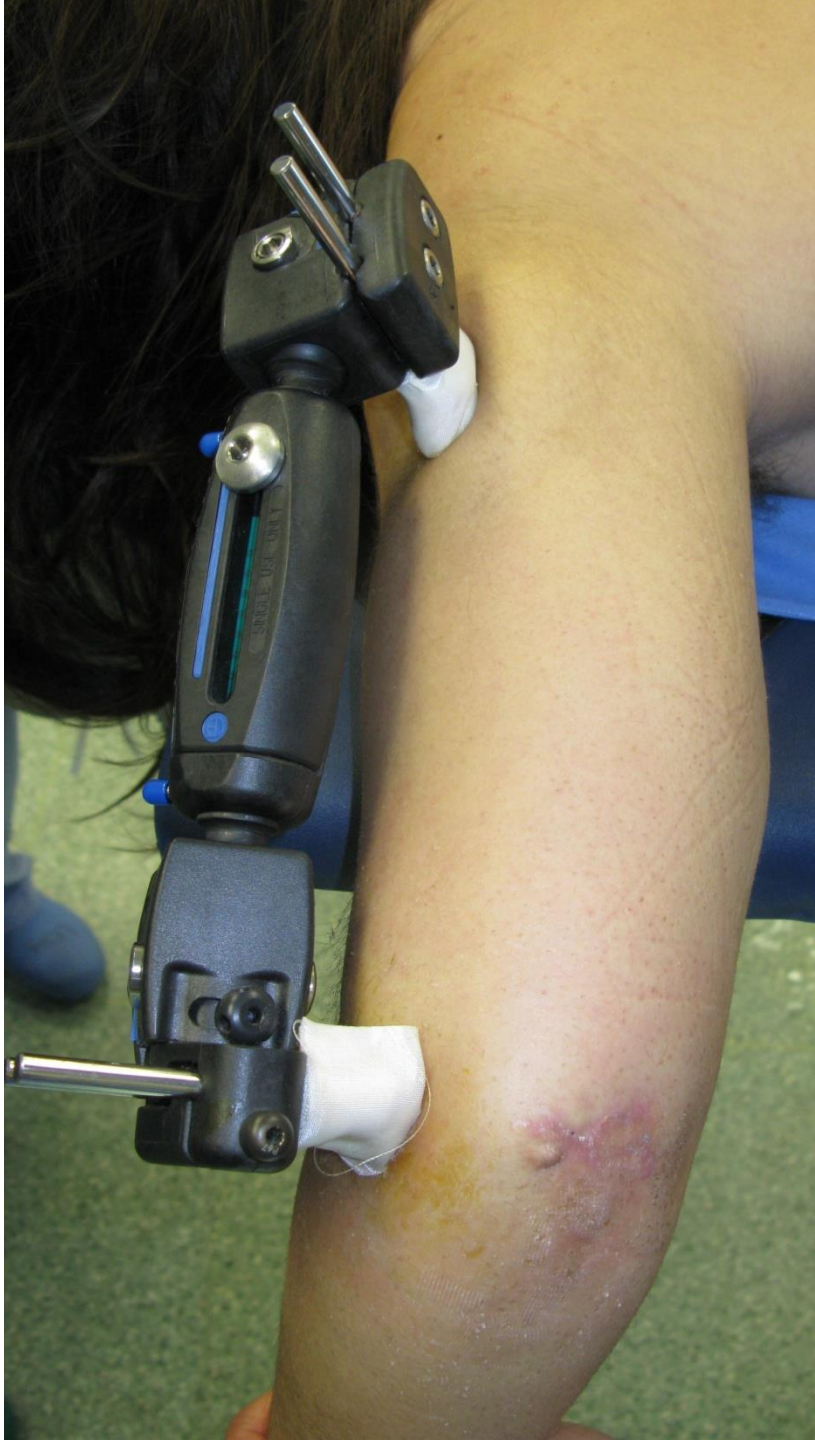Marzo 2011 a 2 mesi



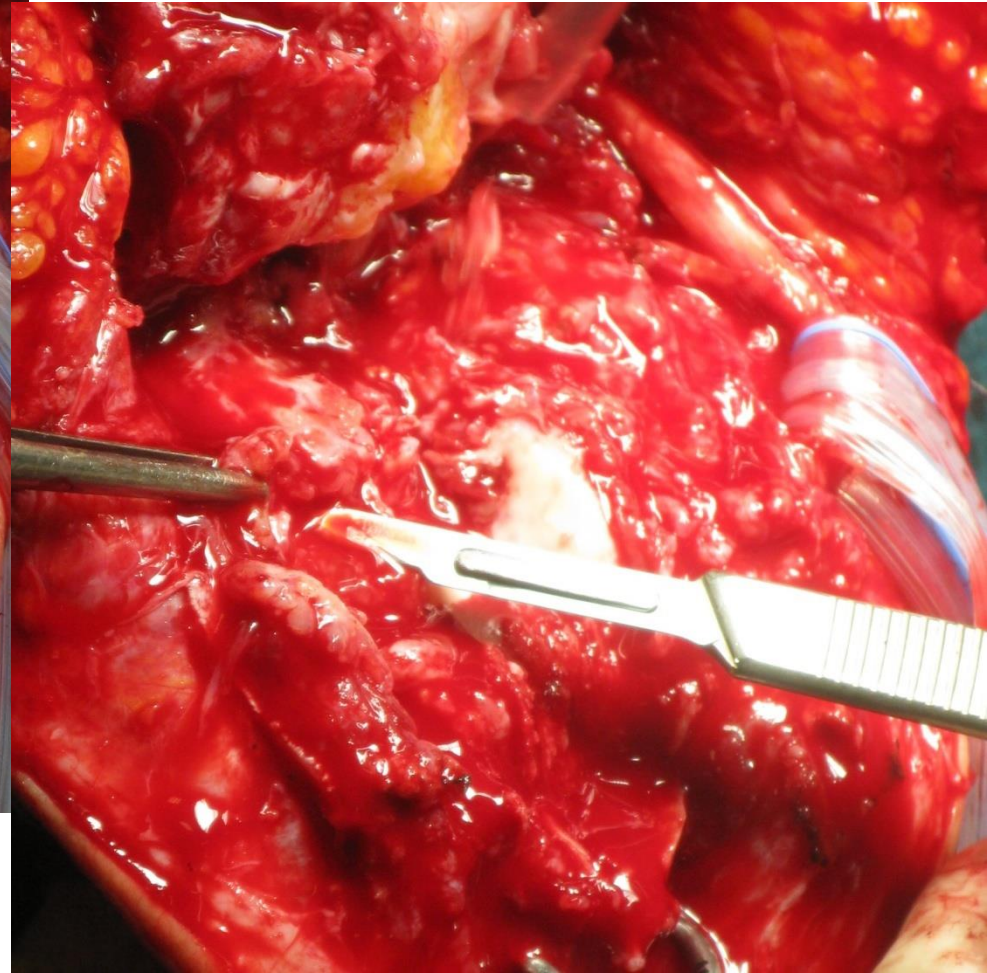
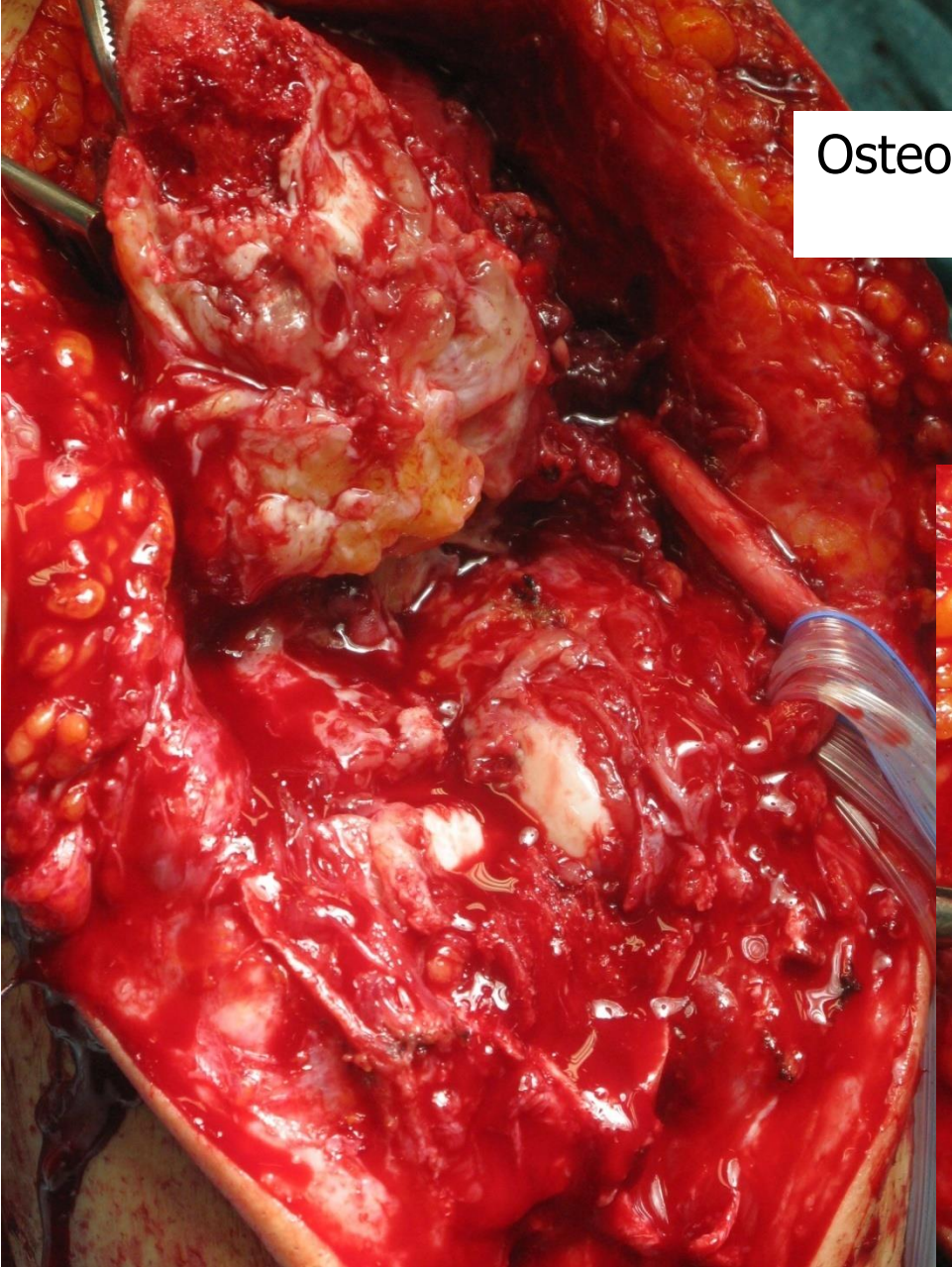
AO

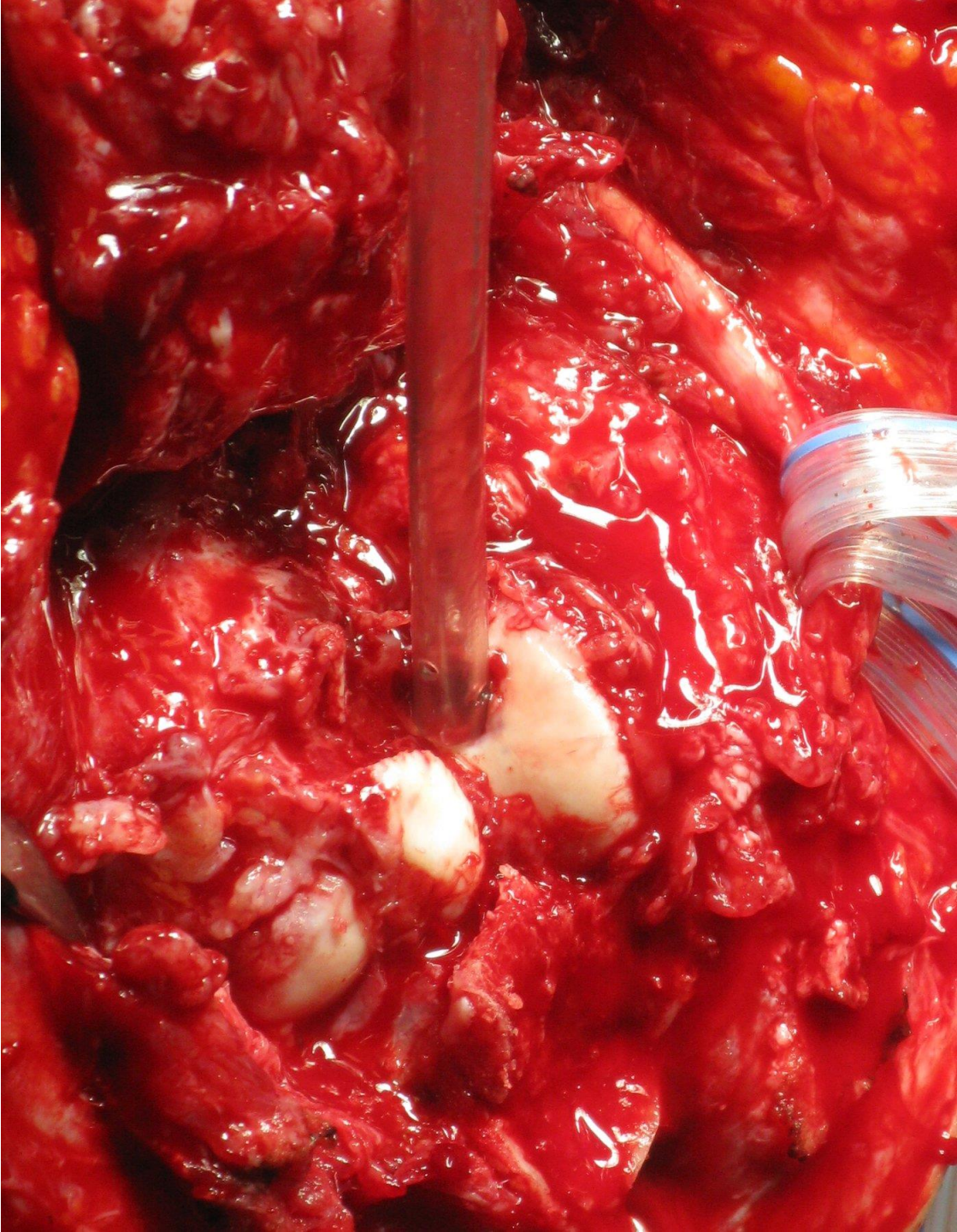
Aprile 2011 a 3 mesi





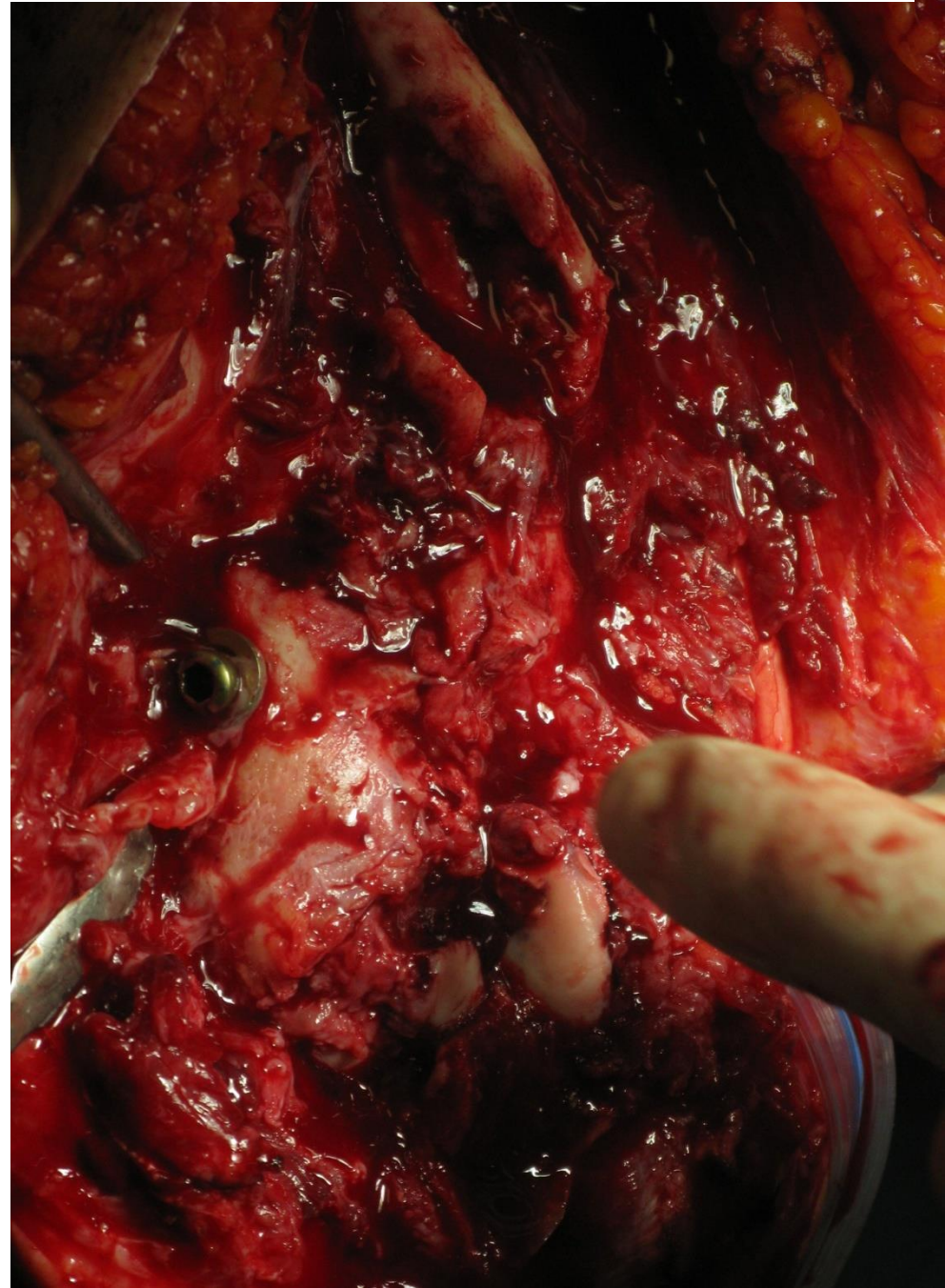
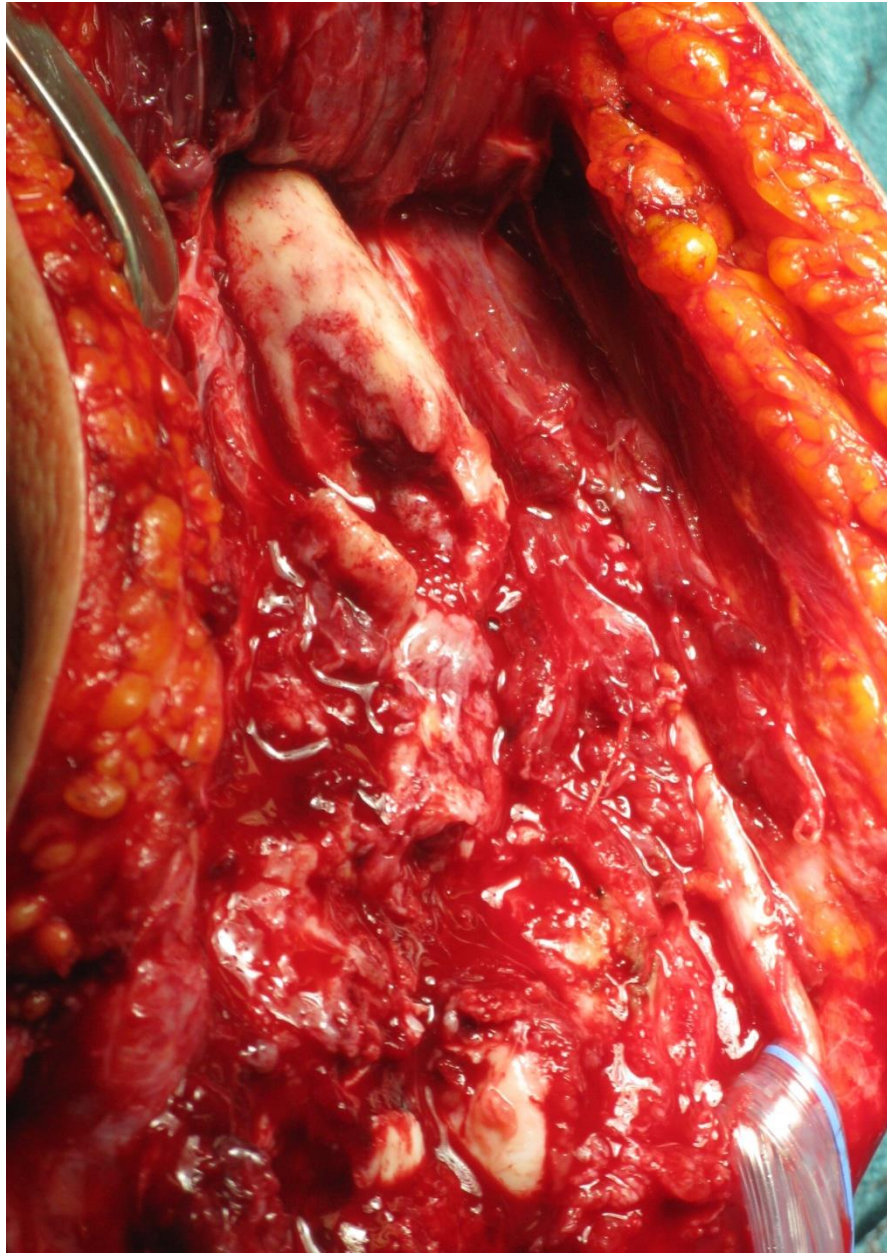
Osteotomia olecrano, isolamento n. ulnare e artrolisi



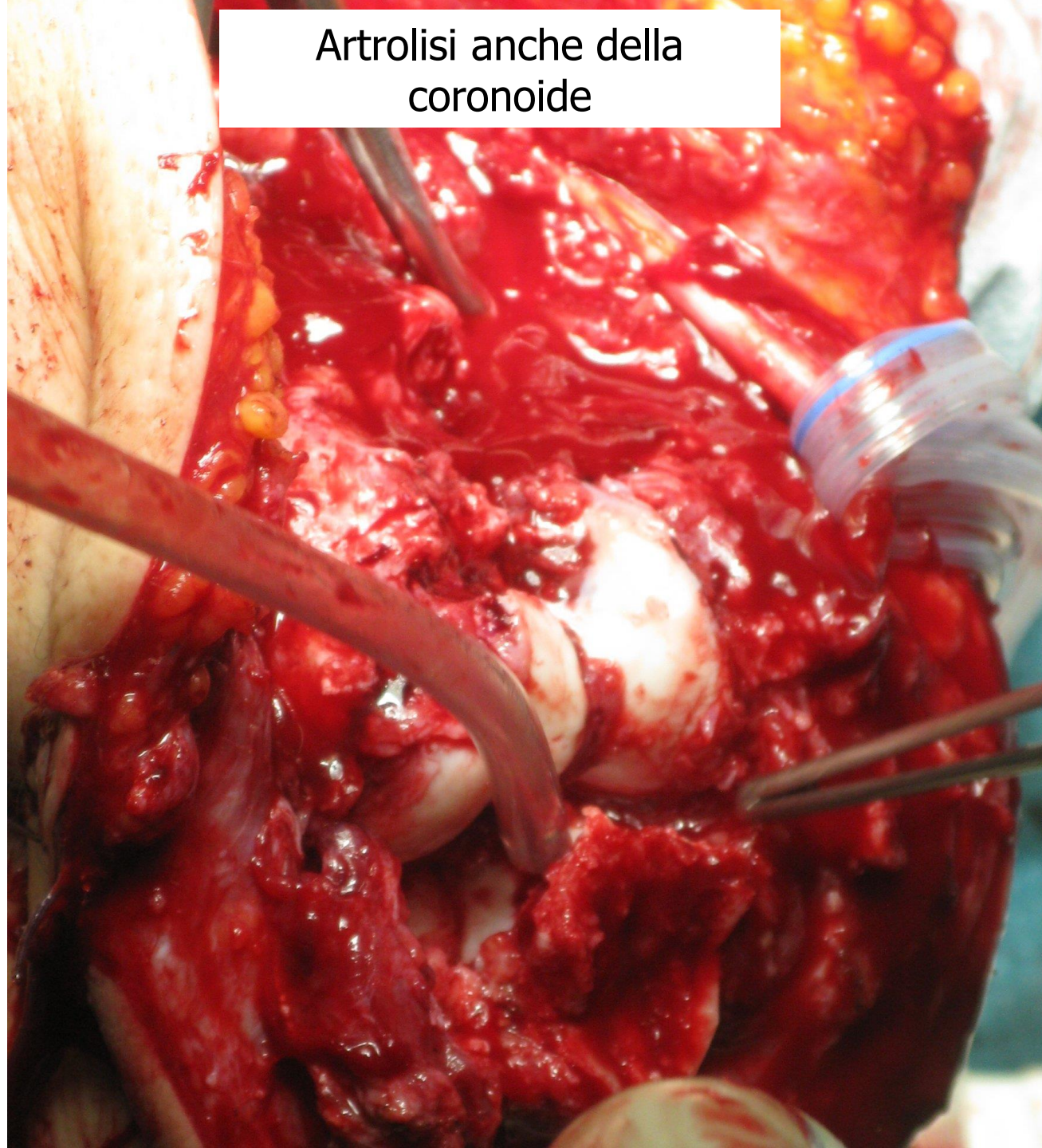

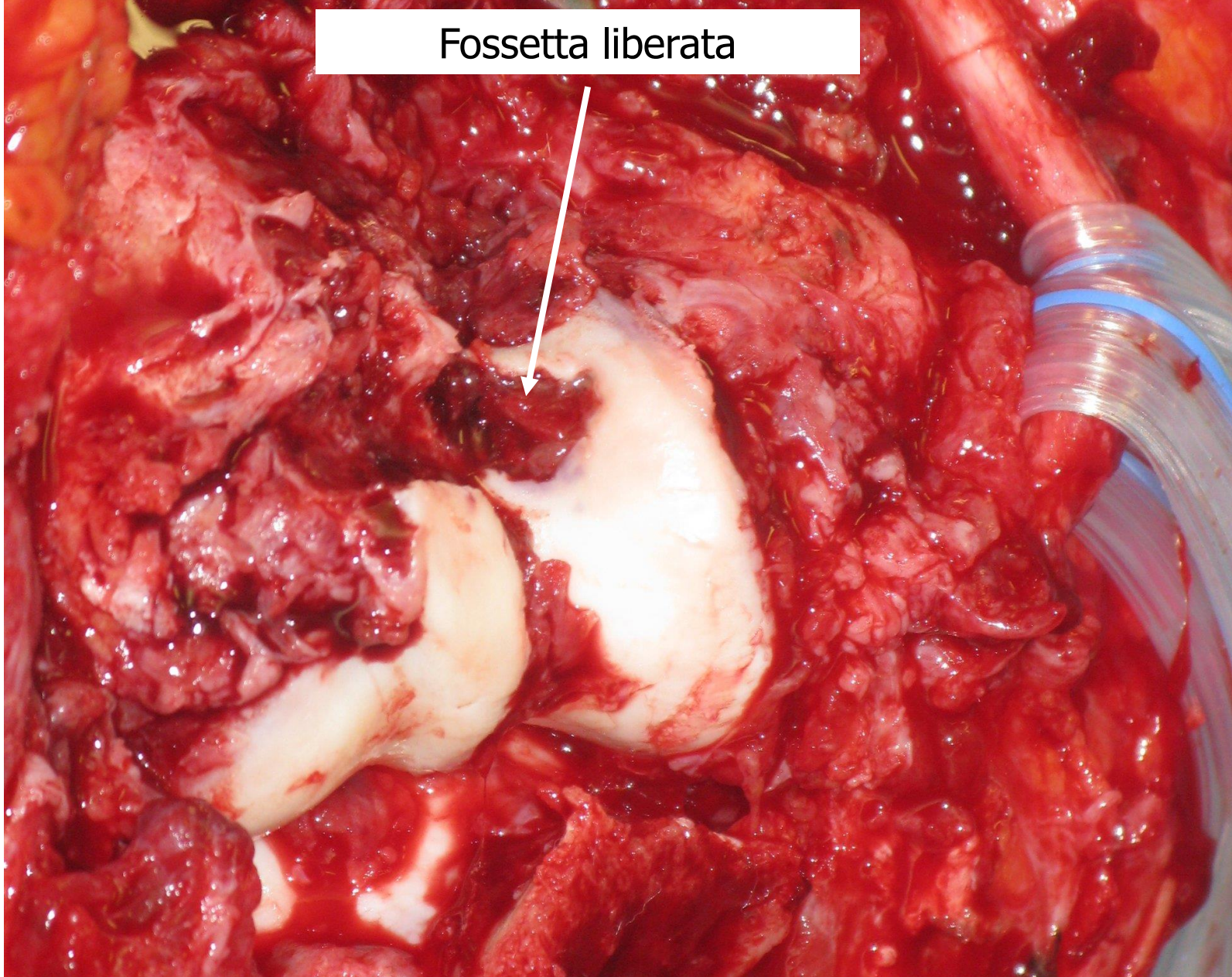
Ricerca della fossetta
olecranica che è ricoperta
da callo esuberante

Liberazione del frammento prossimale, evidenziazione del gap e rimozione viti libere

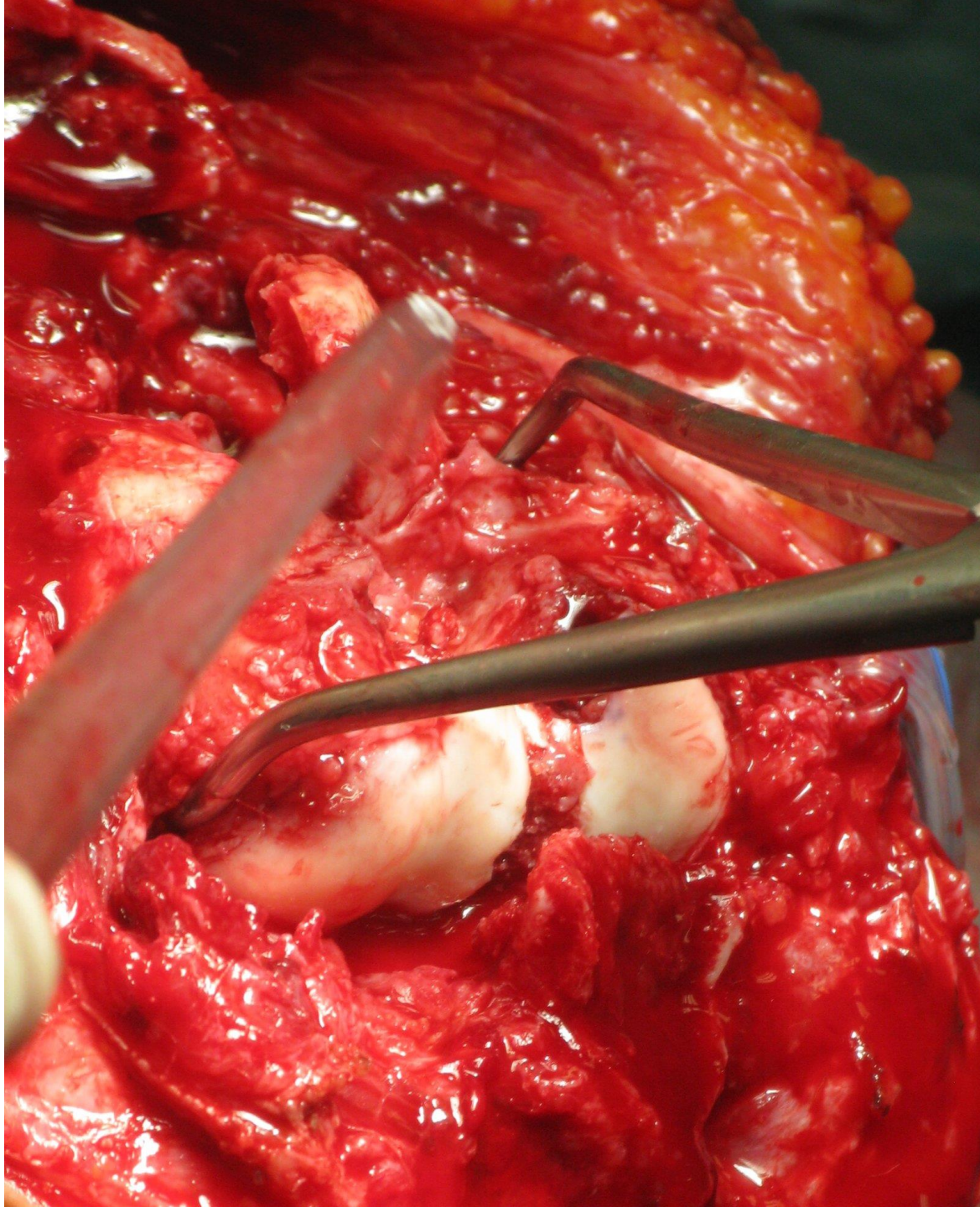


Artrosi anche della
coronoide



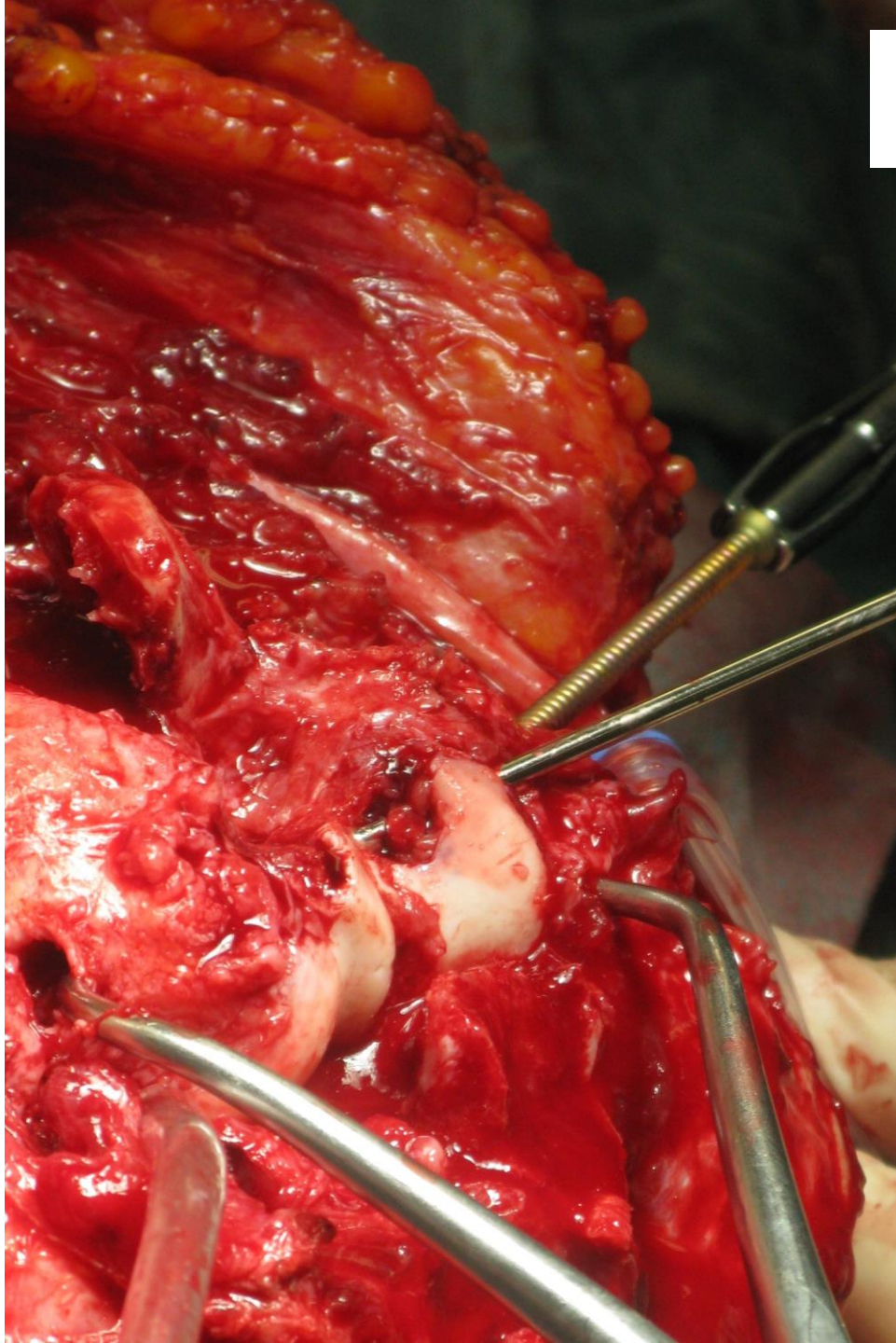


La rima è tra capitulum e troclea con la troclea con perdita di sostanza e scomposta in obliquo ruotata radialmente. X ridurre la superficie articolare bisogna ruotare la troclea ulnarmente .
Rimarrà un gap aumentato che verrà mantenuto con vite di stabilizzazione

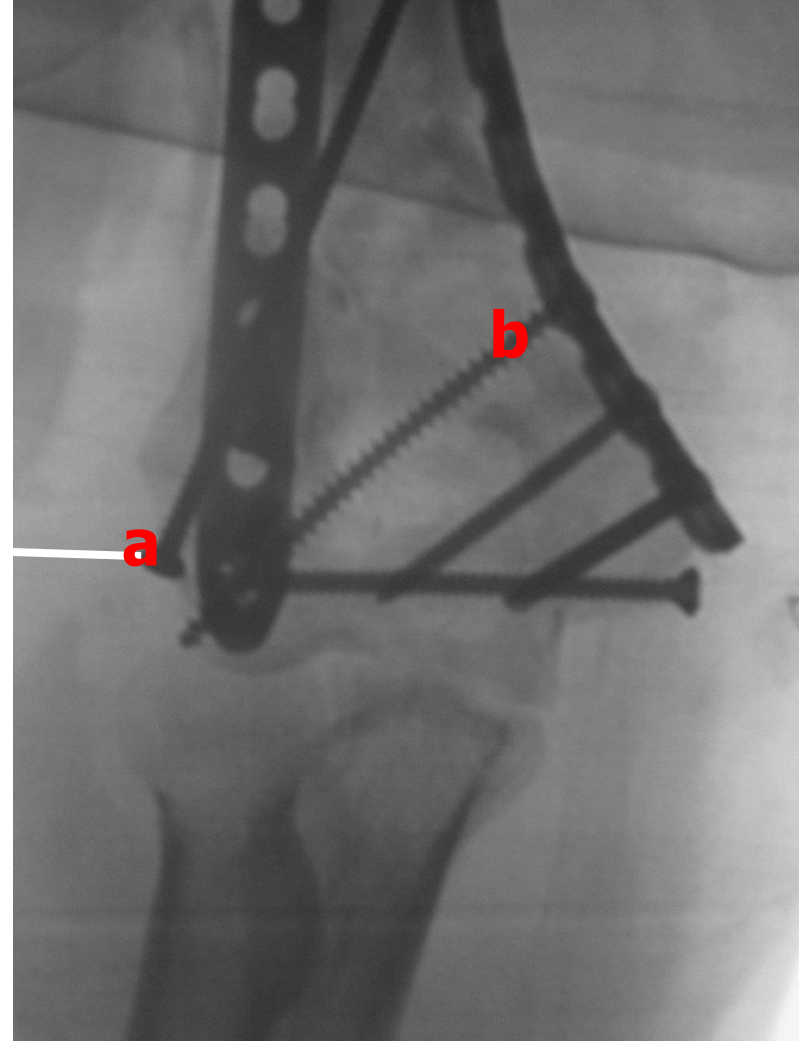
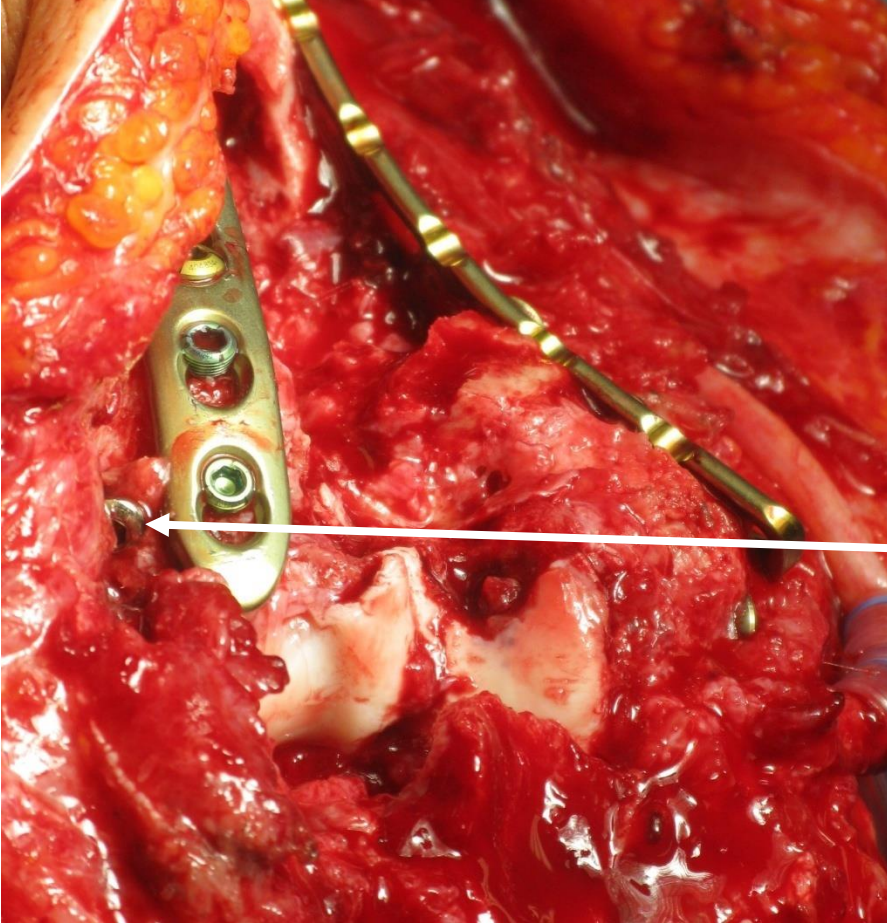


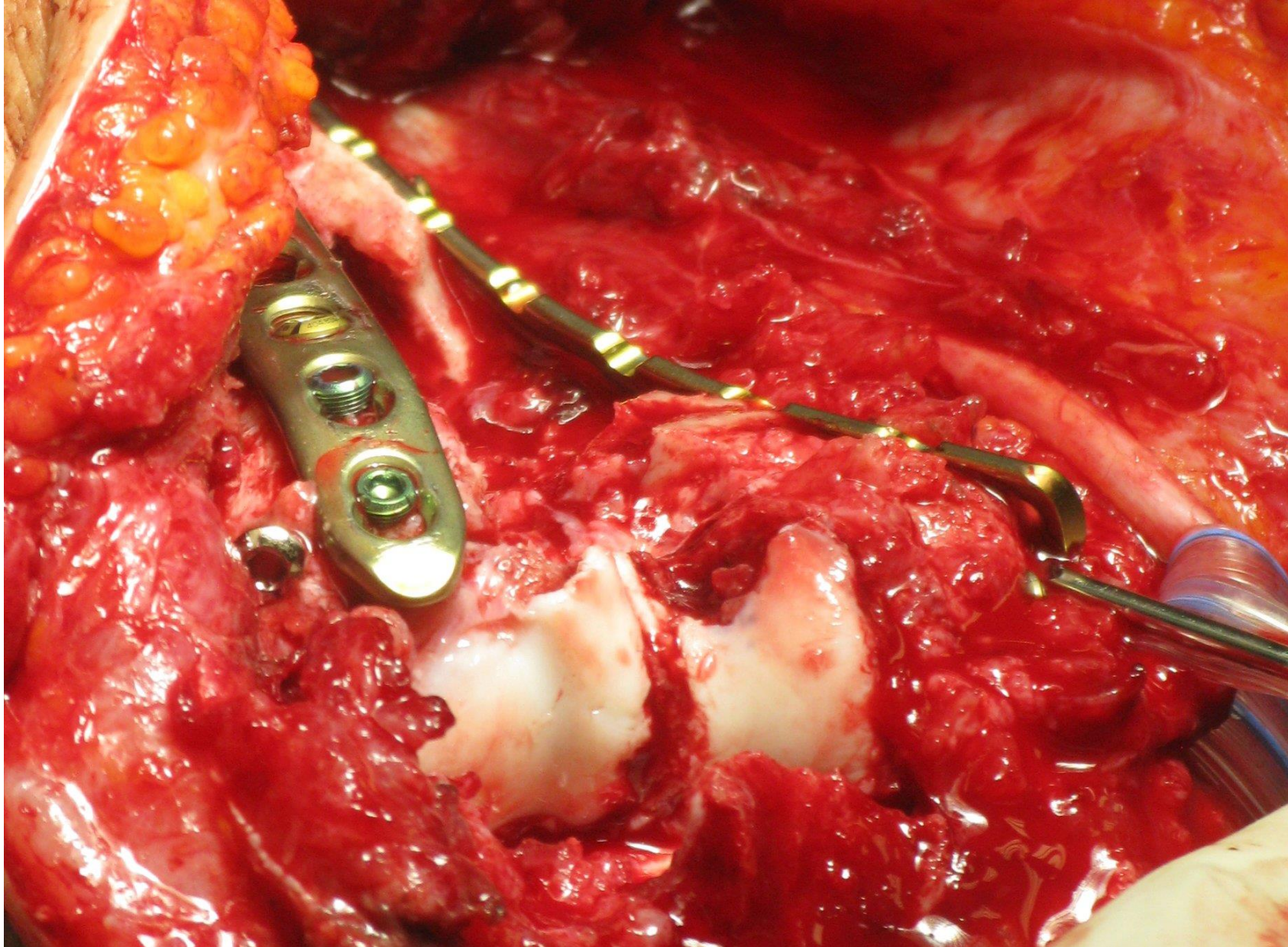
Riduzione della interlinea articolare e si accetta il gap centrale

Kw provvisorio e vite ulnoradiale di stabilizzazione

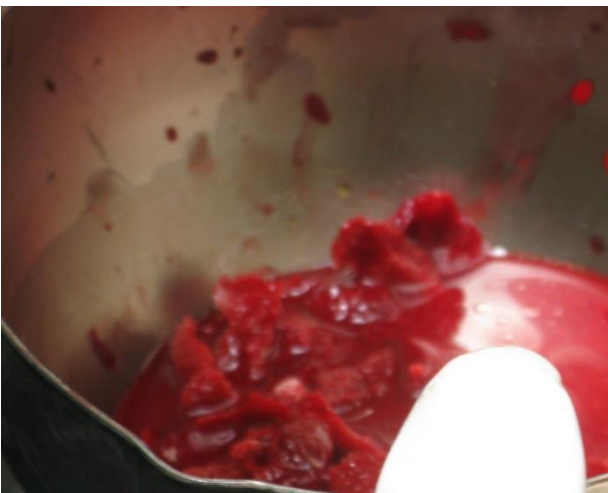

Il collegamento tra le 2 colonne è difficile perché limitato dalla grandezza dei frammenti e dalla direzione dei fori. Si aggiunge una vite lunga a collegare le 2 colonne – il collegamento ora è fatto da 2 viti (a e b)

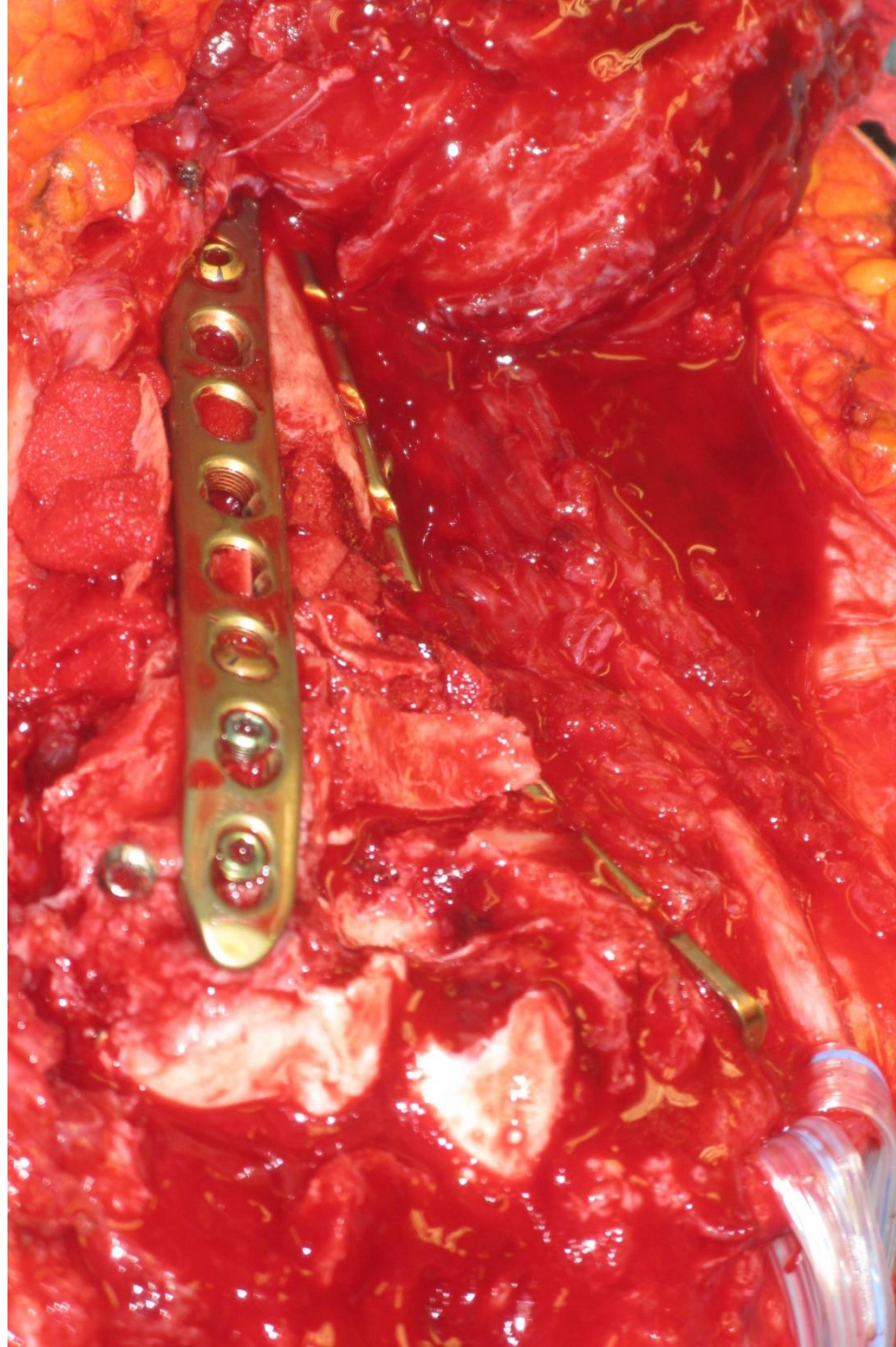


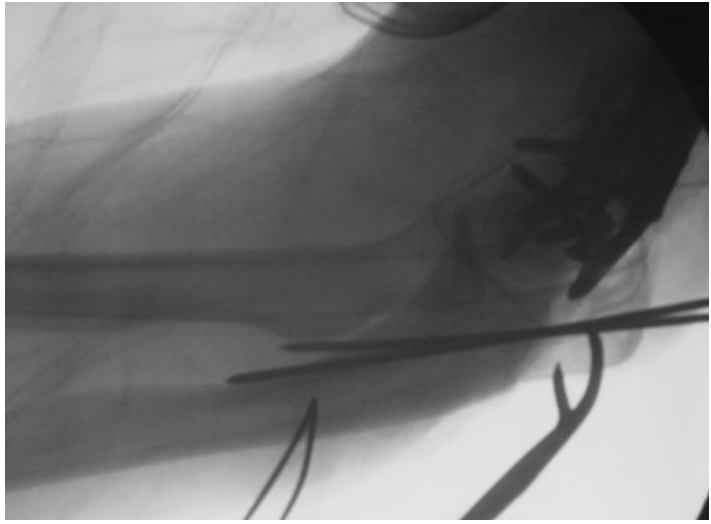
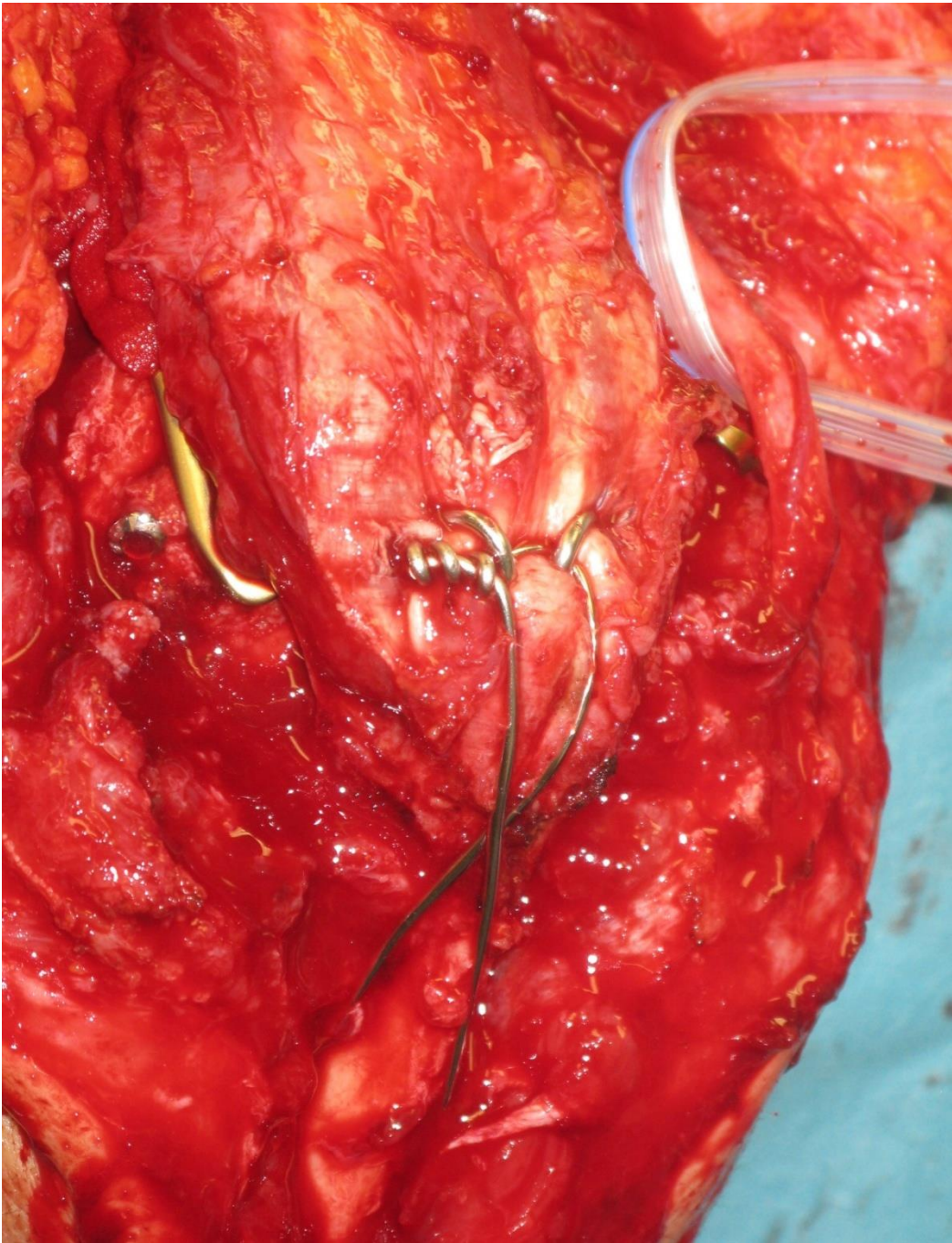


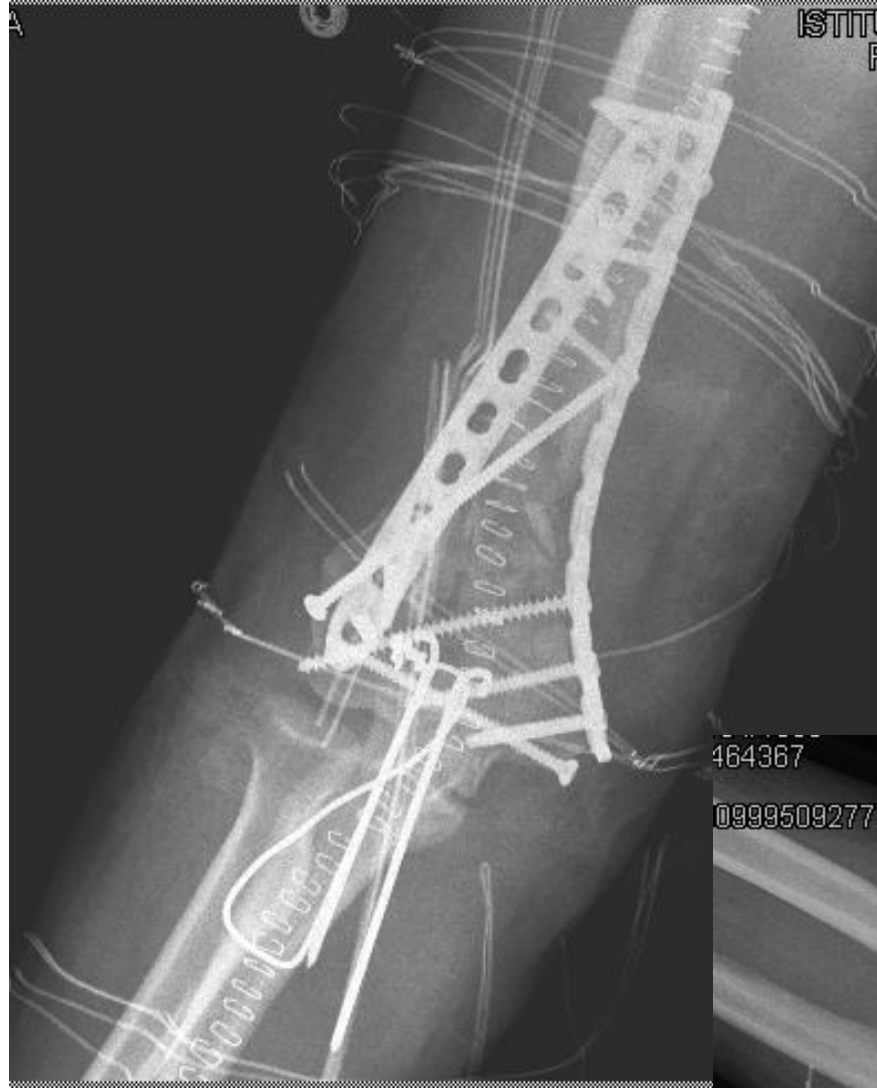Il gap



Innesti dalla cresta post

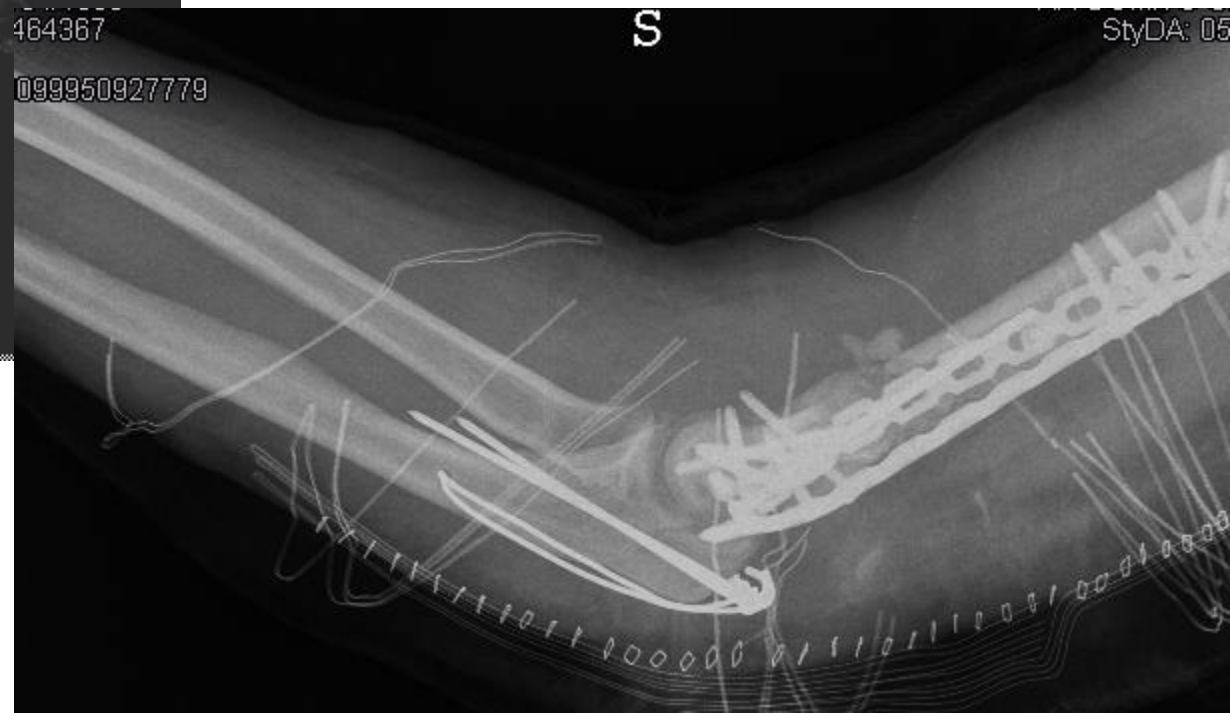





464367

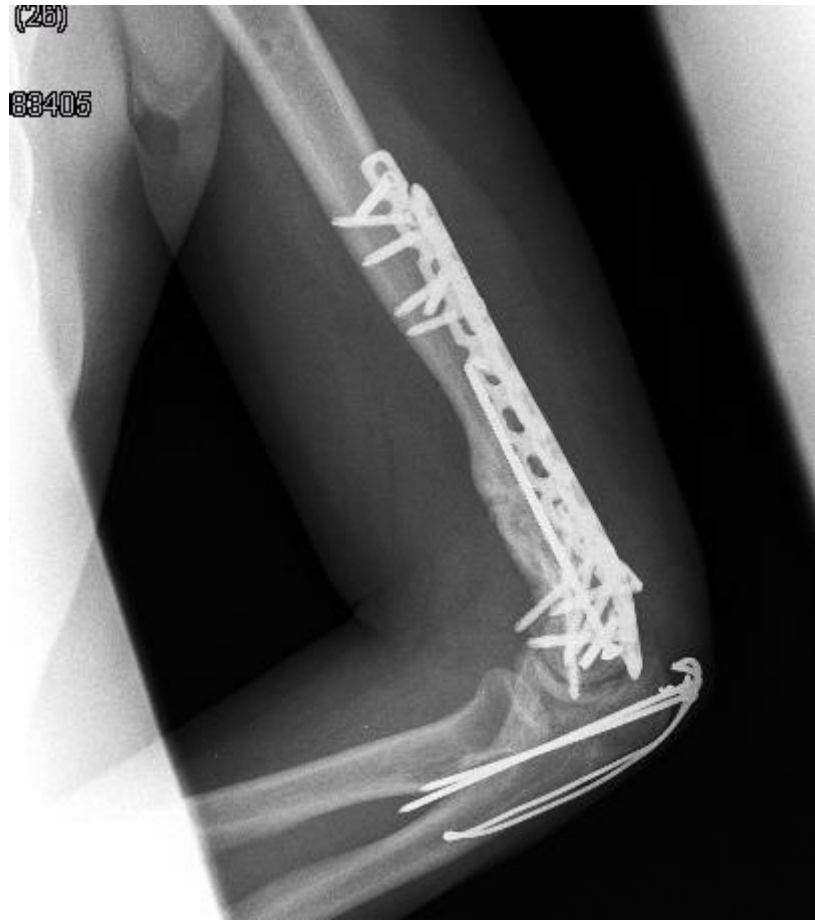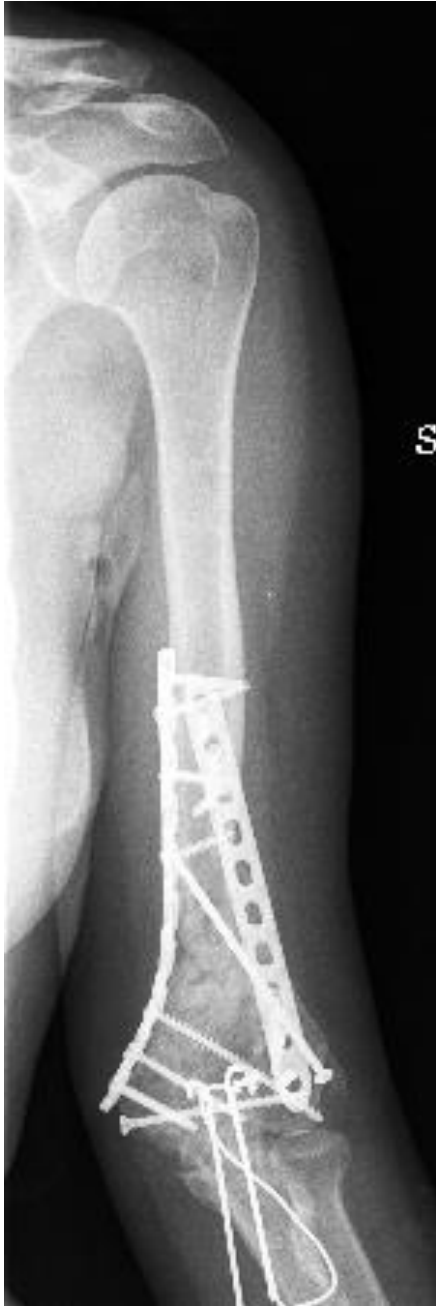099950927779



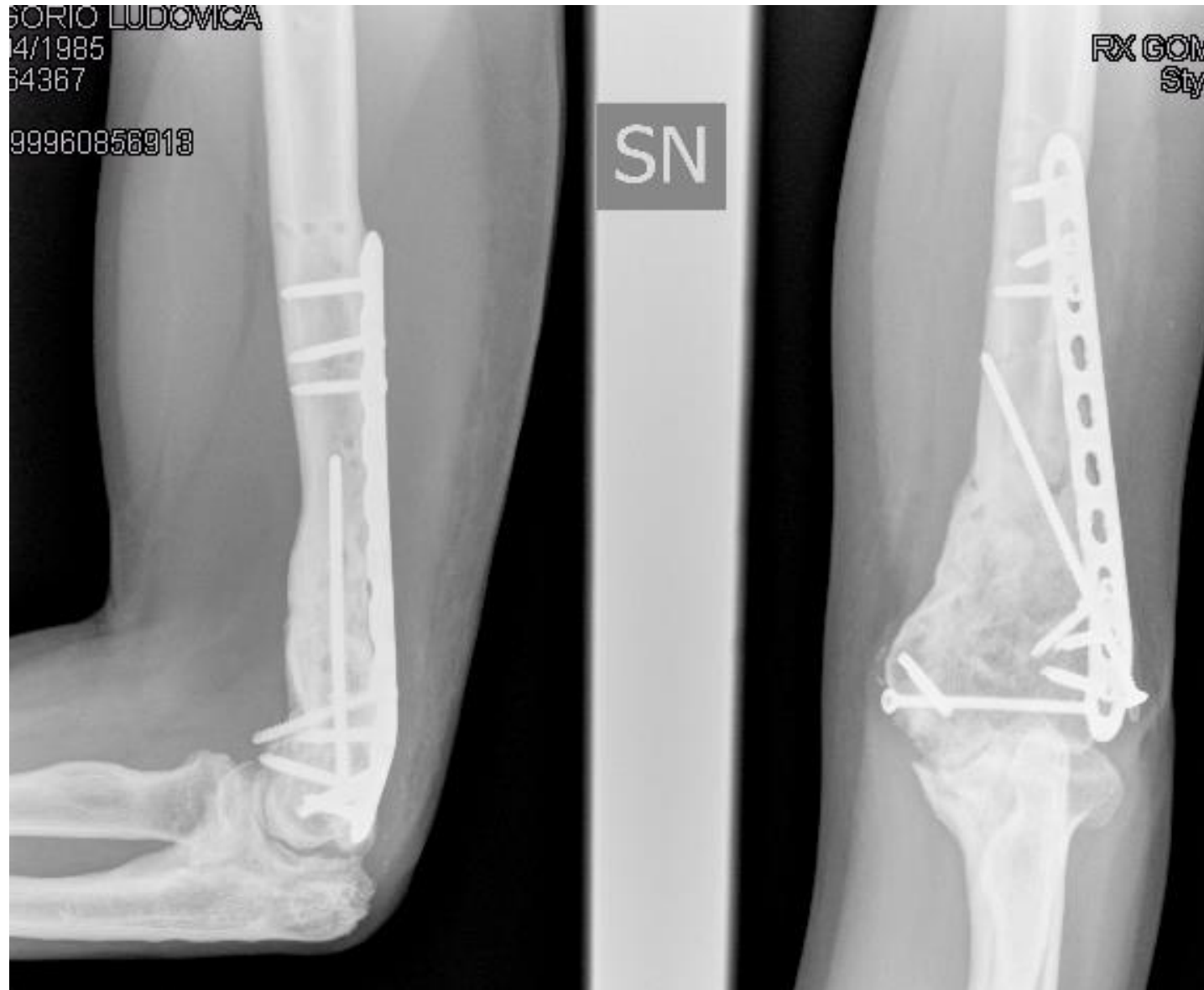S

StyDA: 05

Sep 6 months



A 3 anni



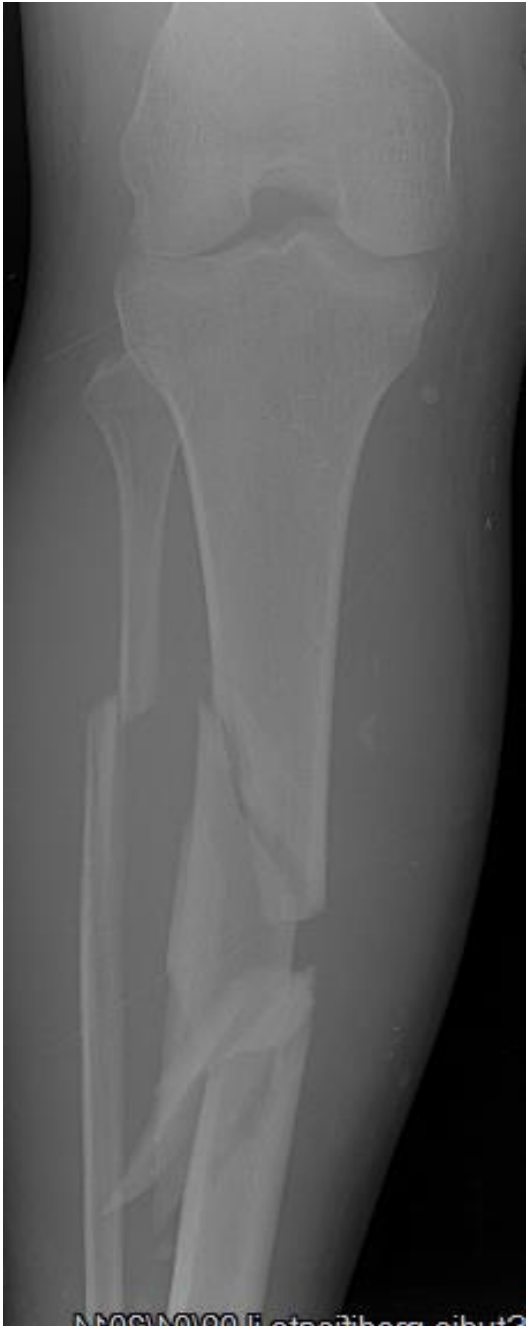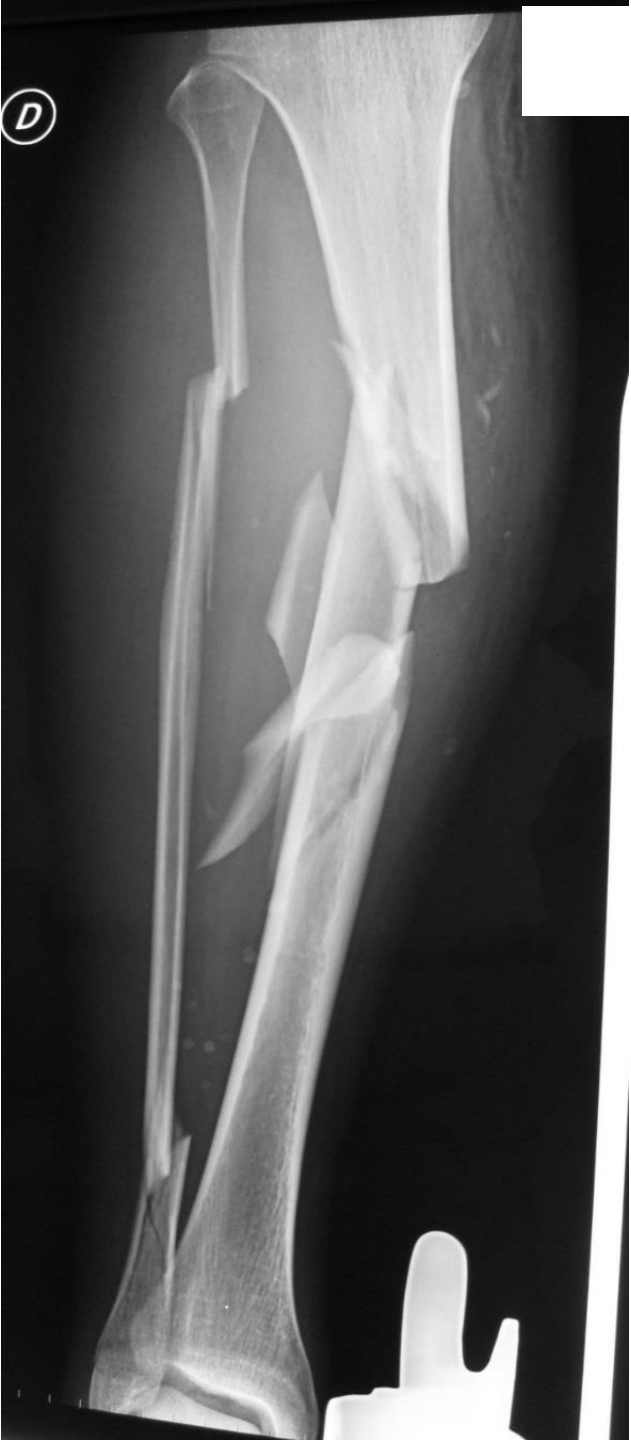Il fissatore NON fa guarire i gaps

La riduzione è piu' importante della fissazione

Timing

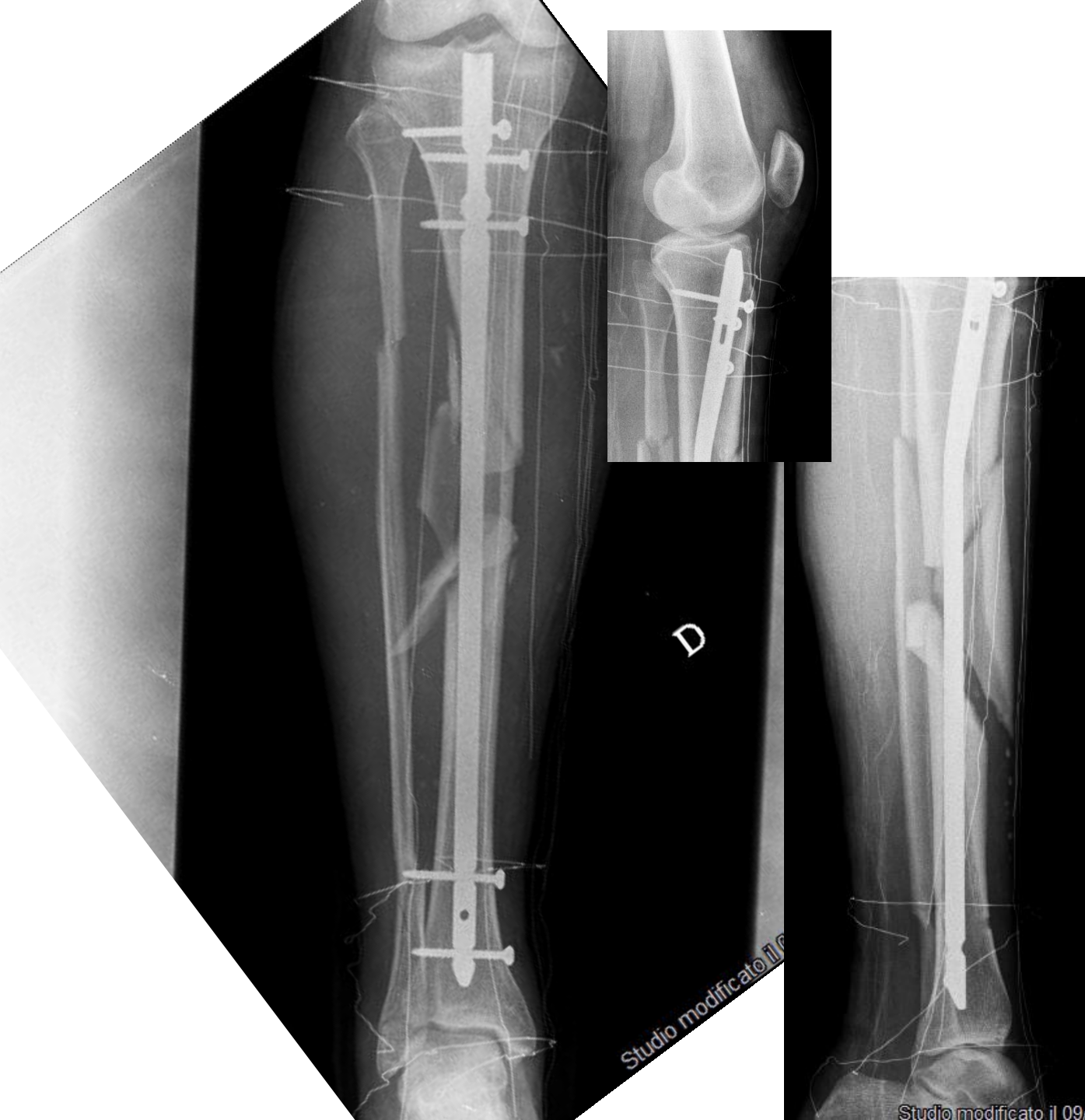
AO

47 anni Gustilo 1



to il 09/04/2014

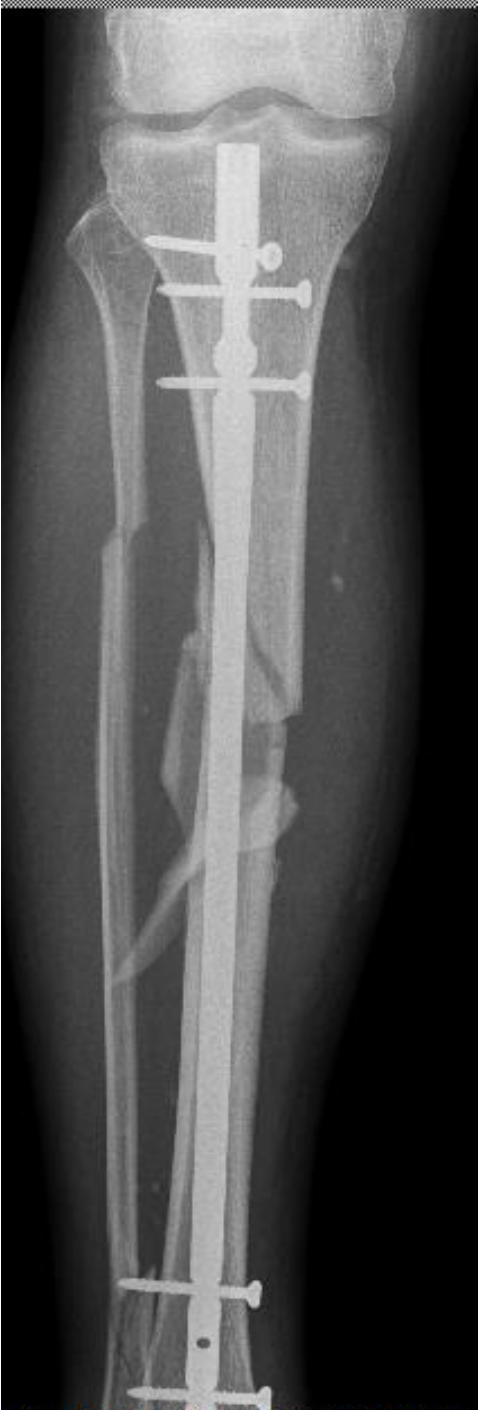AO



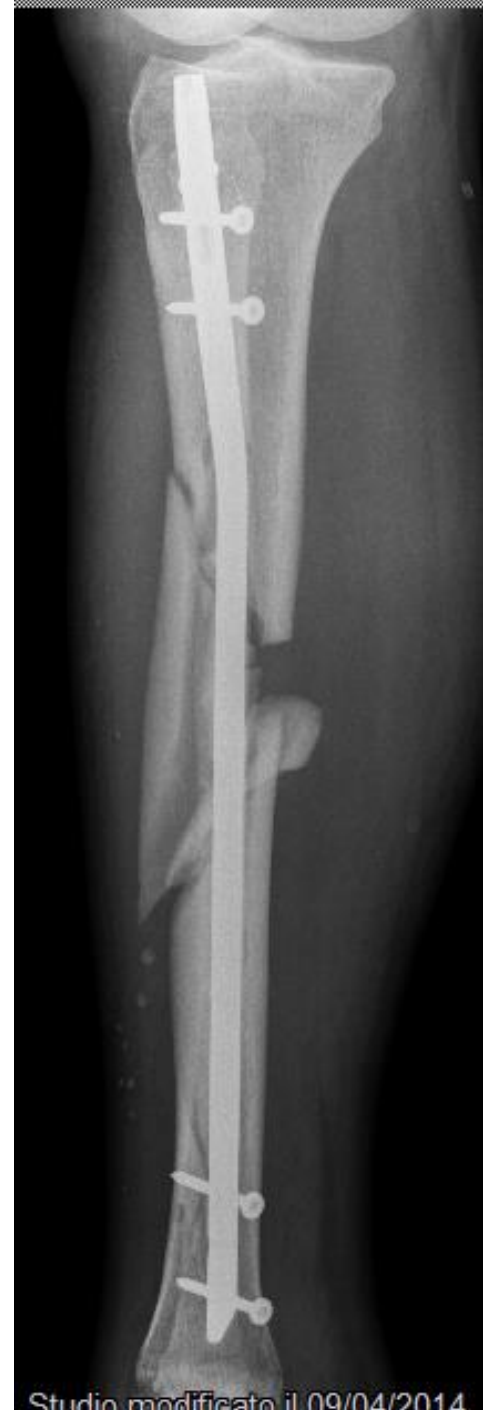UTN

Problemi

1. **VARO PROSSIMALE**
2. **GAP**
3. **CHIDO SOTTODIMENSIONATO** (era il chiodo pieno non alesato delle esposte)

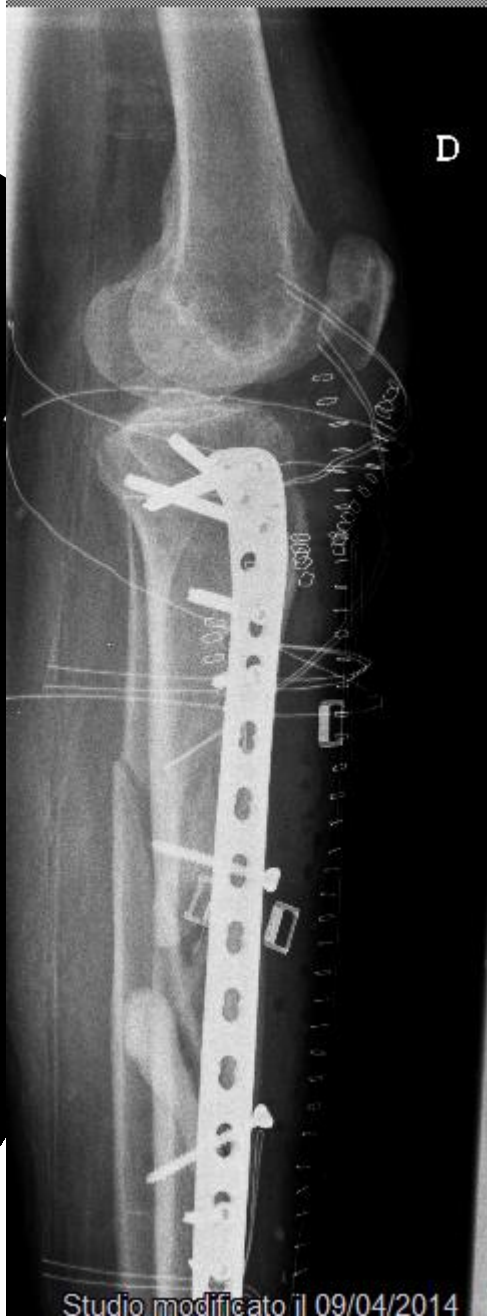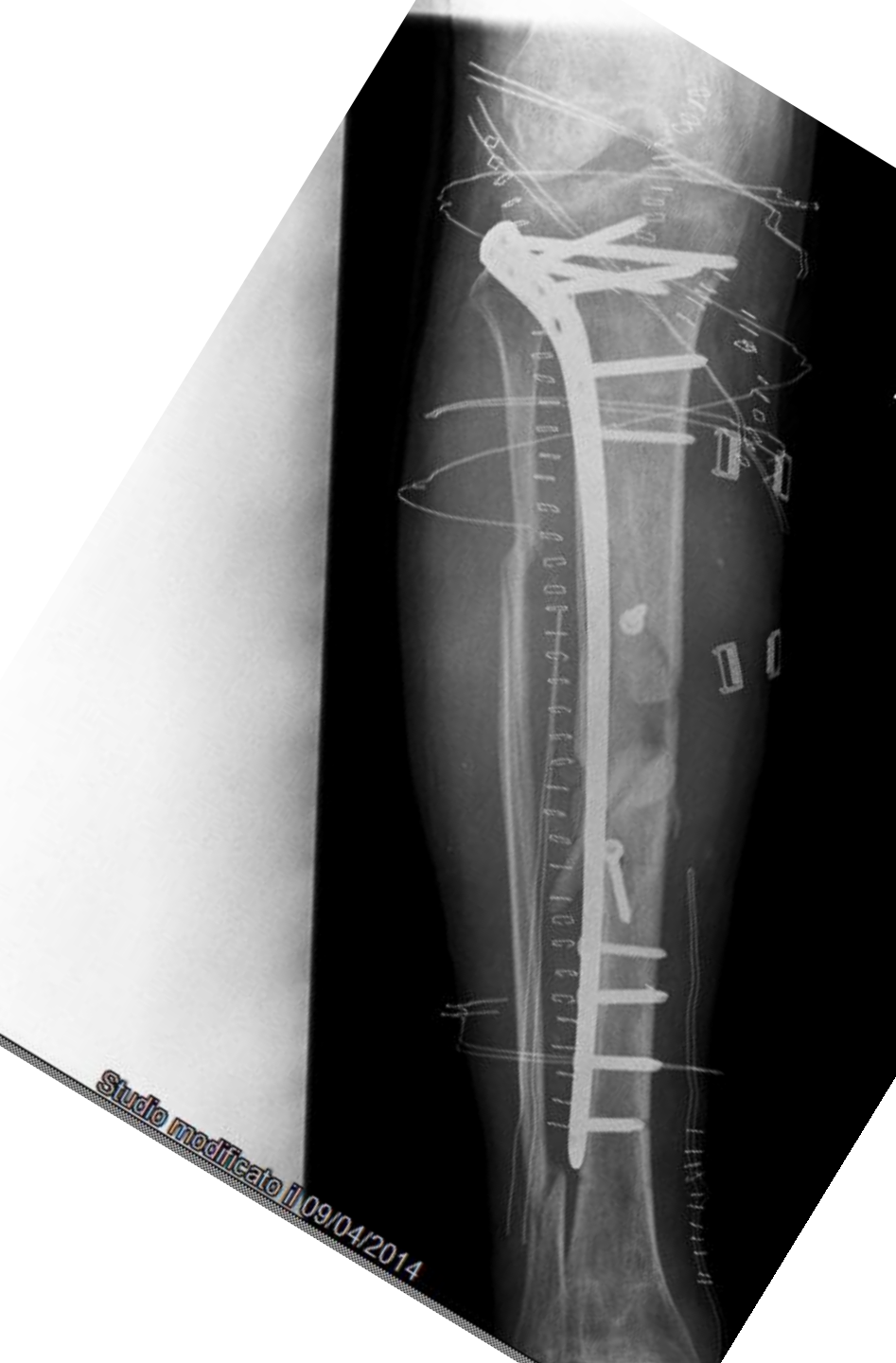


Studio modificato il 09/04/2014

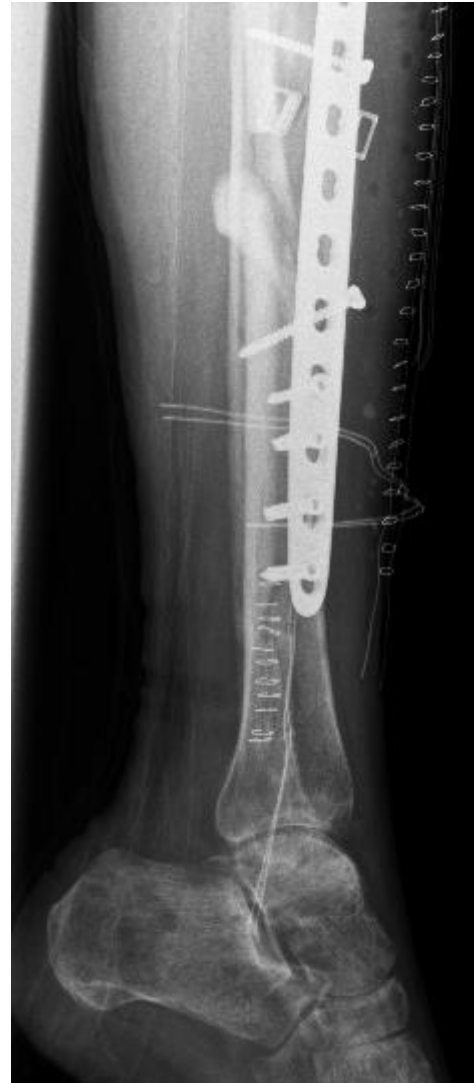

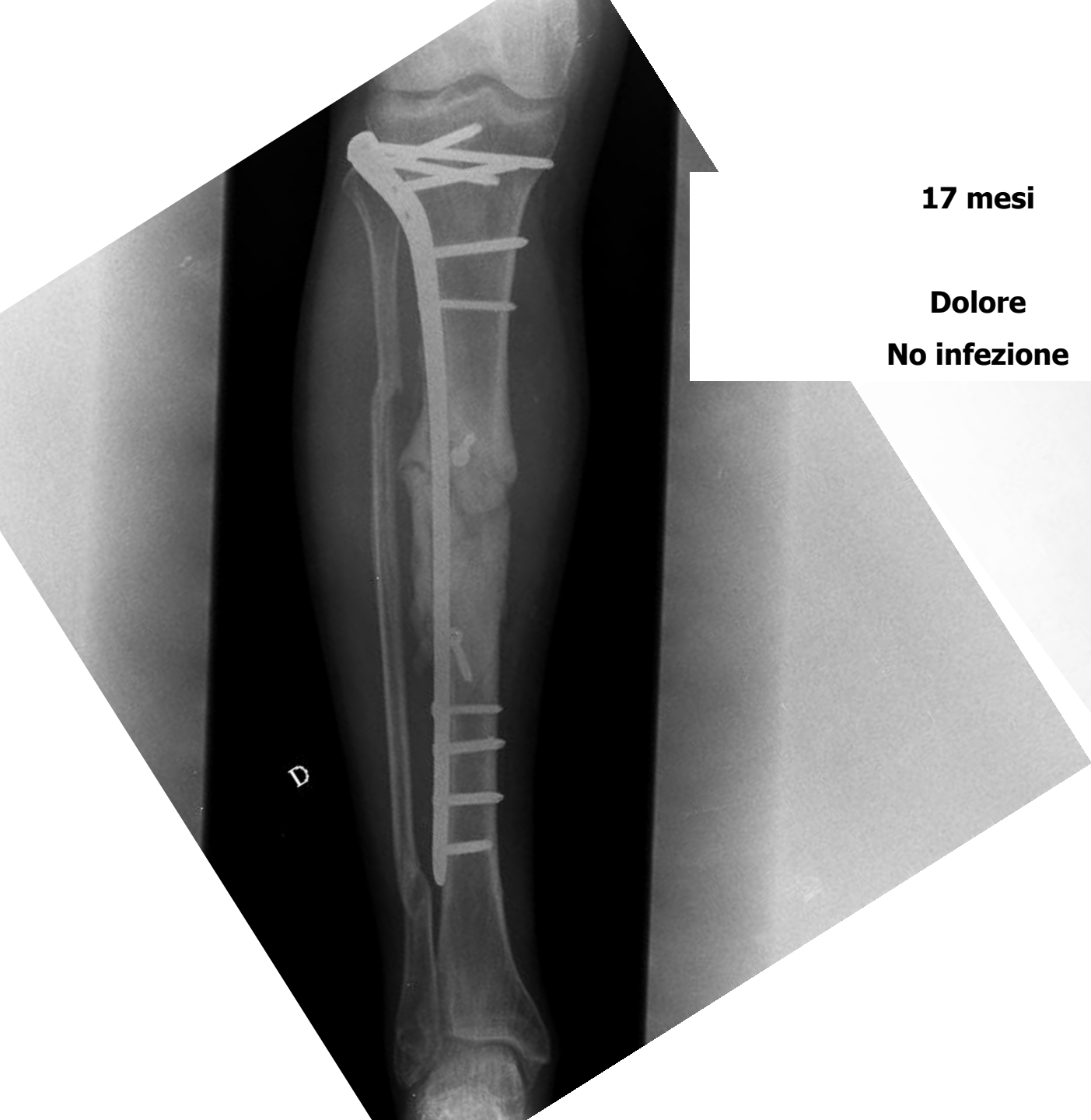Studio modificato il 09/04/2014

pseudartrosi



6 mesi
Revisione + innesto da cresta

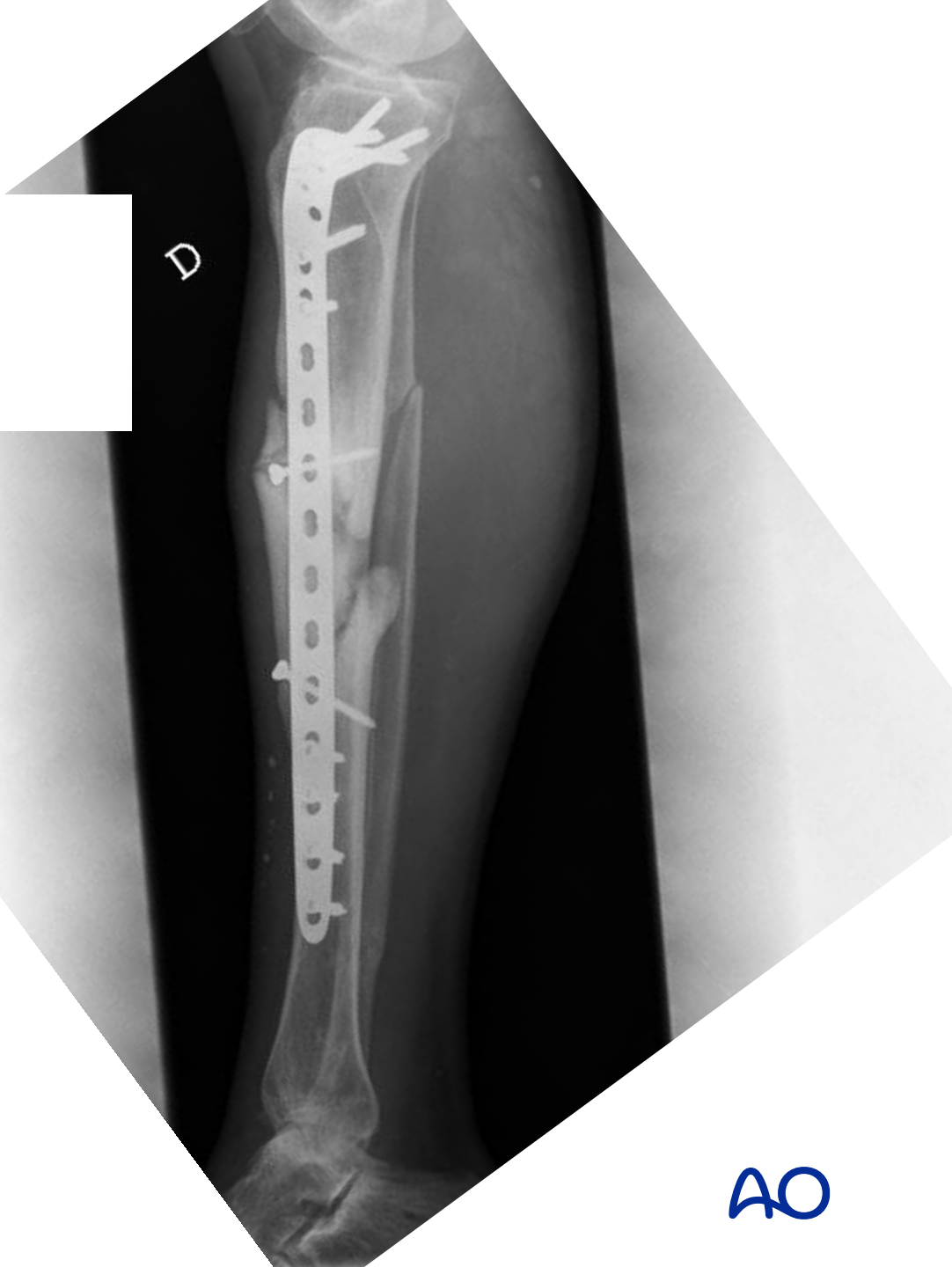


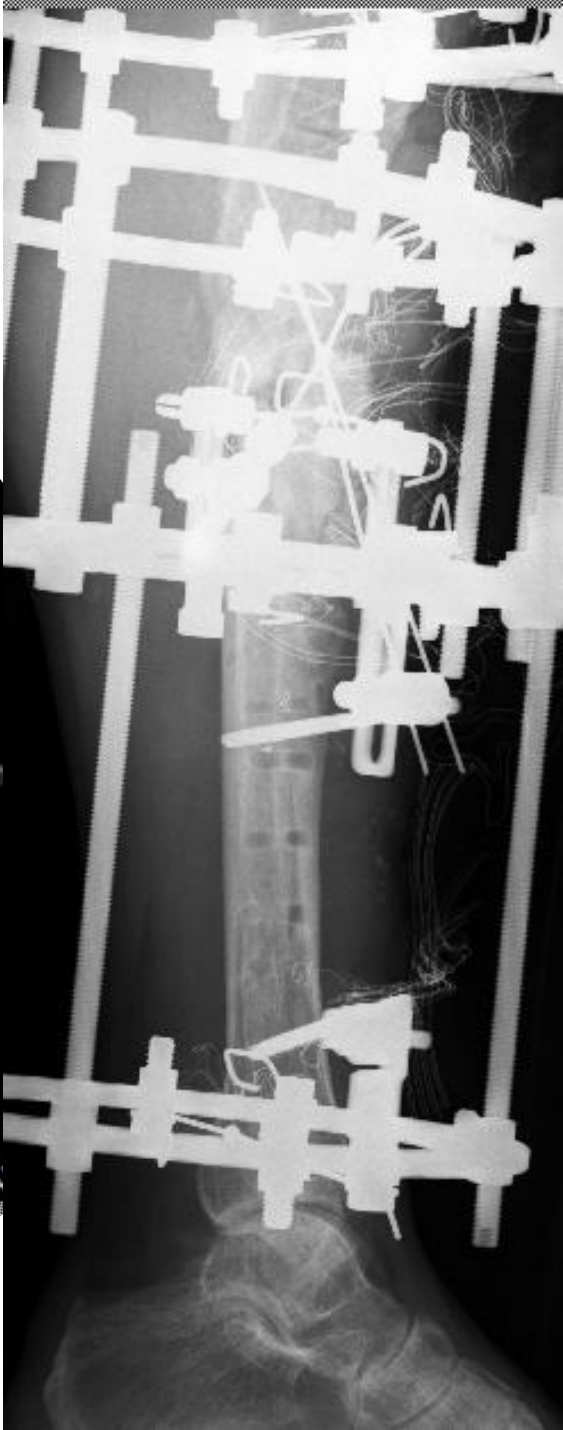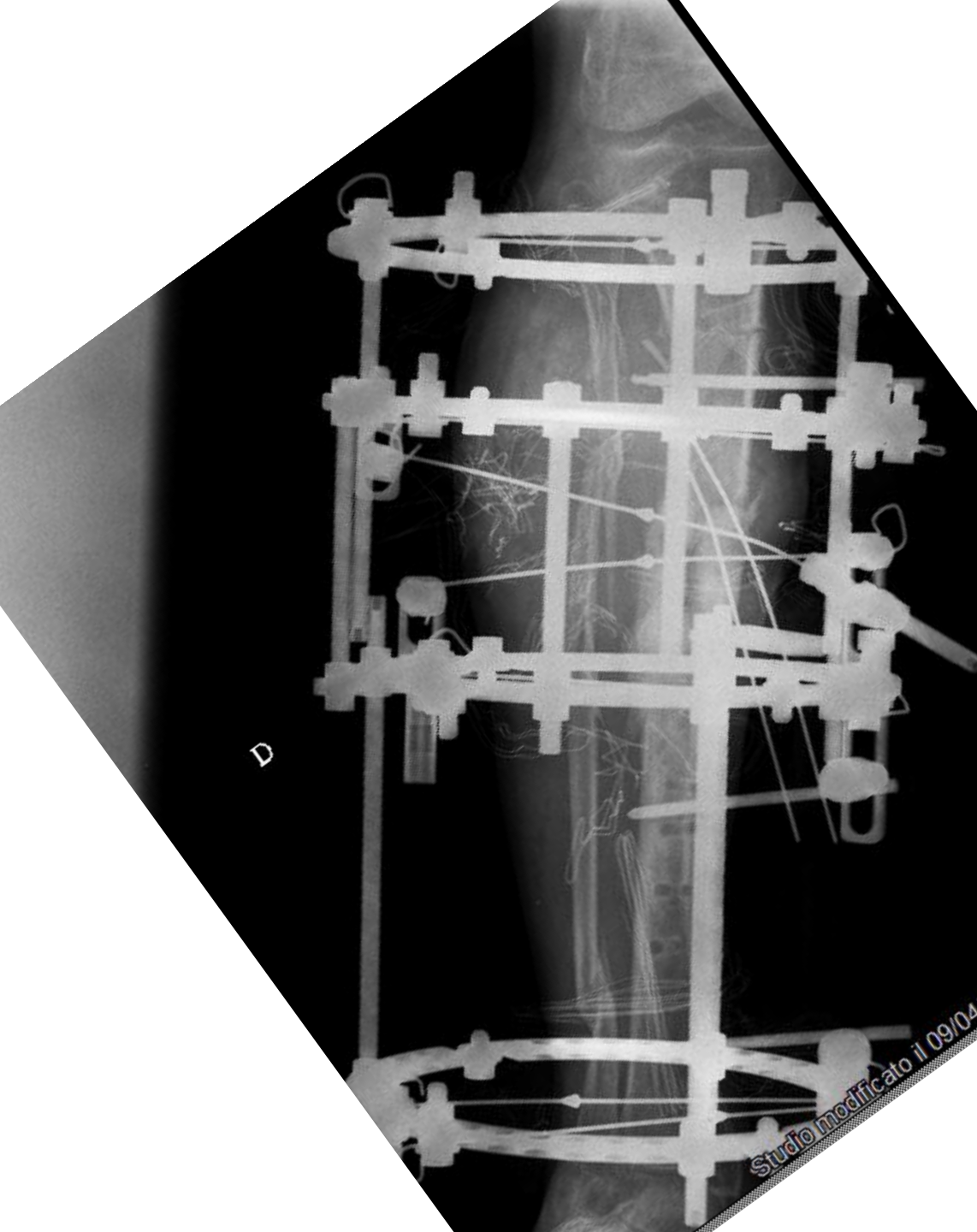


17 mesi


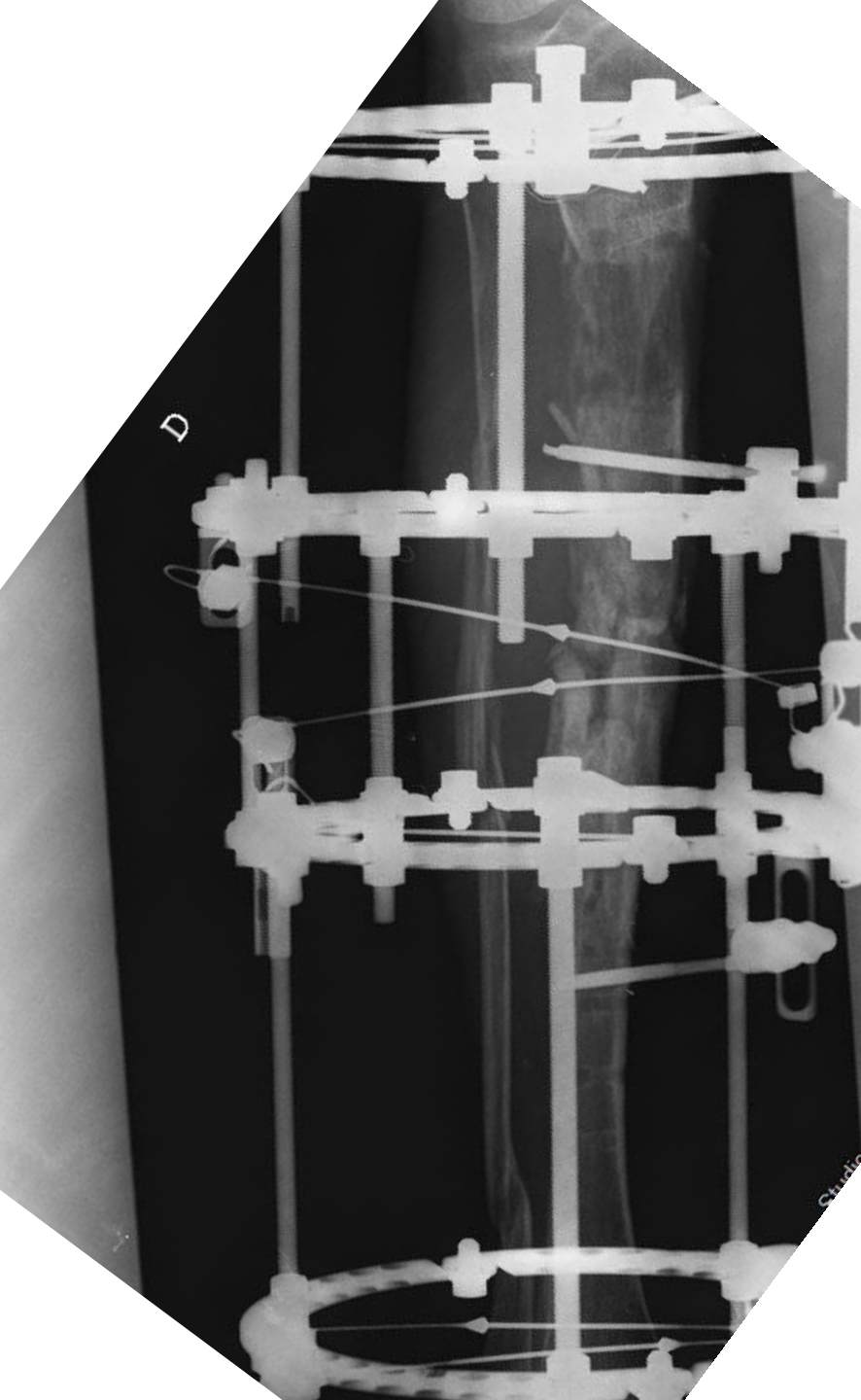
Dolore

No infezione

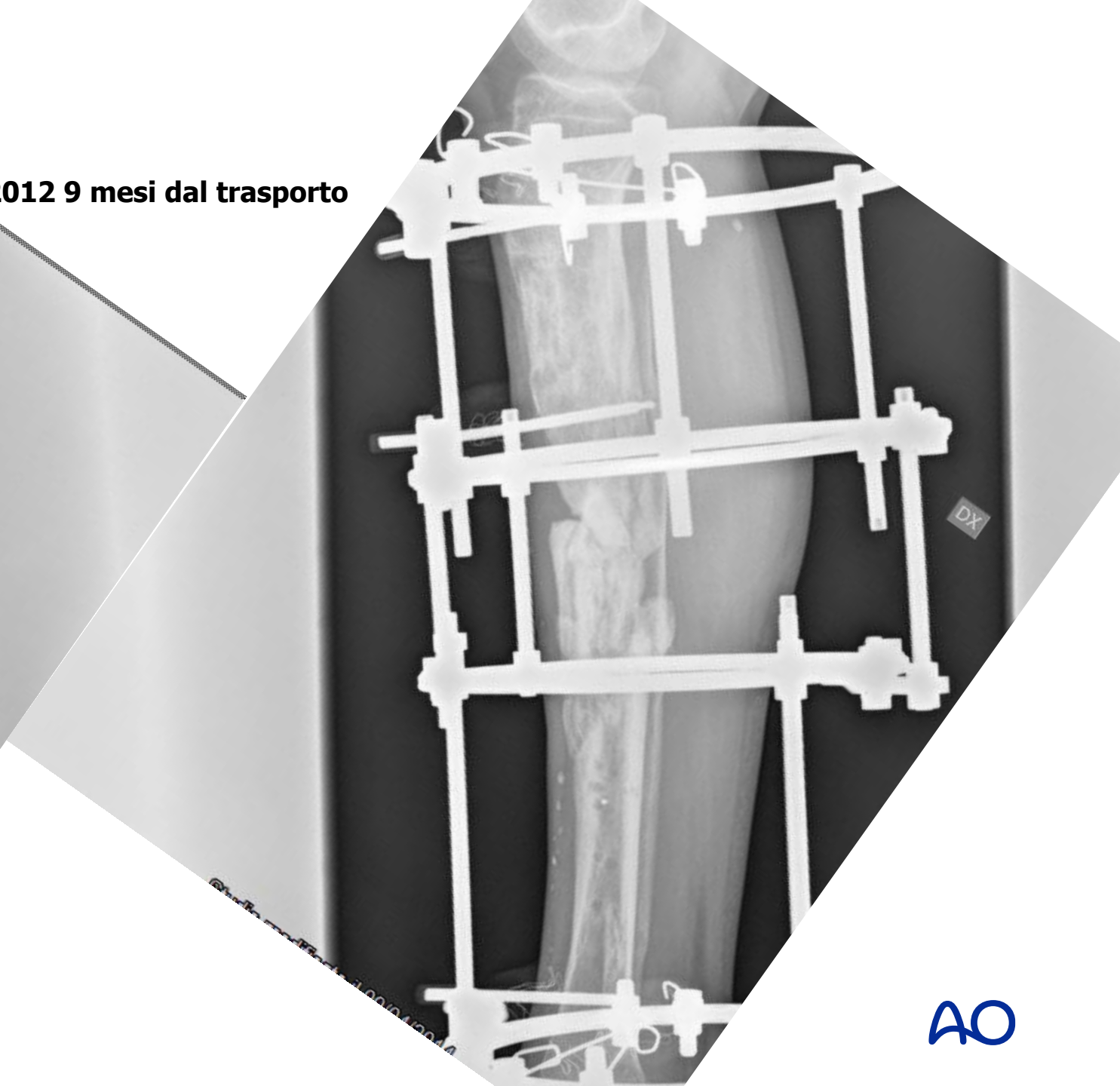
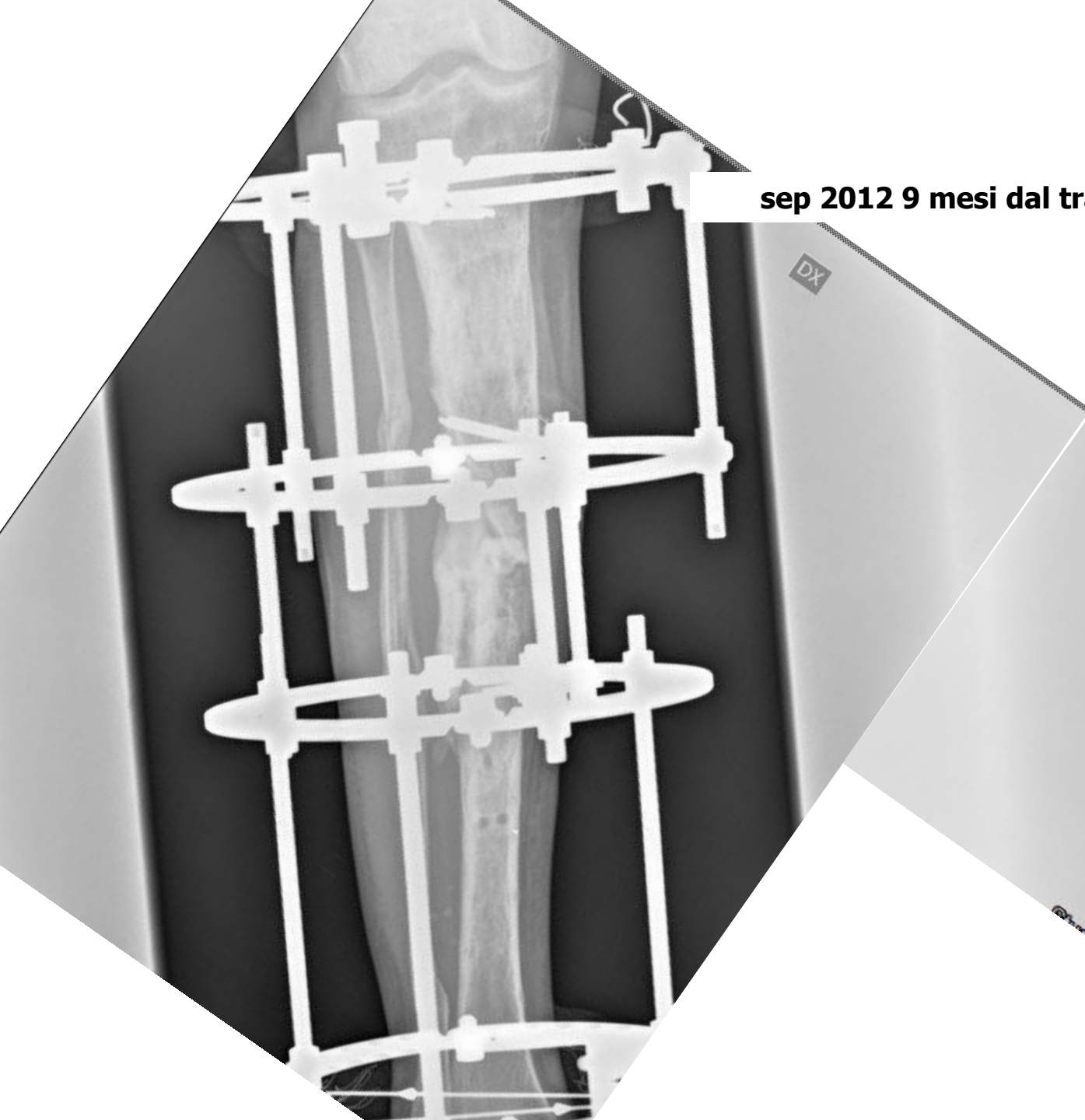




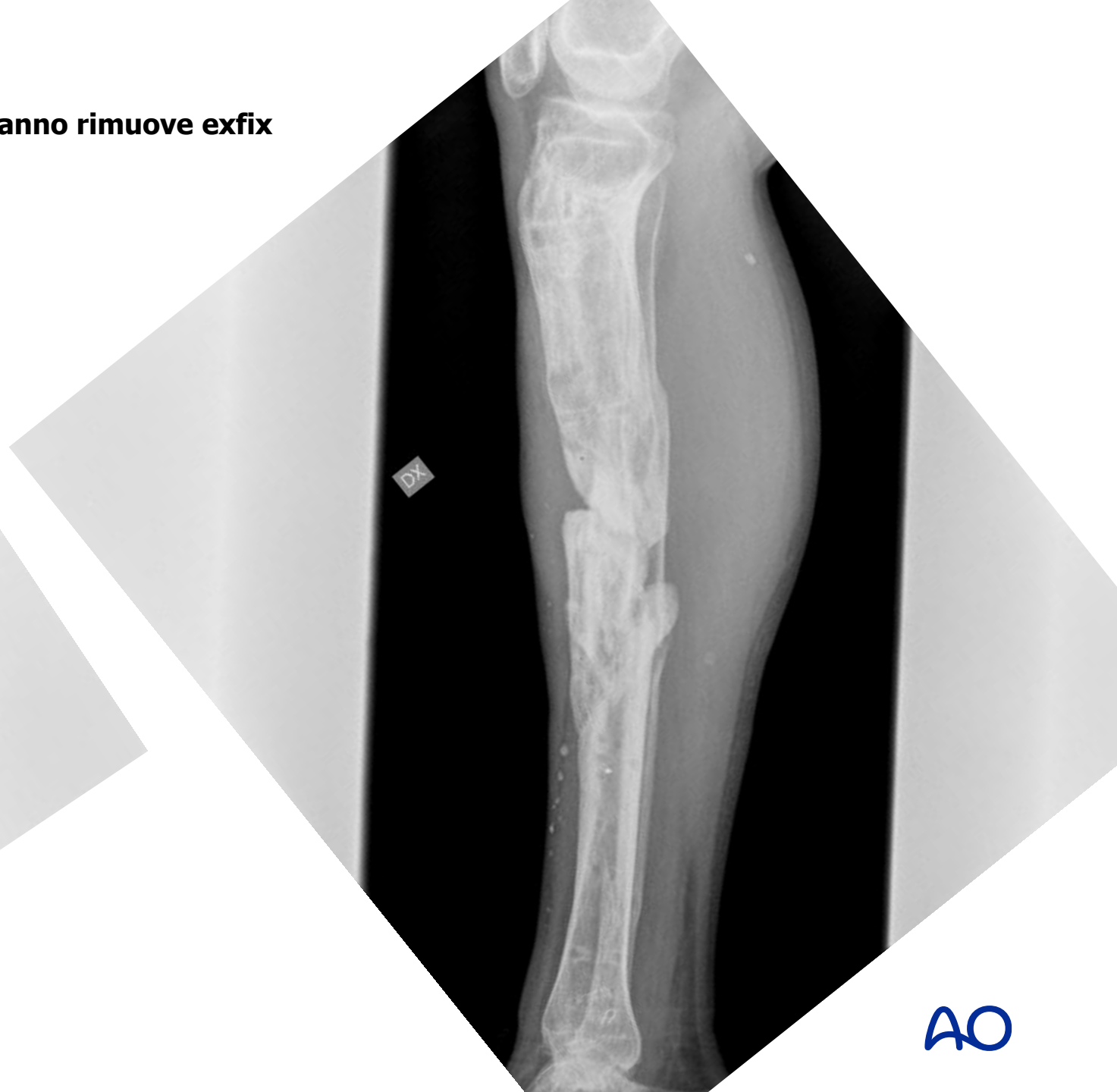
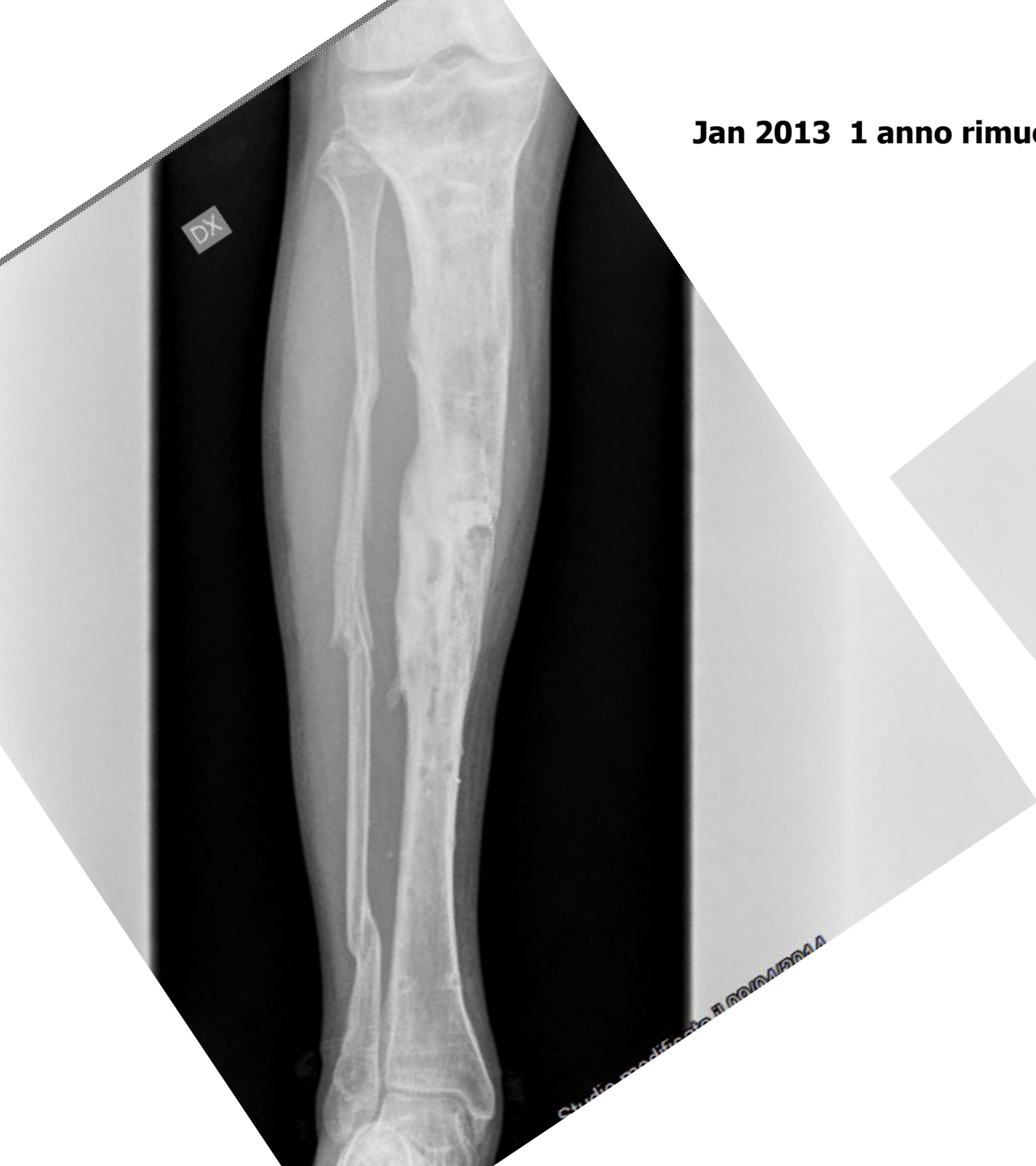
Jan 2012 3 mesi dal trasporto



sep 2012 9 mesi dal trasporto

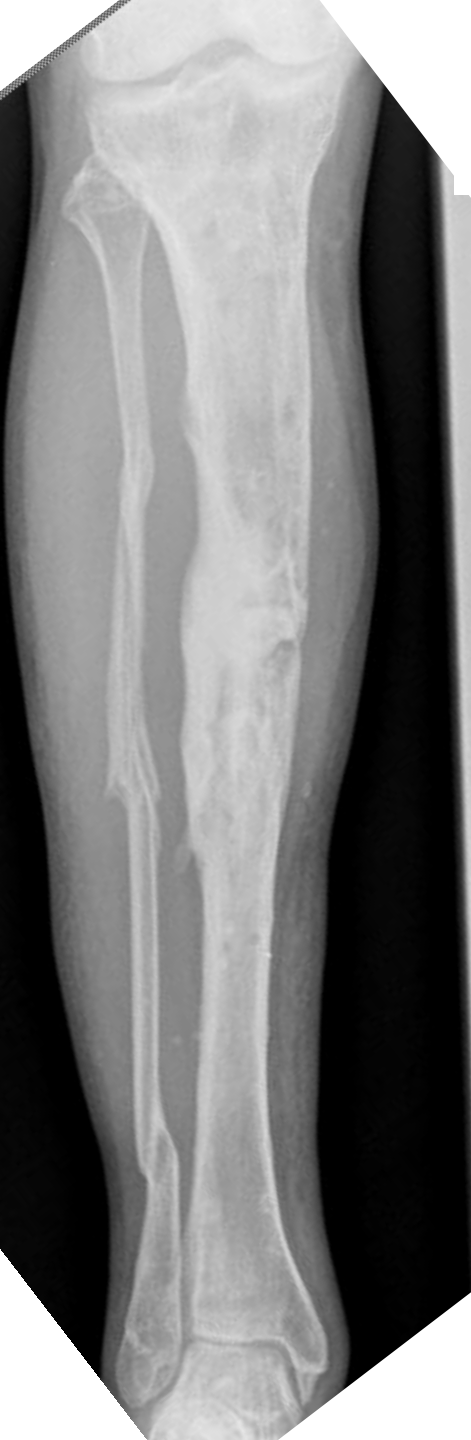

Jan 2013 1 anno rimuove exfix

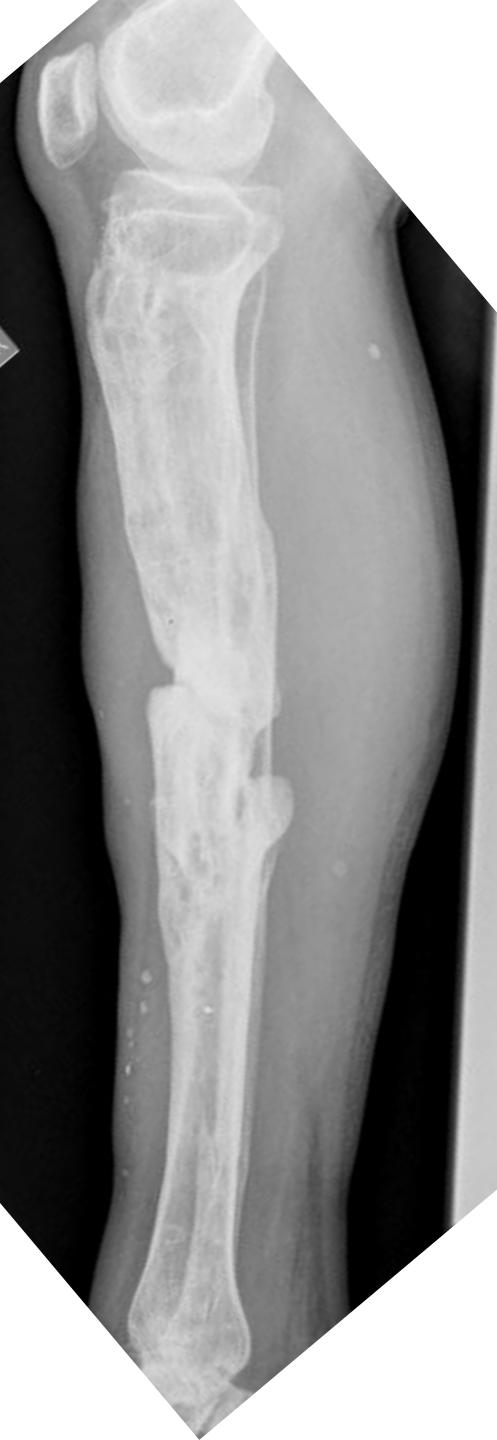

A 20 mesi instabilità soggettiva

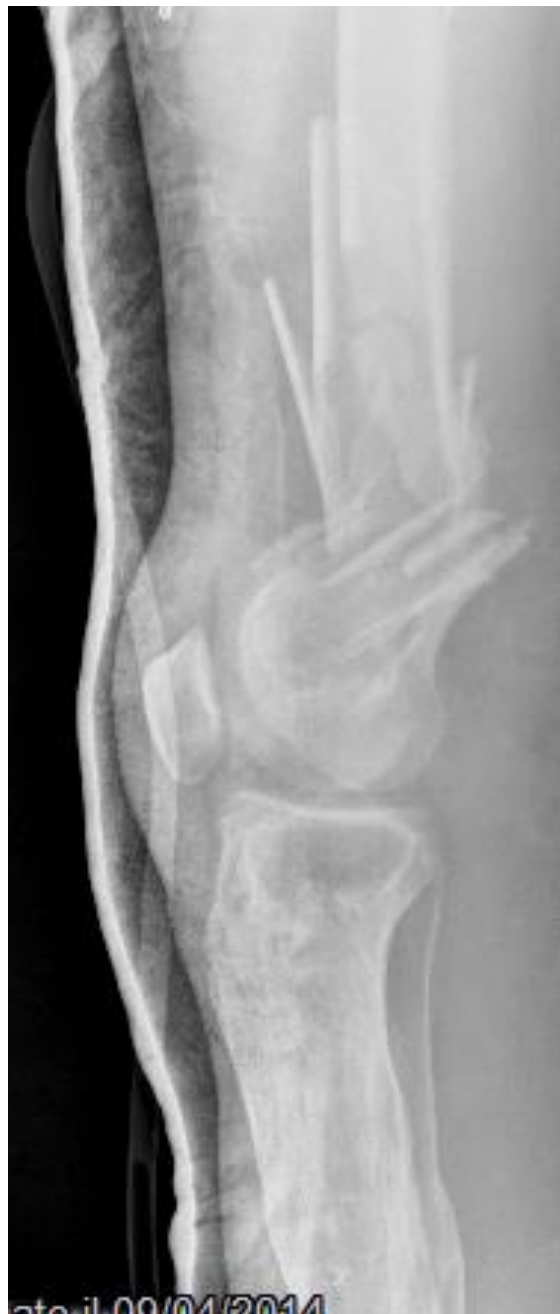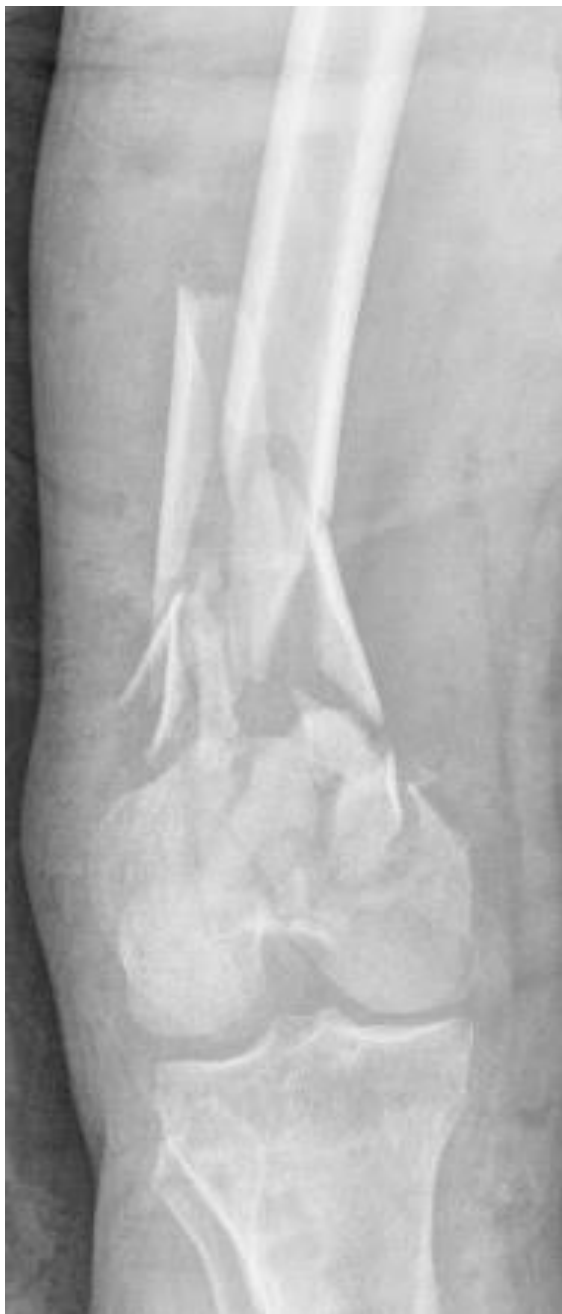Dx

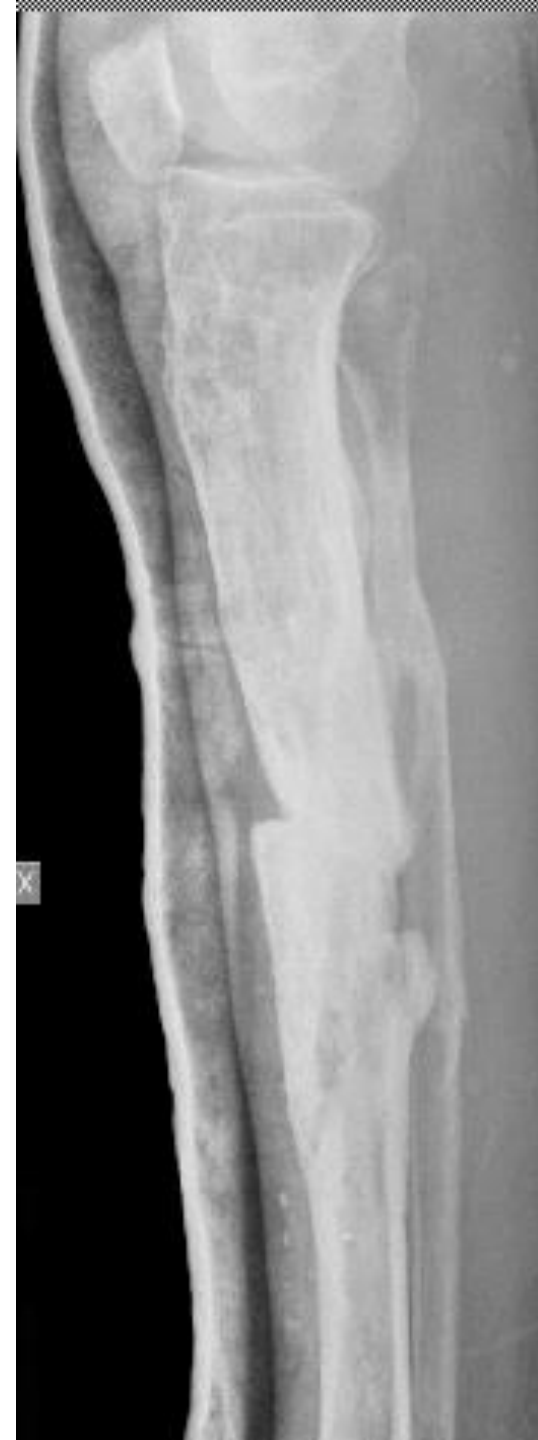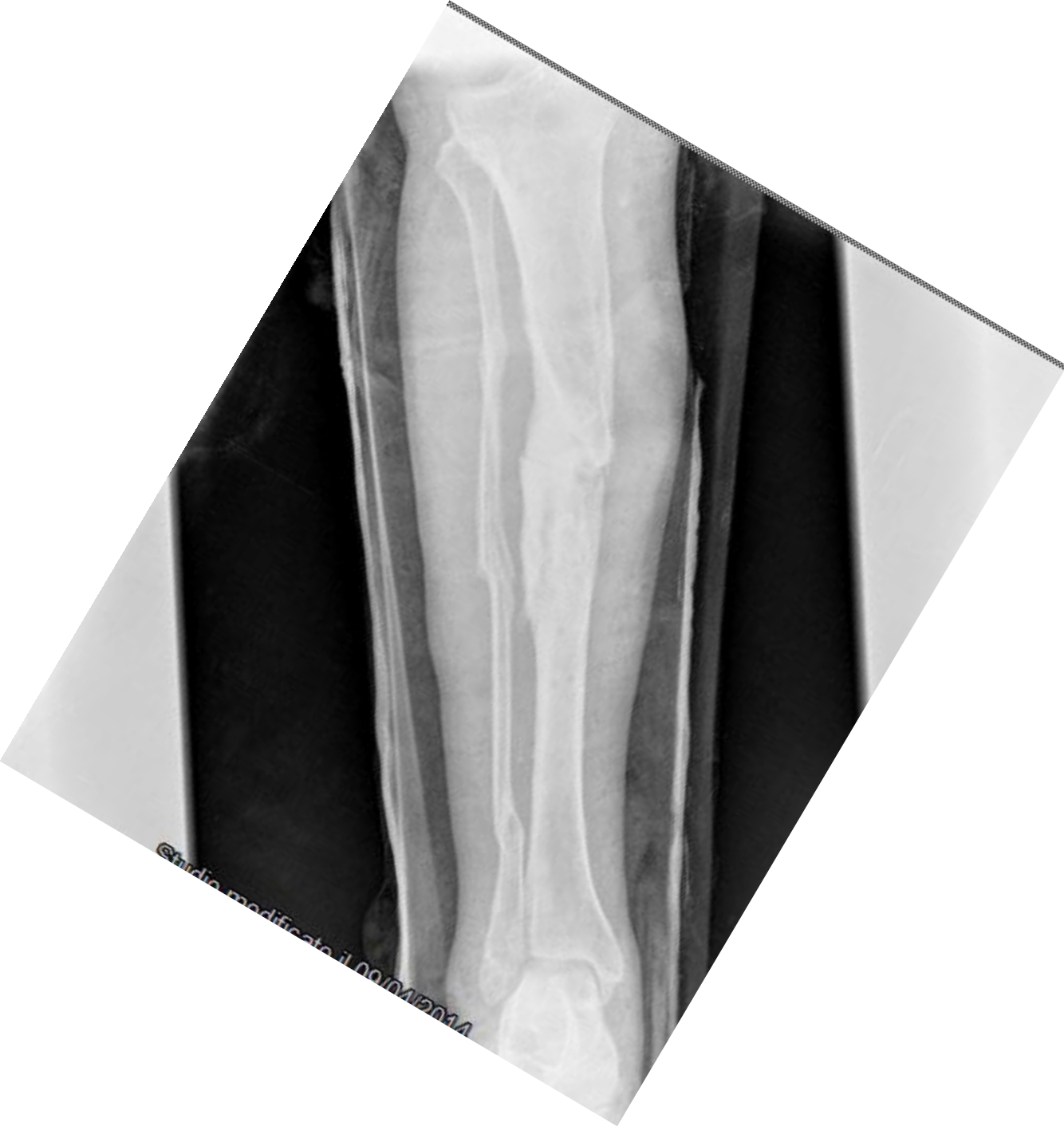


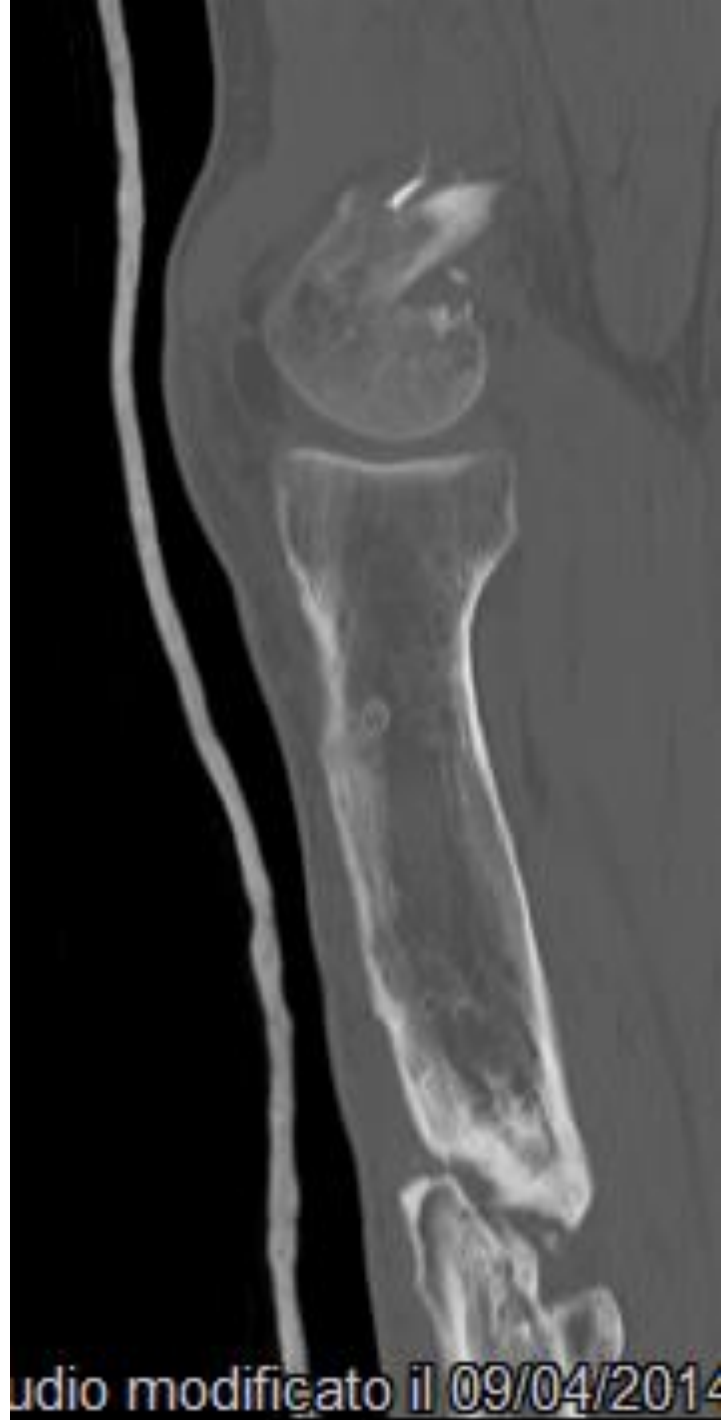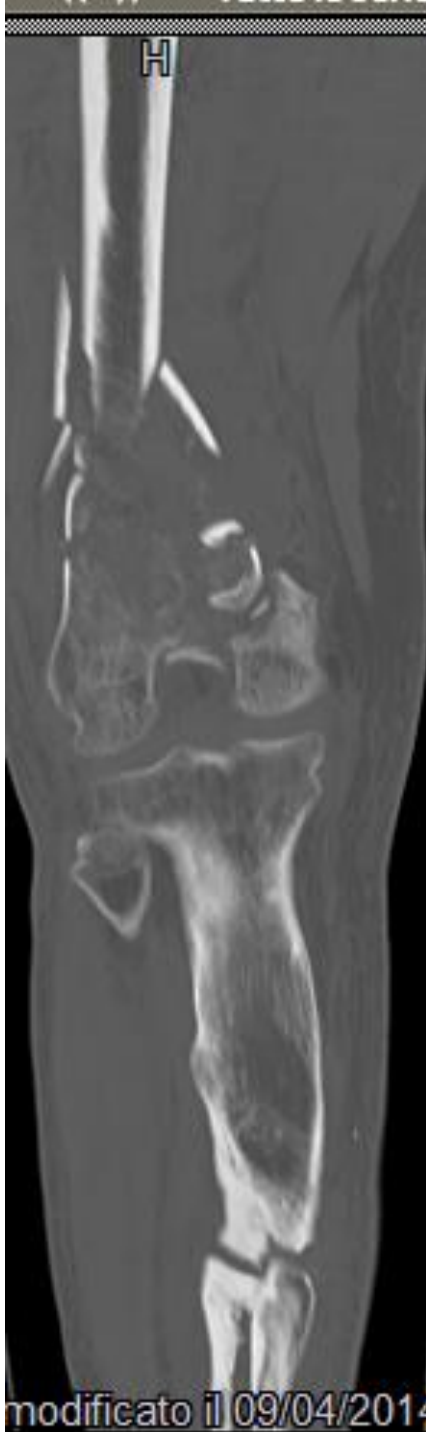Dx



2014 nuovo incidente fr chiusa femore distale viene trasportato con emistivalone gessato

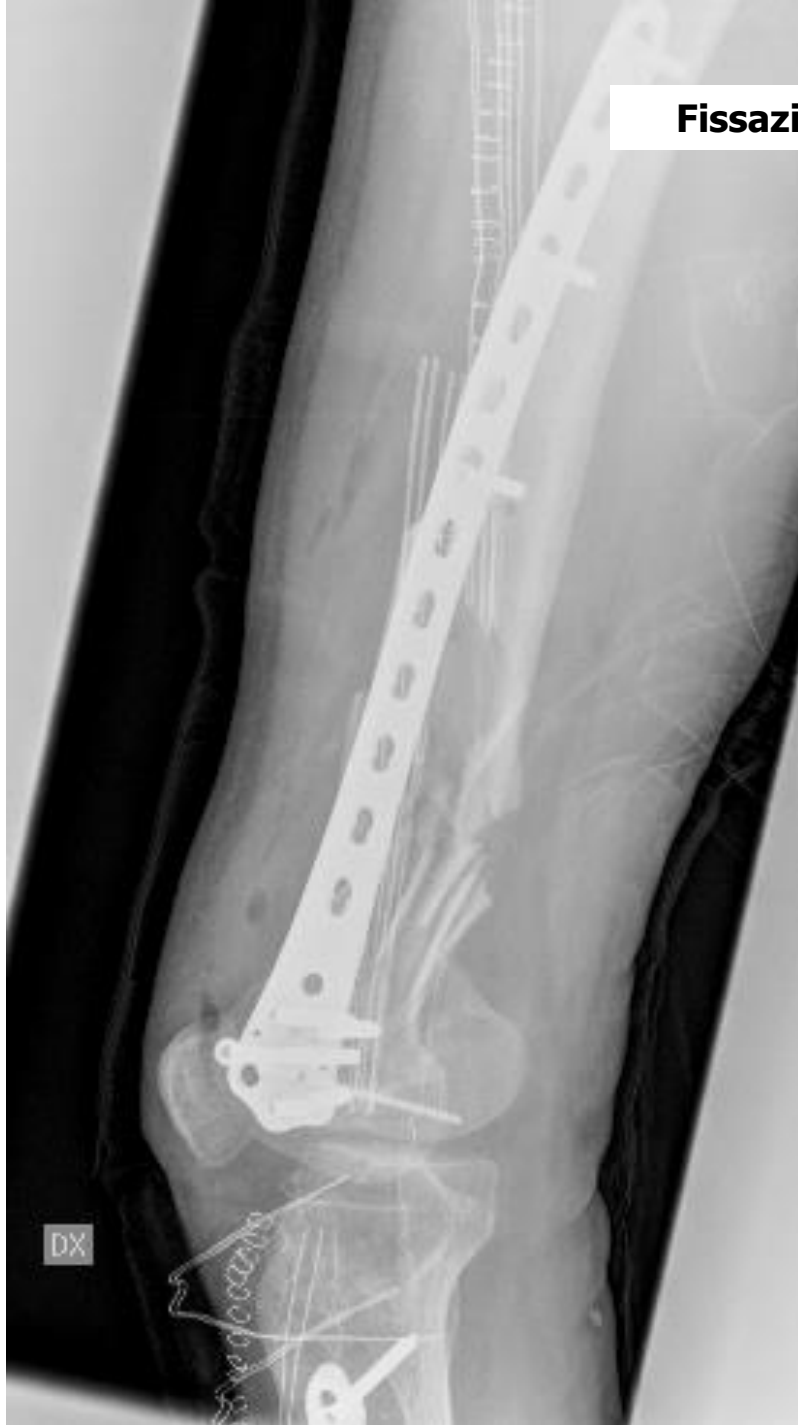
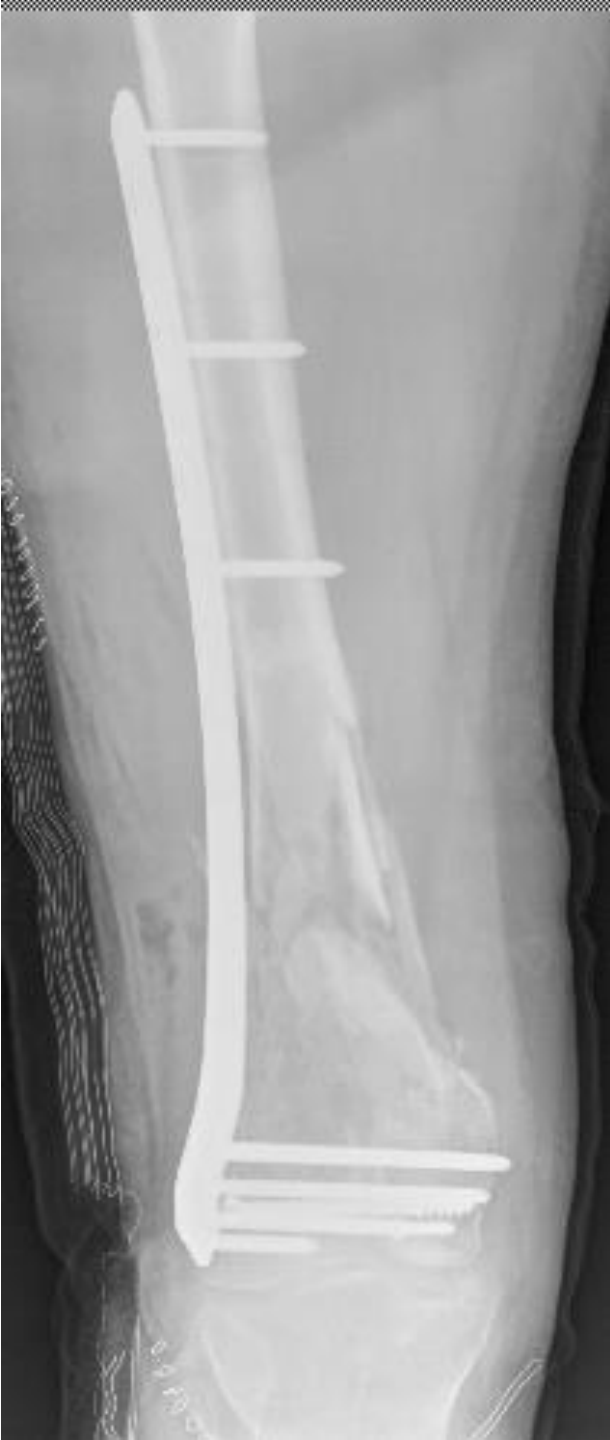




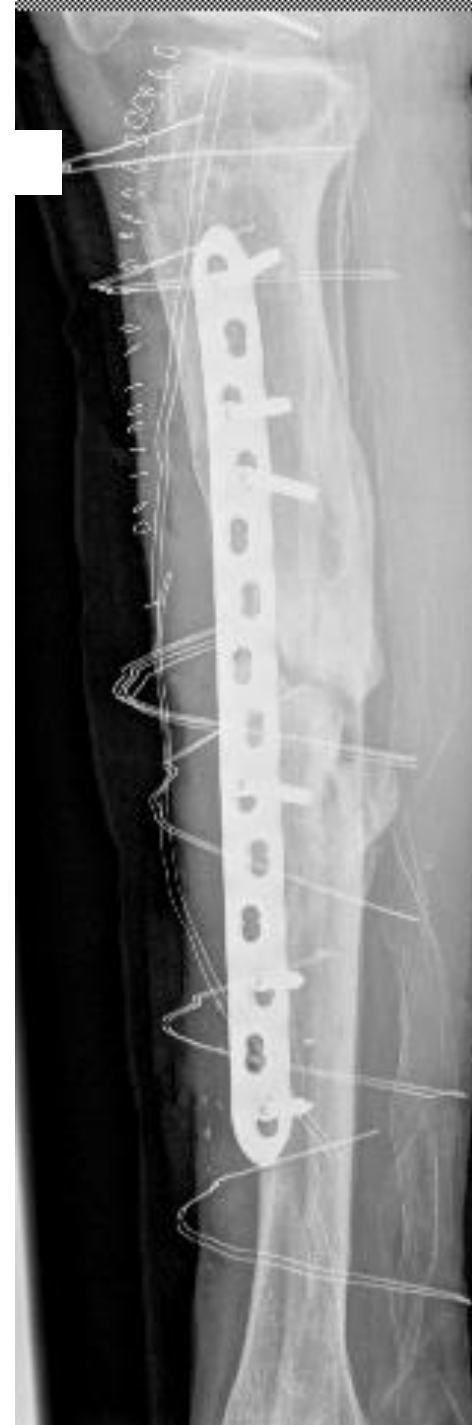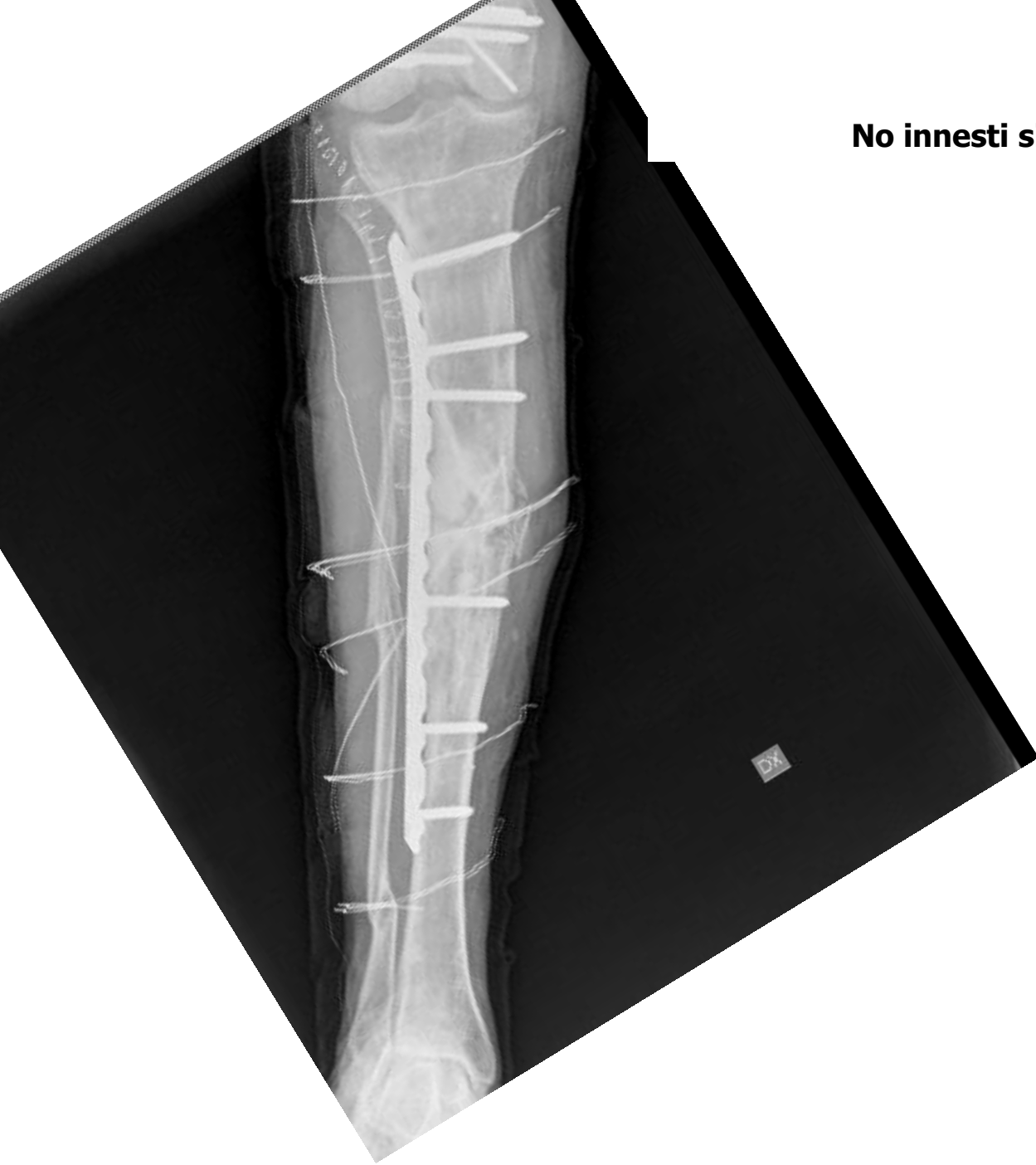A 20 mesi instabilità soggettiva

TC per studio precedente pseudoartrosi

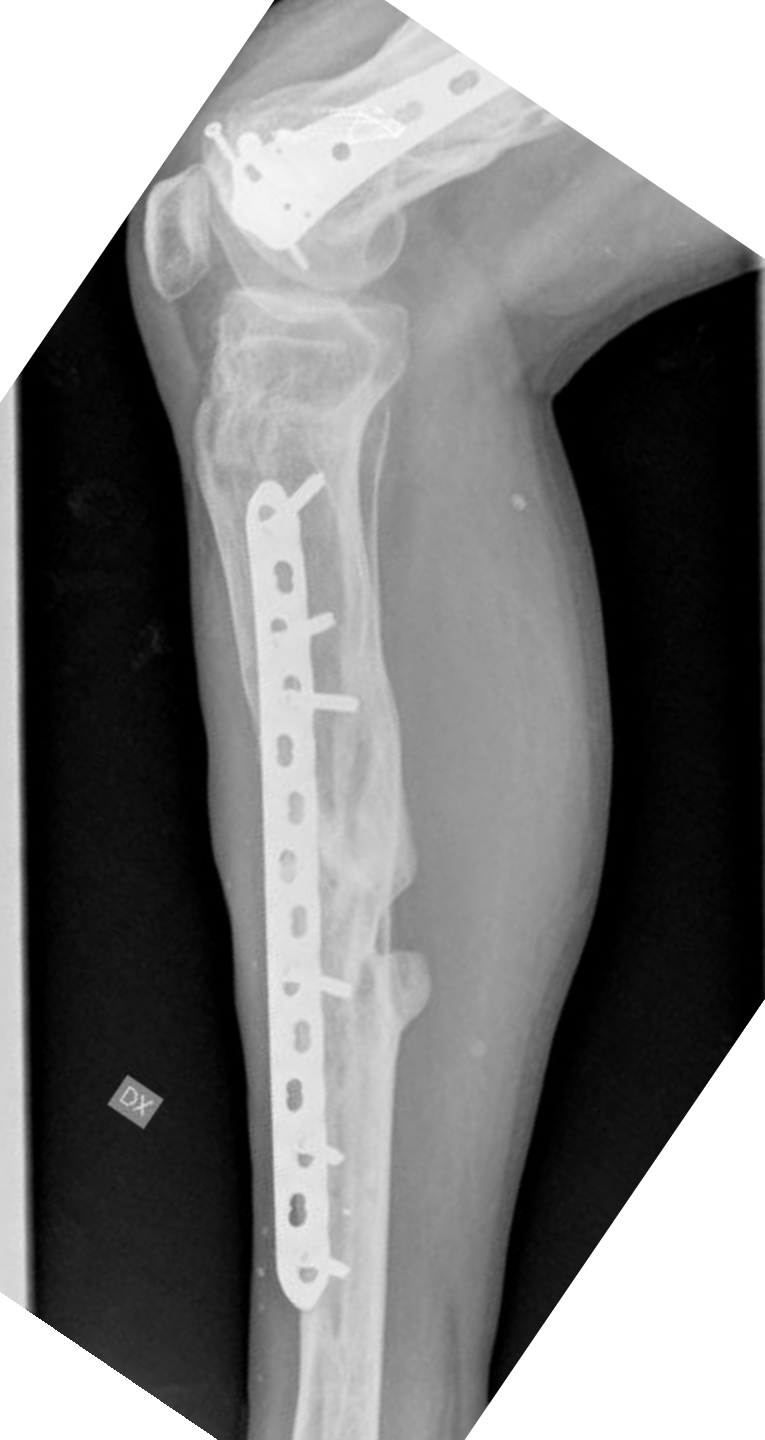
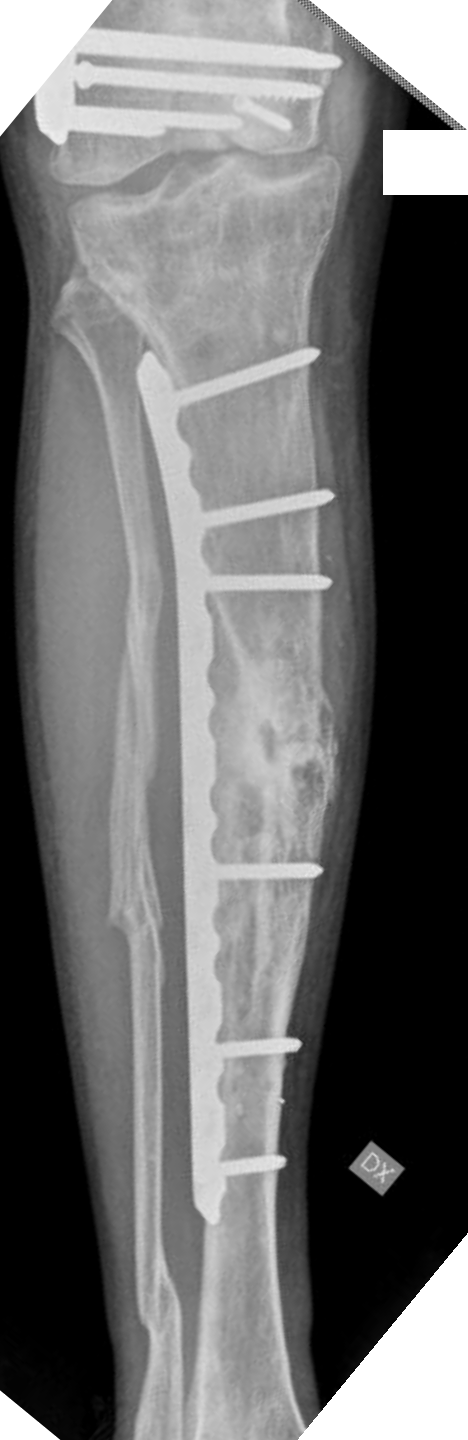
Fissazione femore + ... già che ci siamo...

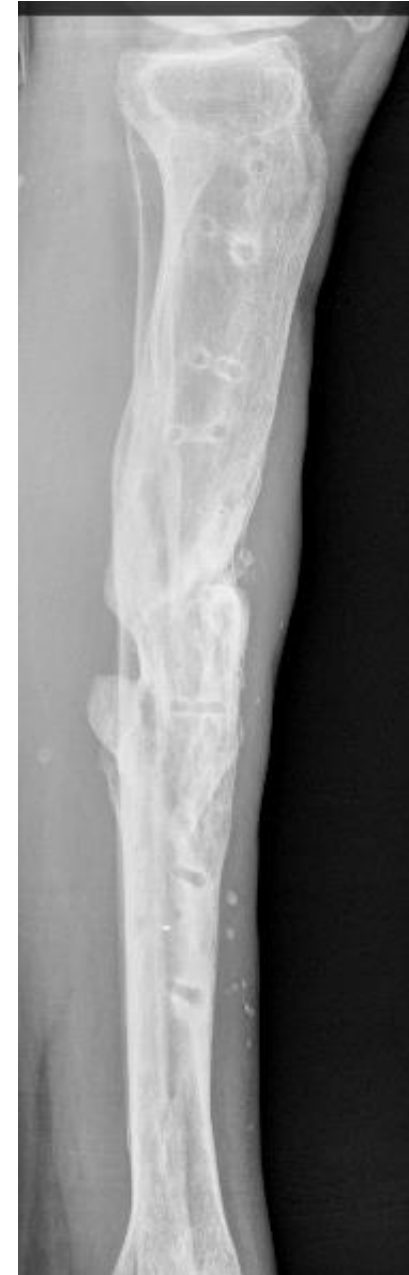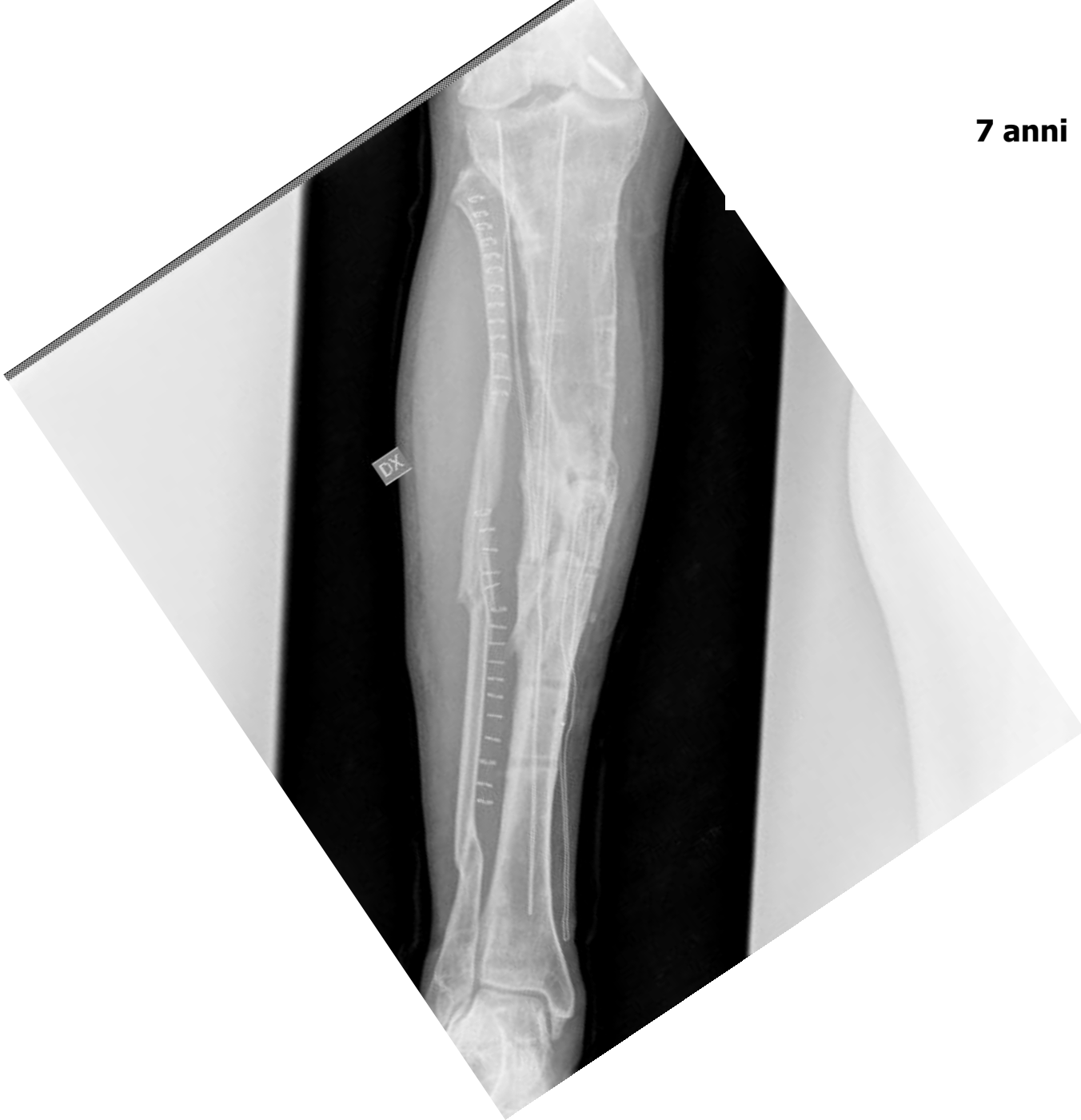No innesti si tenditore

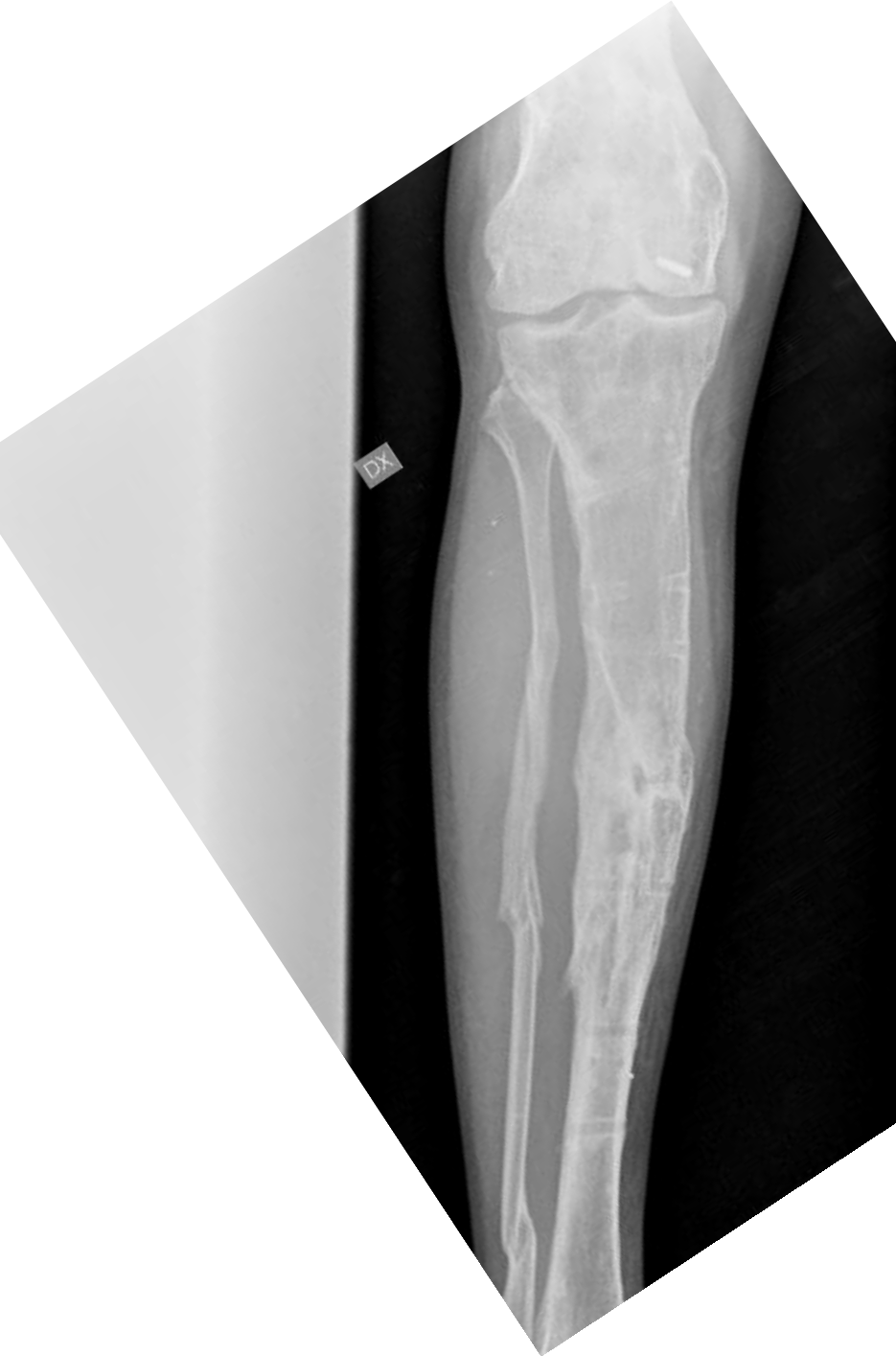

11 mesi



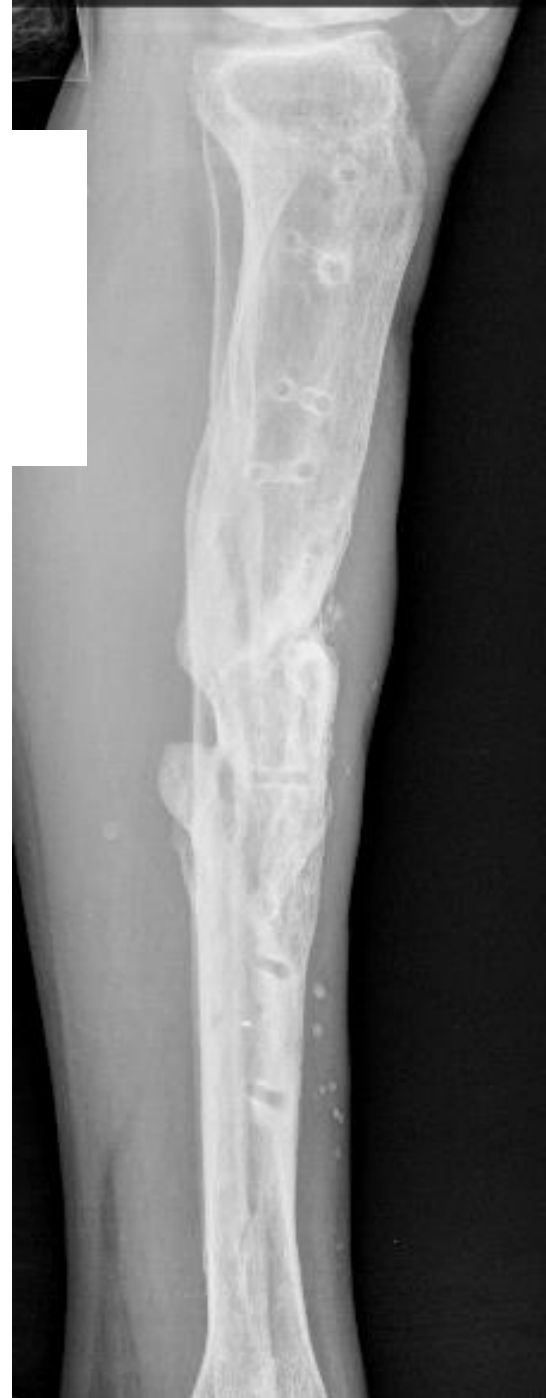7 anni





Feb 2017 at 8 years

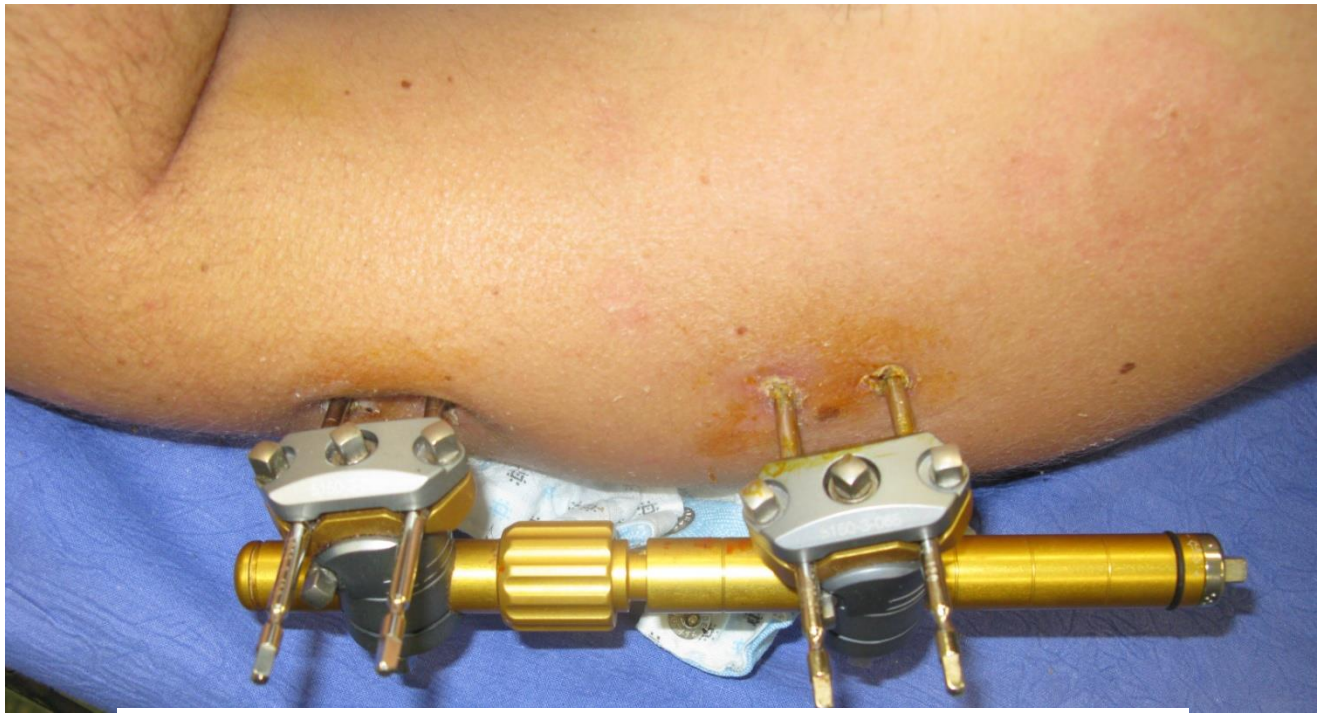
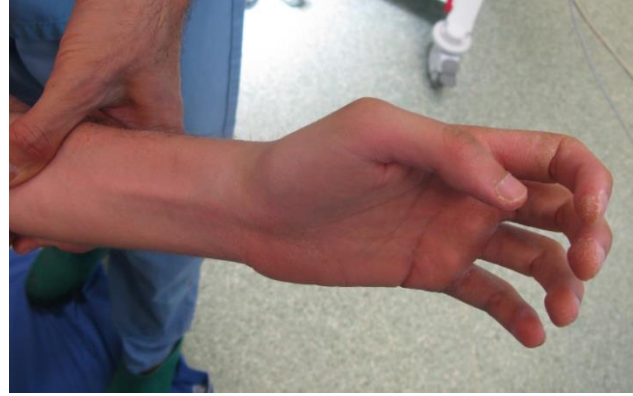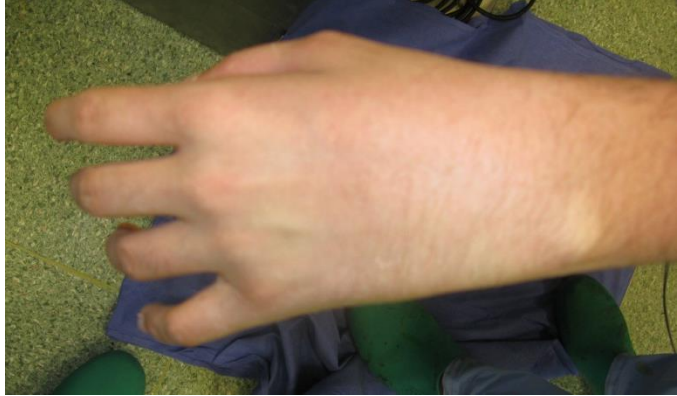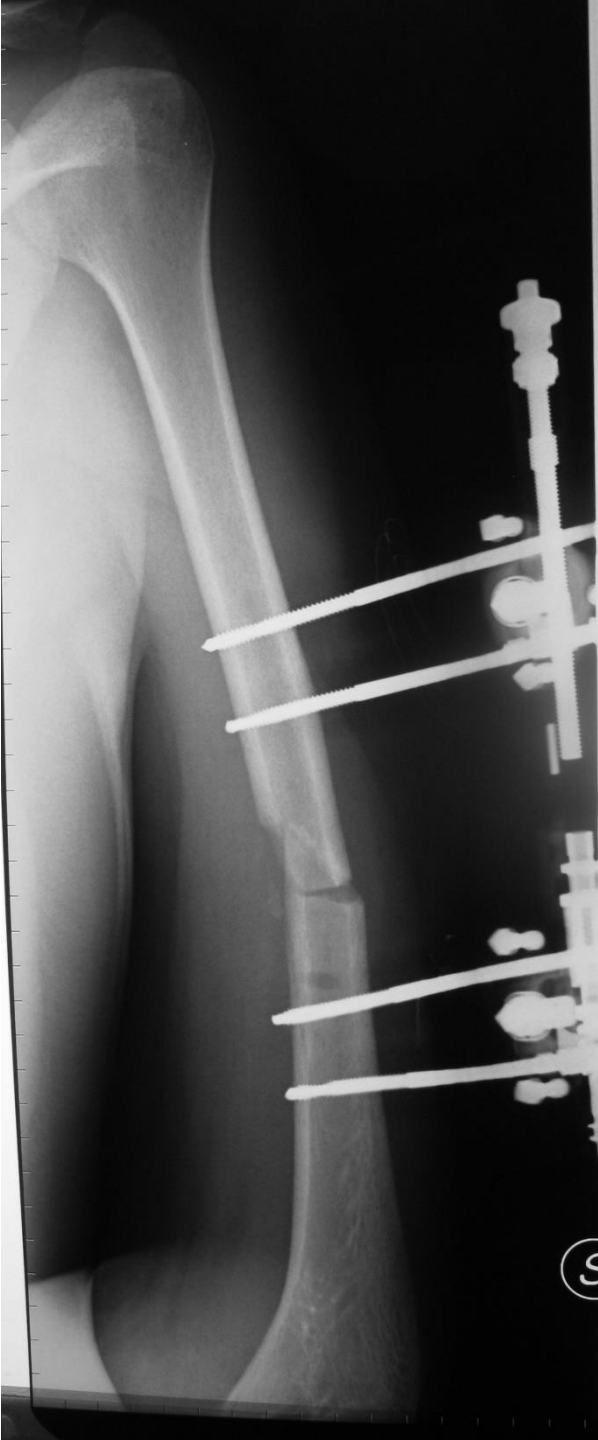THE END



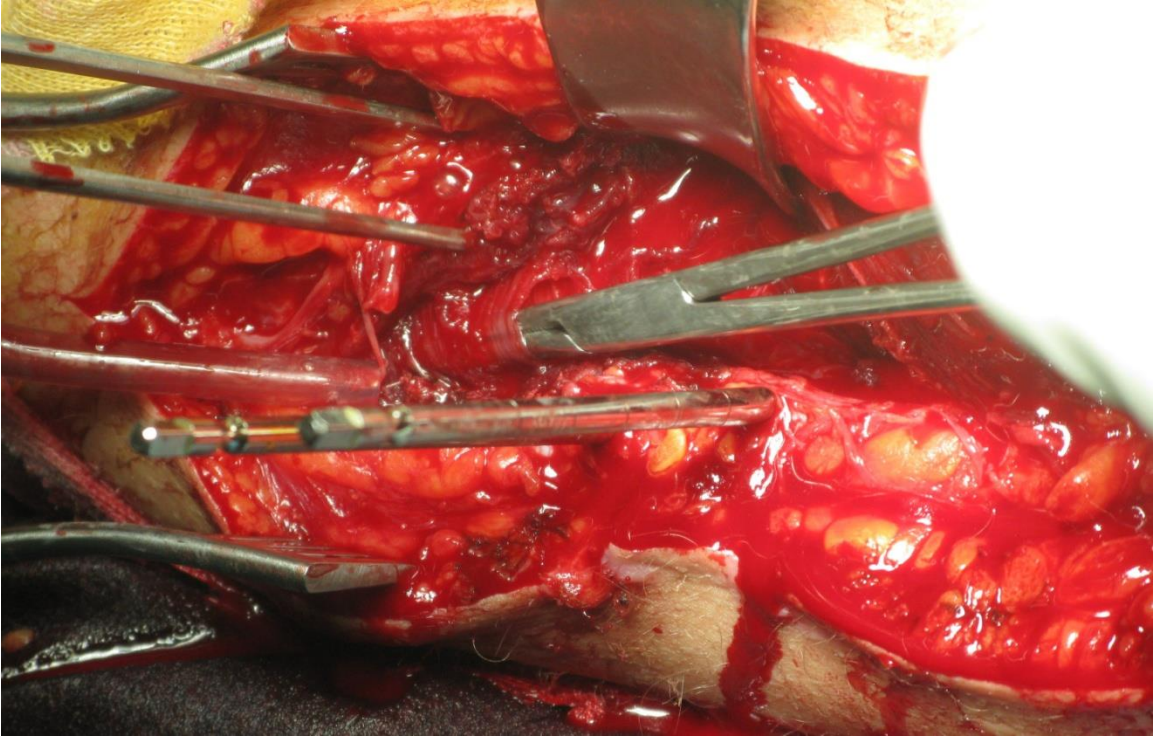Ad un certo punto ...
innesti nel docking site

Per i critici del «fissatore e.terno»

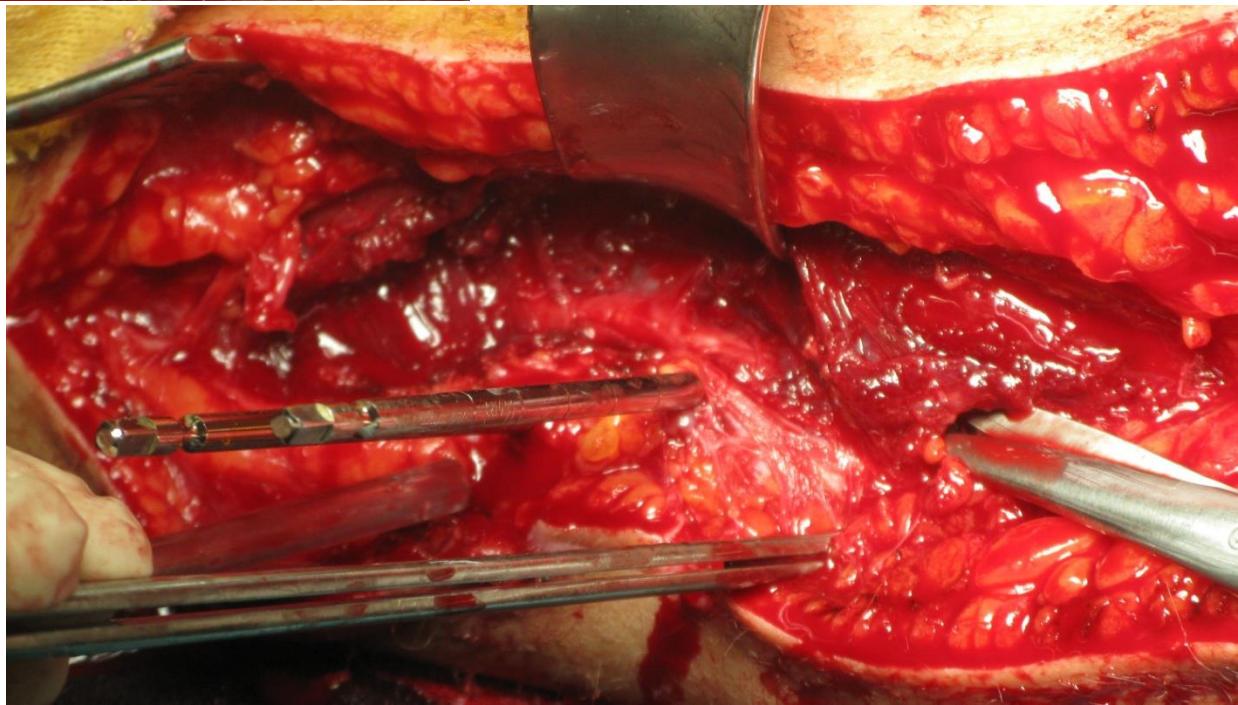
Complicanze

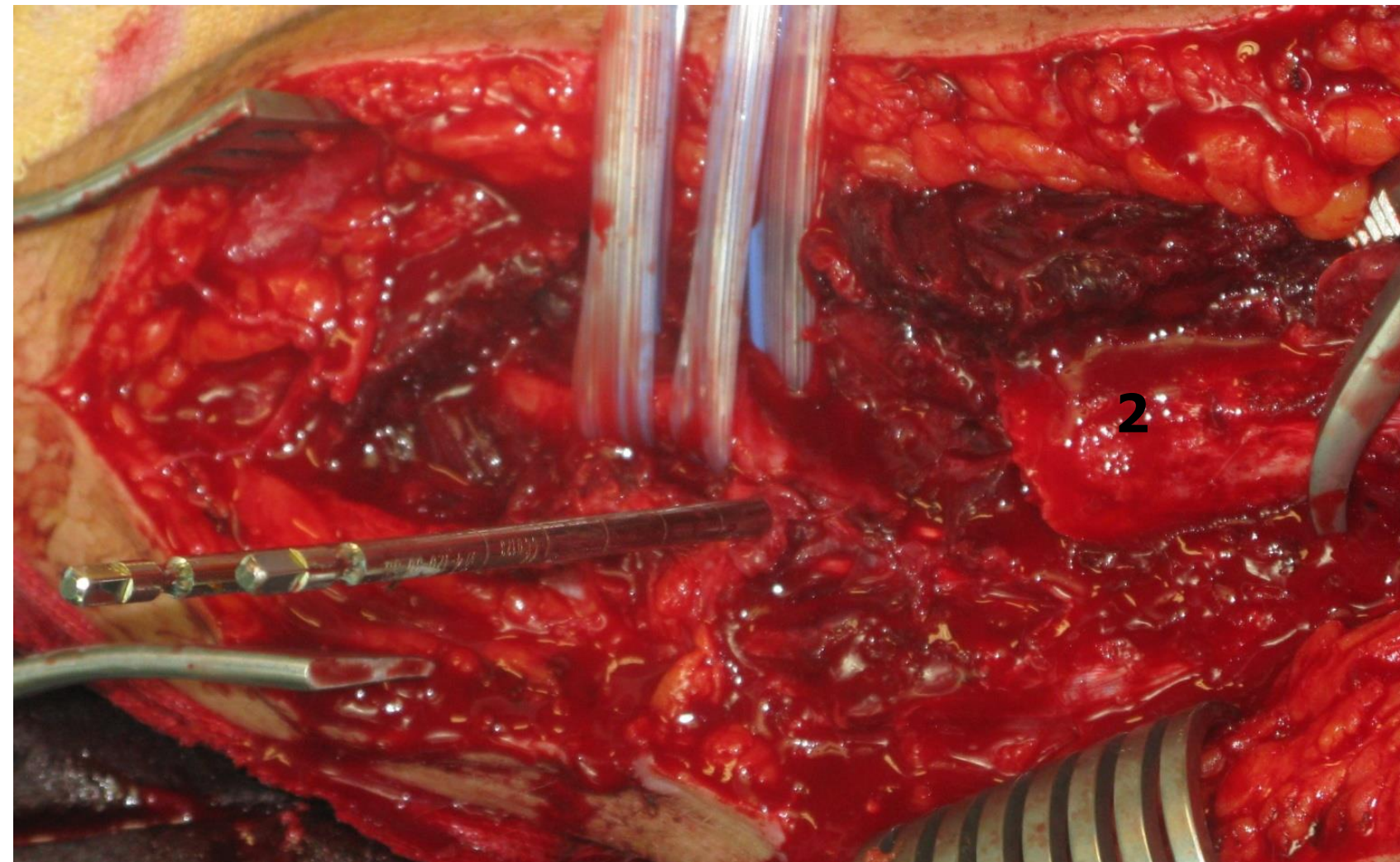


**Uomo a 2 mesi dal trauma fr
con paralisi del nervo radiale
ospedale 1 exfix**

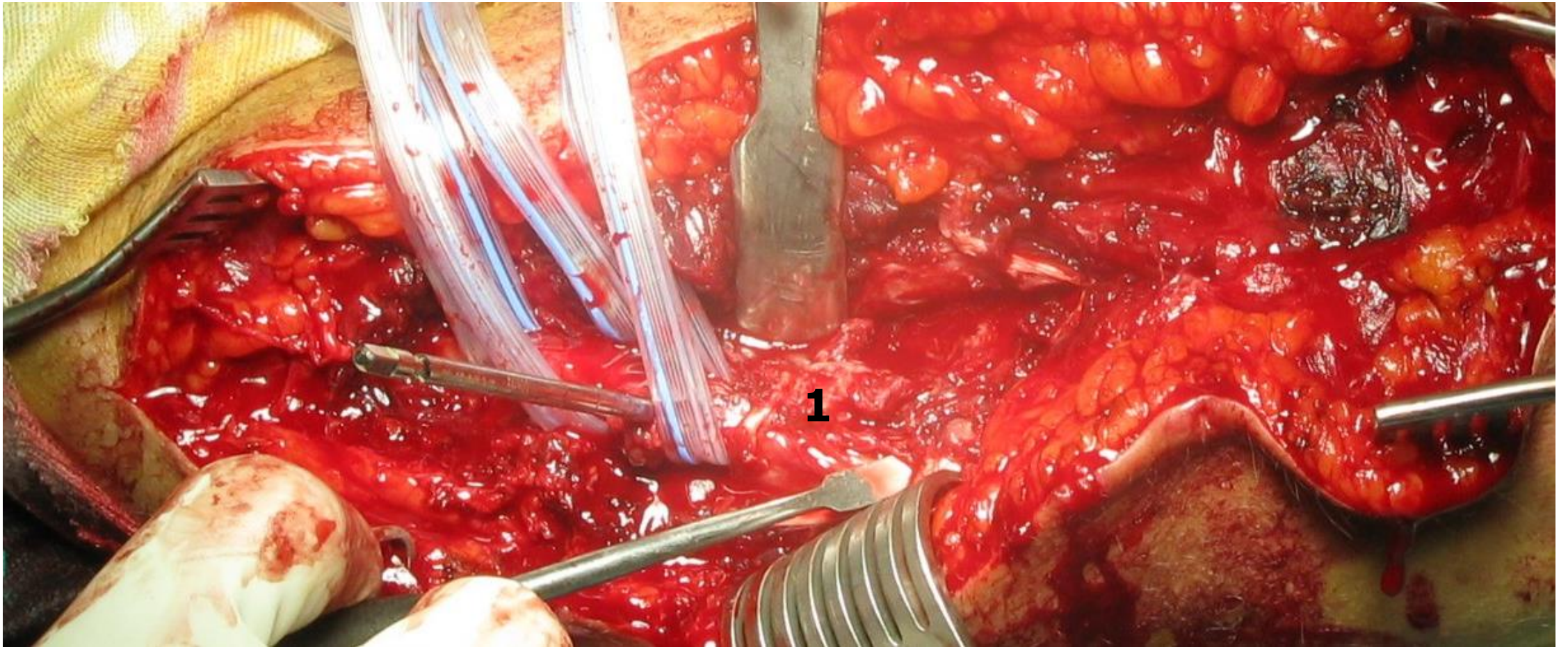


**lasciando le fiches
isolamento del n.
radiale**

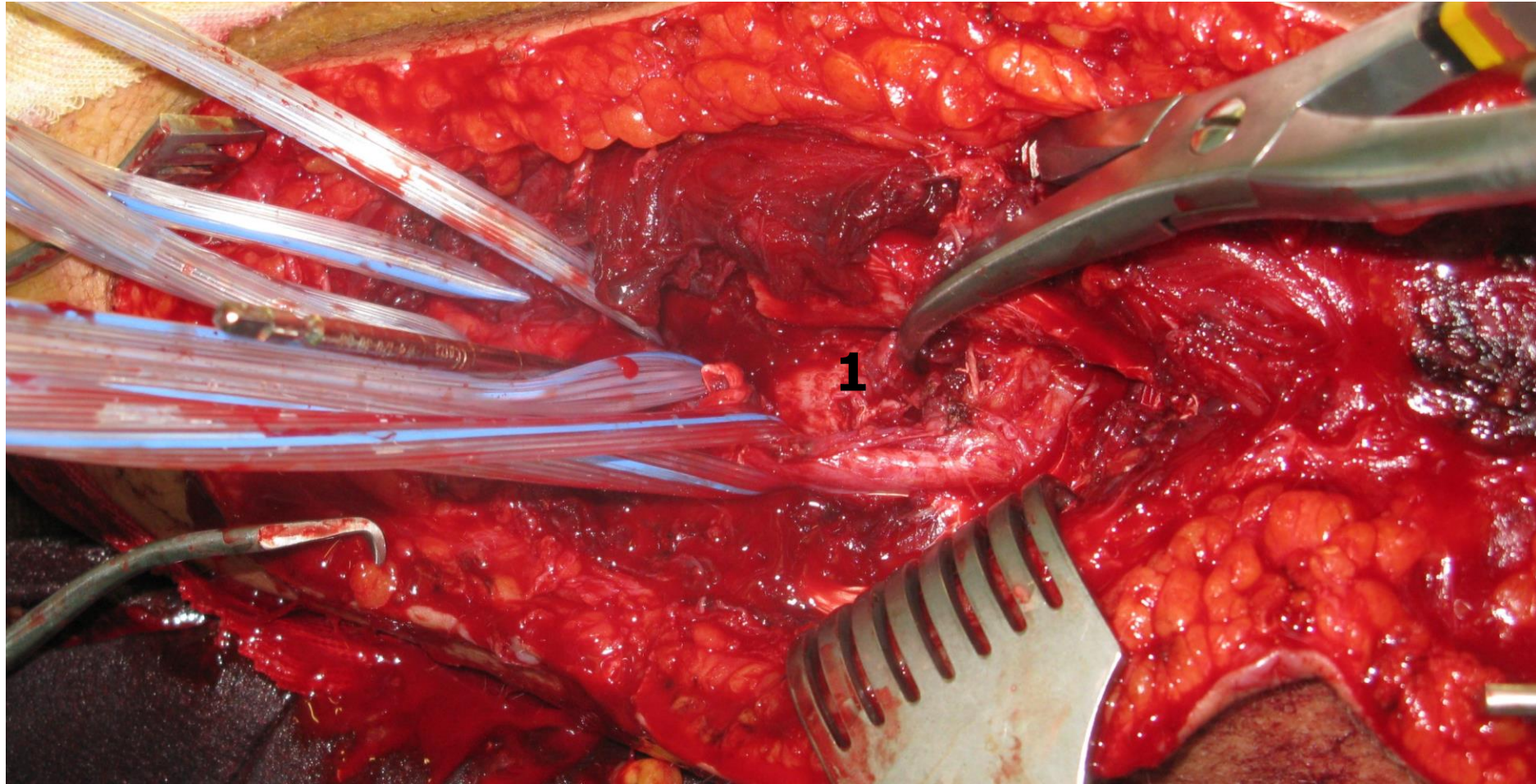




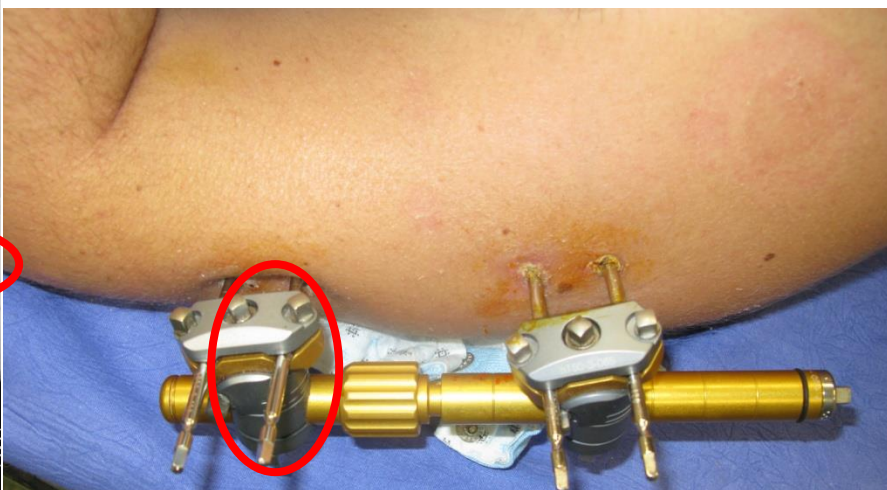
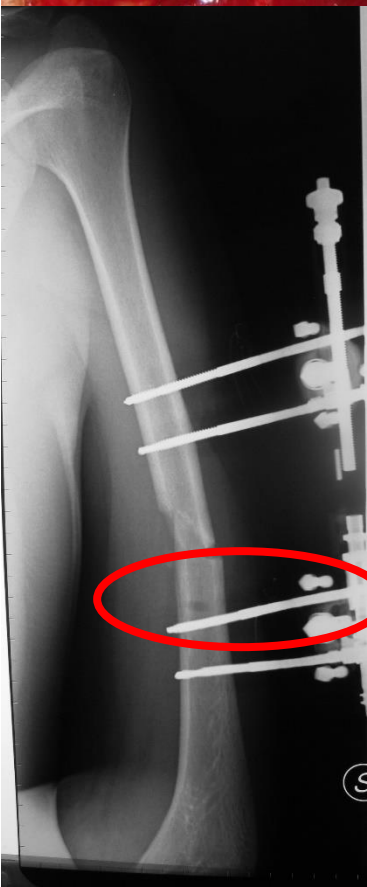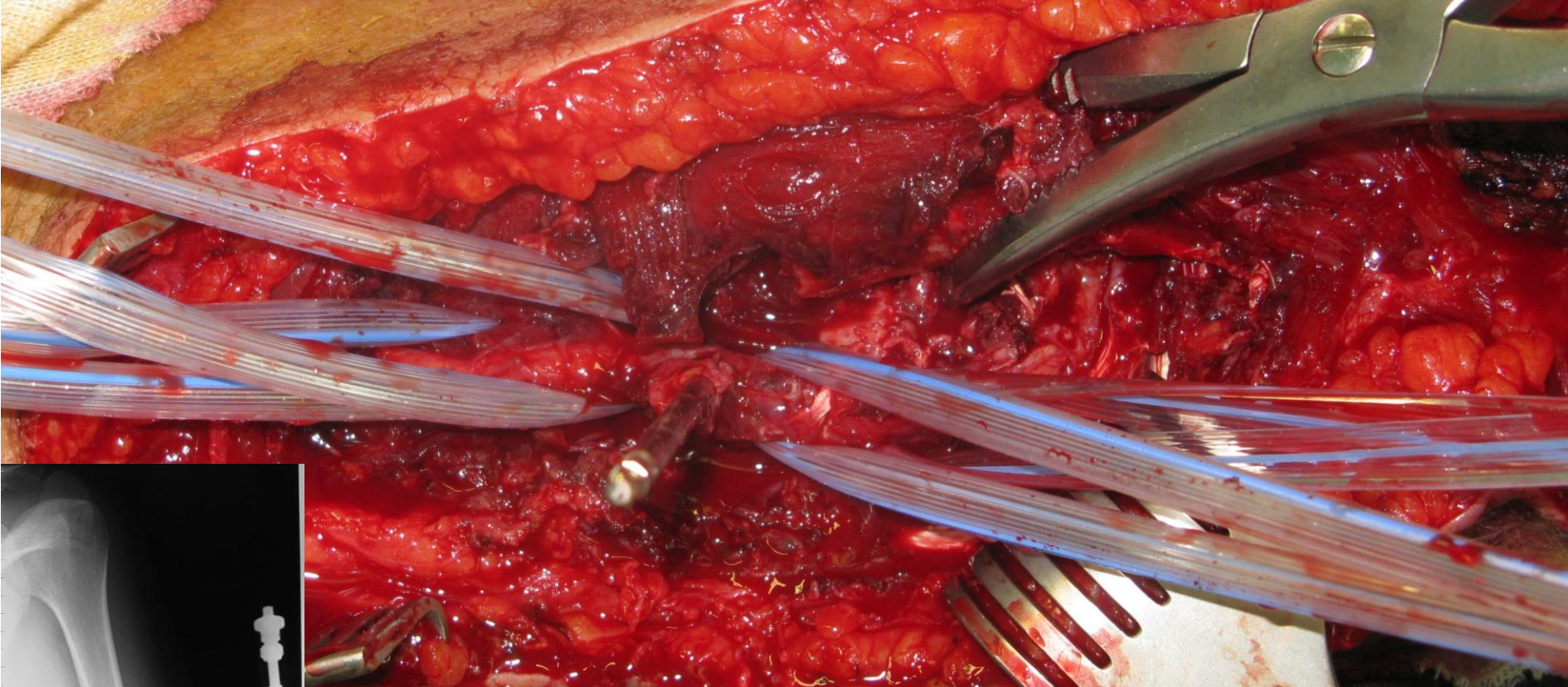
**(2) moncone
prossimale**



**separazione del moncone distale (1) dalle
aderenze con il n. radiale**

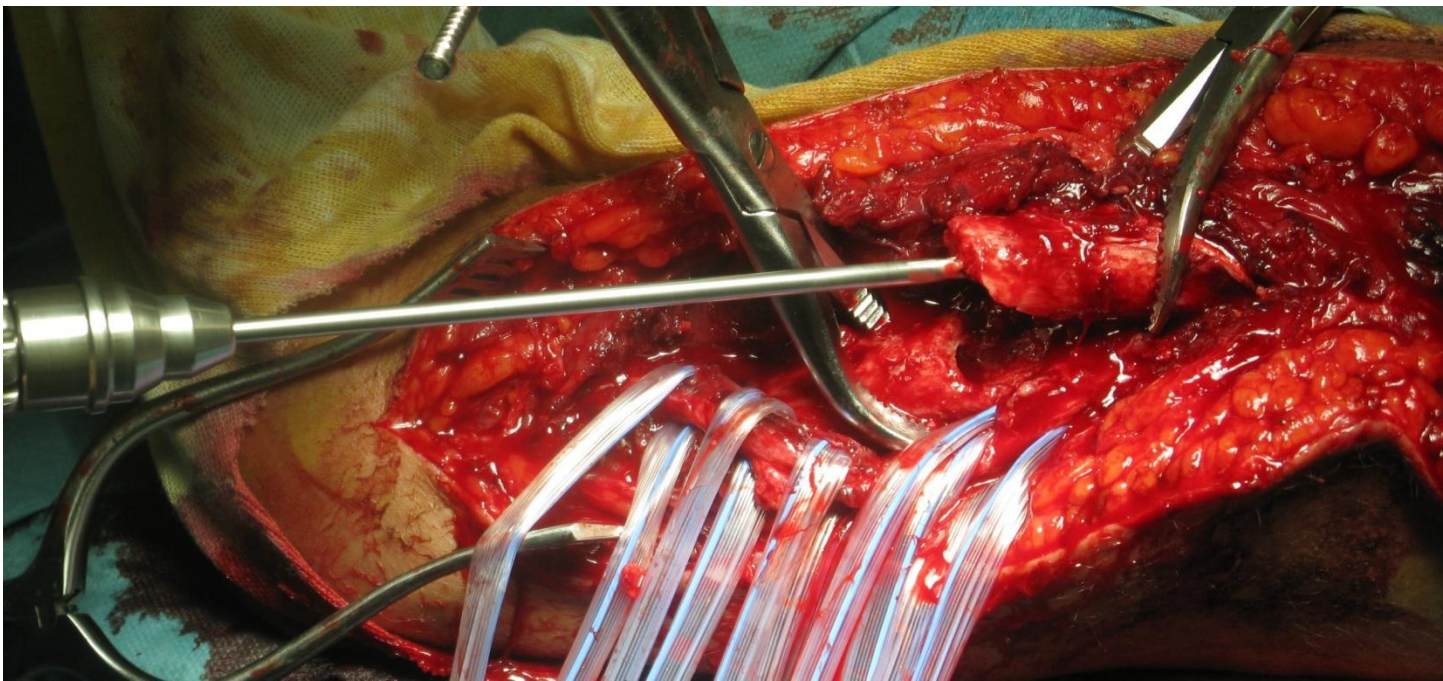
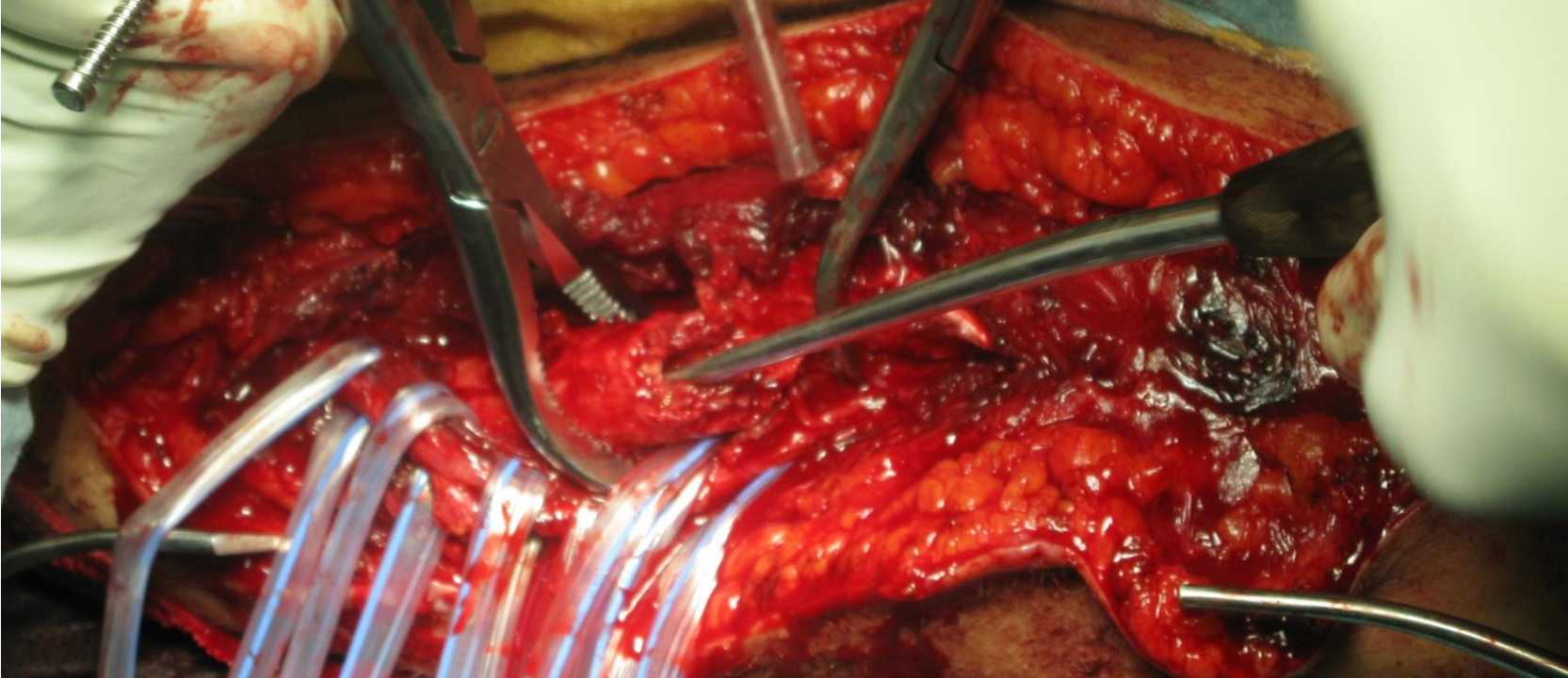

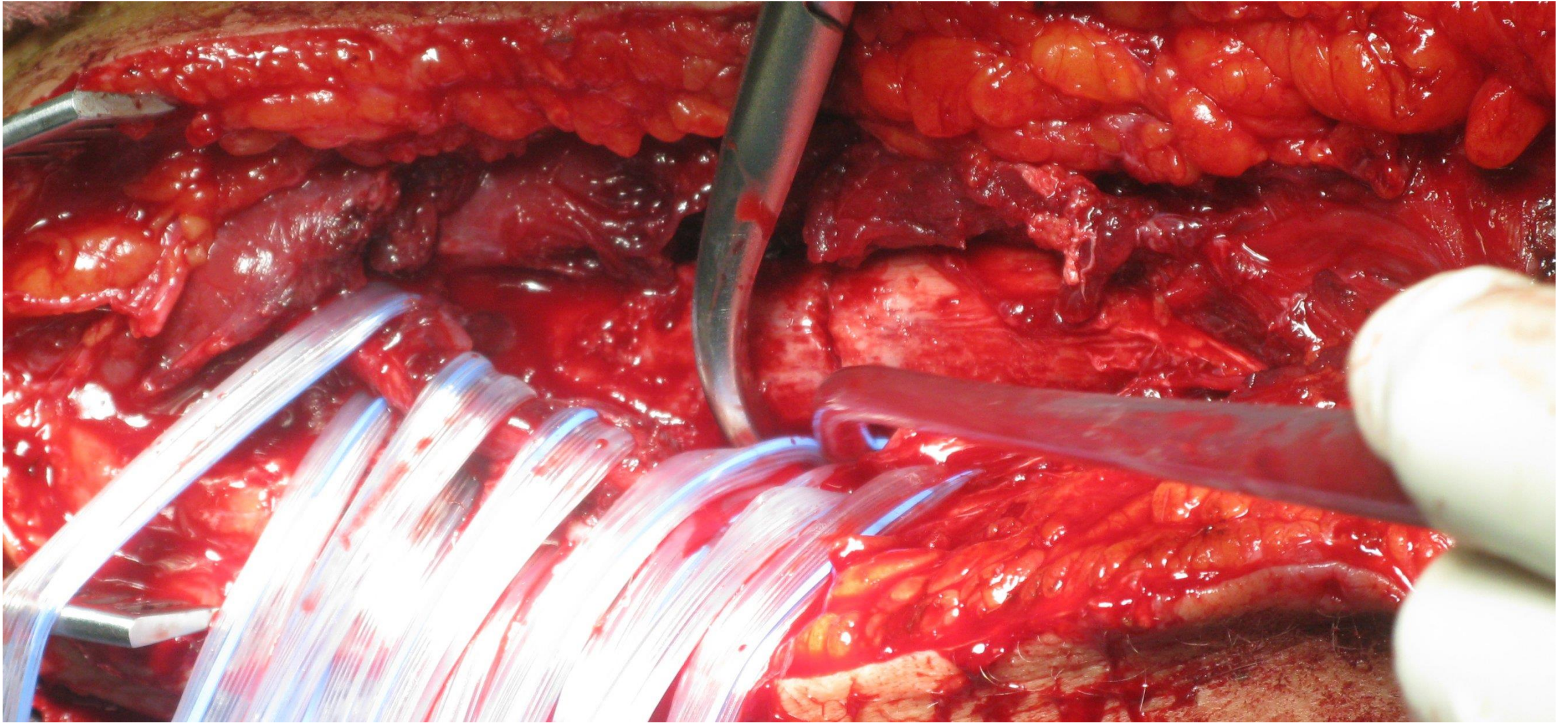
**ora il moncone distale (1) è mobilizzabile
senza interferire con il nervo**

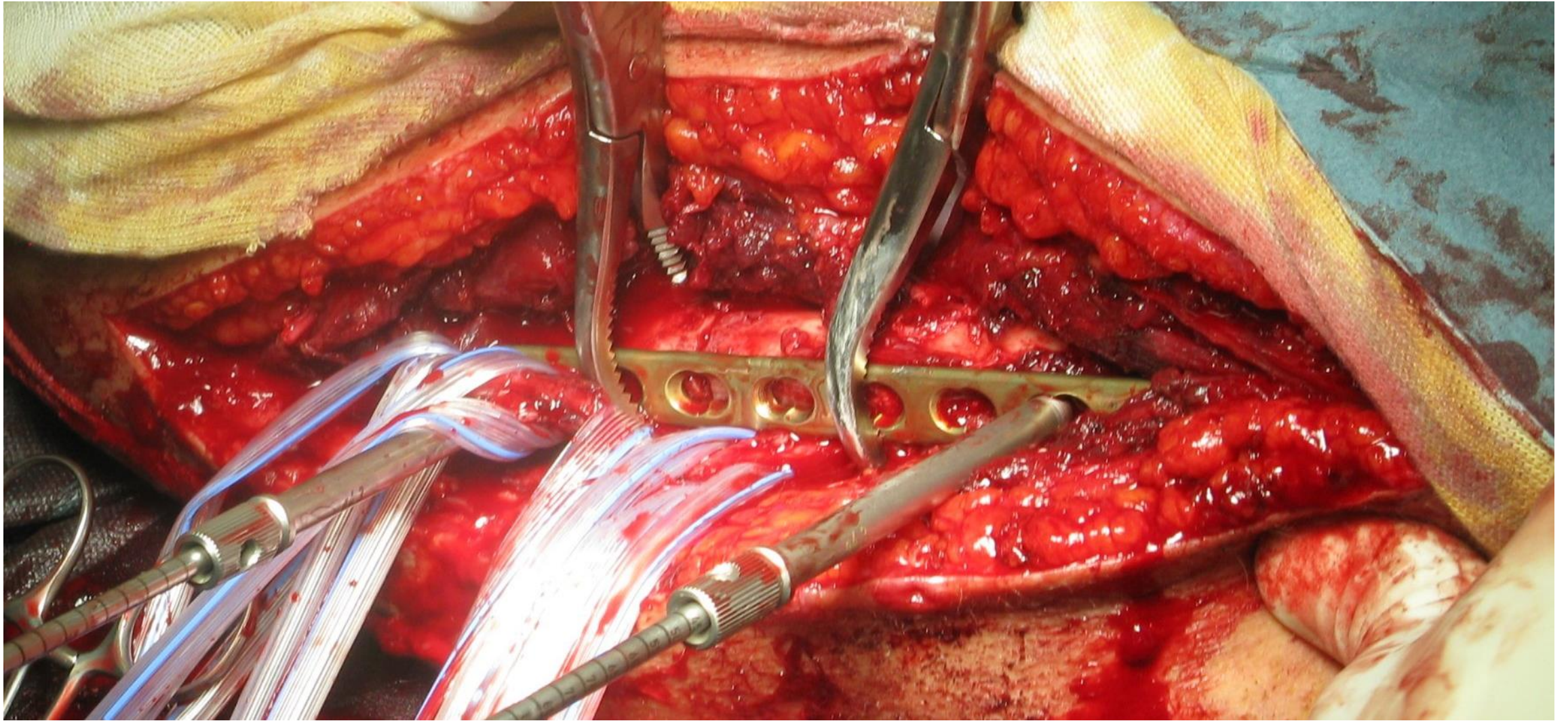


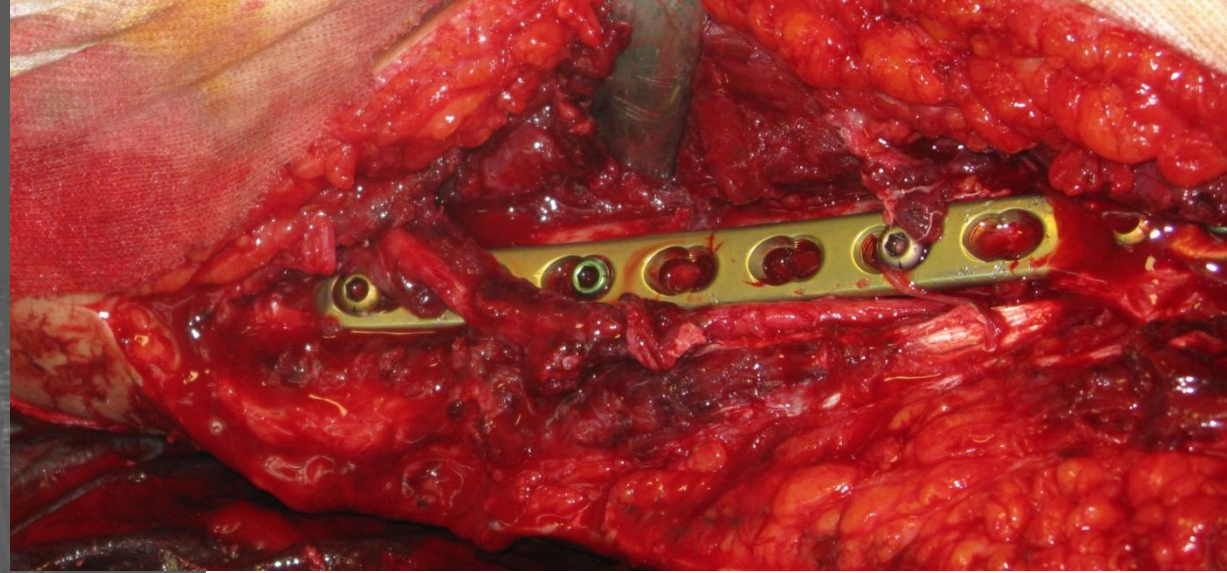
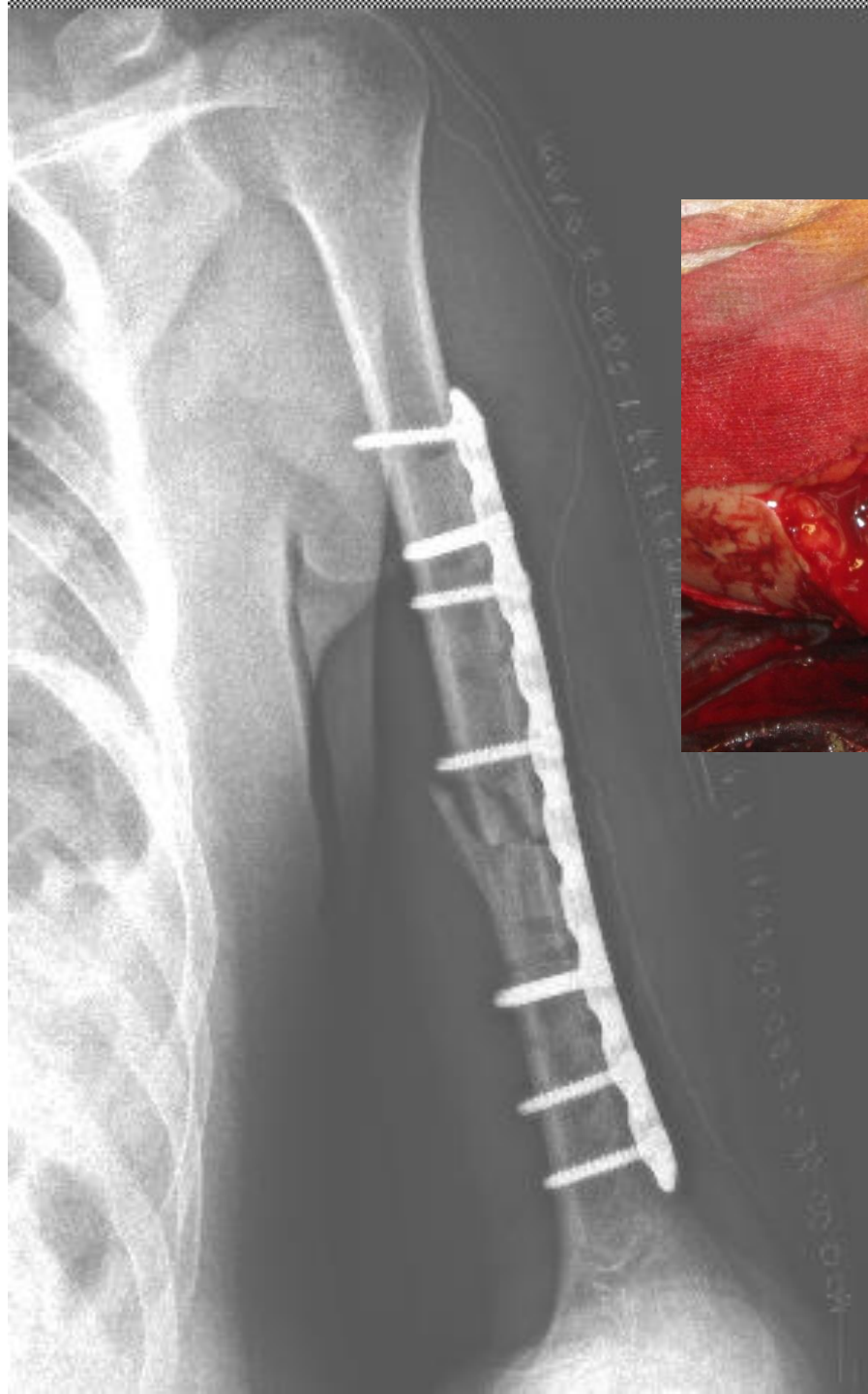
**La fiche
piu'prossimale
delle distali è
purtroppo al
centro del nervo**

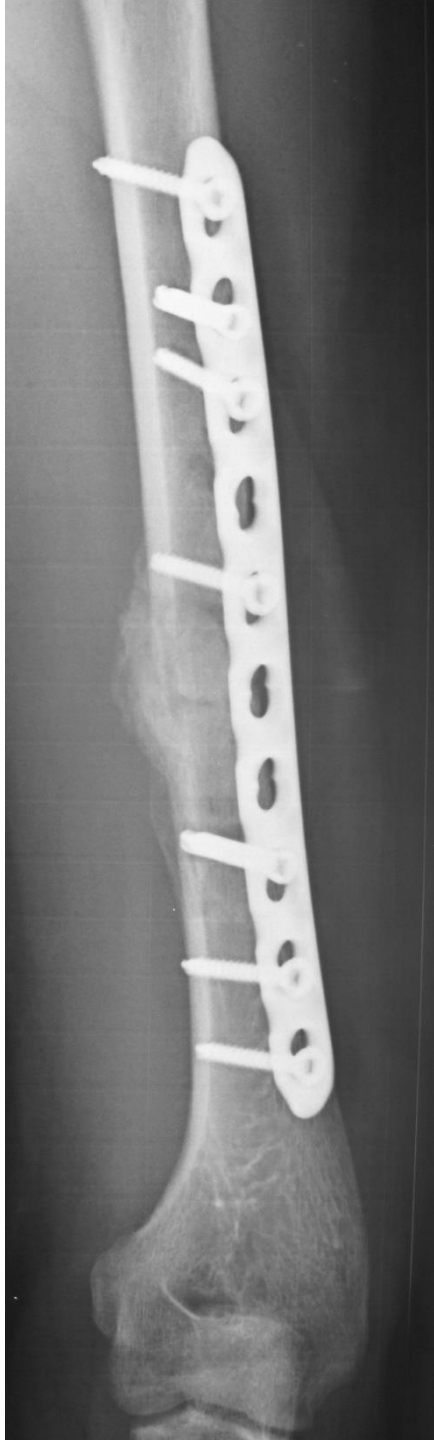






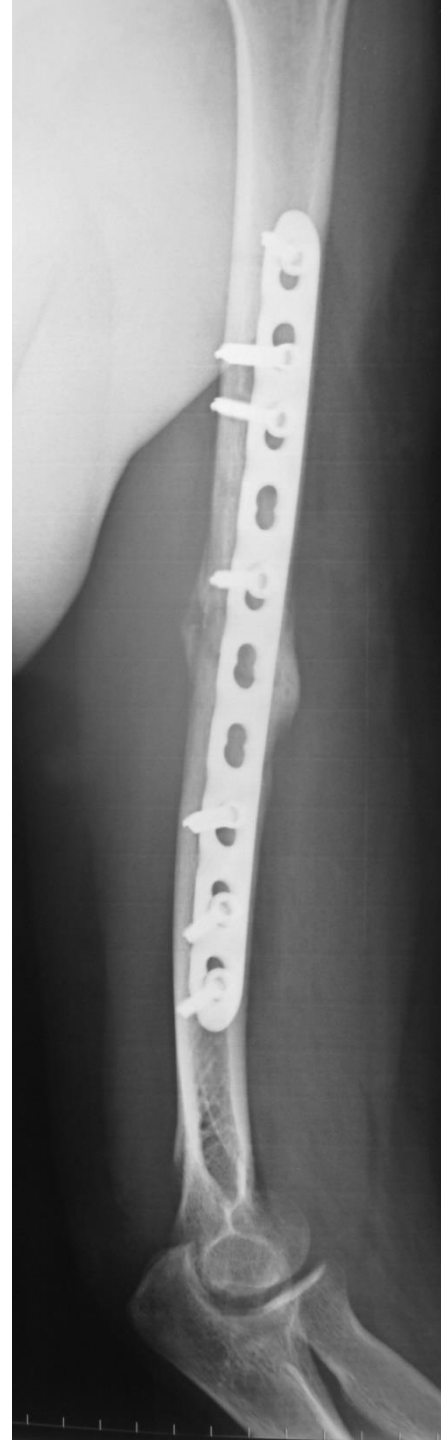




LUGLIO 2011

**A 5 mesi
ripresa
completa del
nervo radiale**



Le viti distali nell'omero devono essere posizionate proteggendo il nervo radiale.

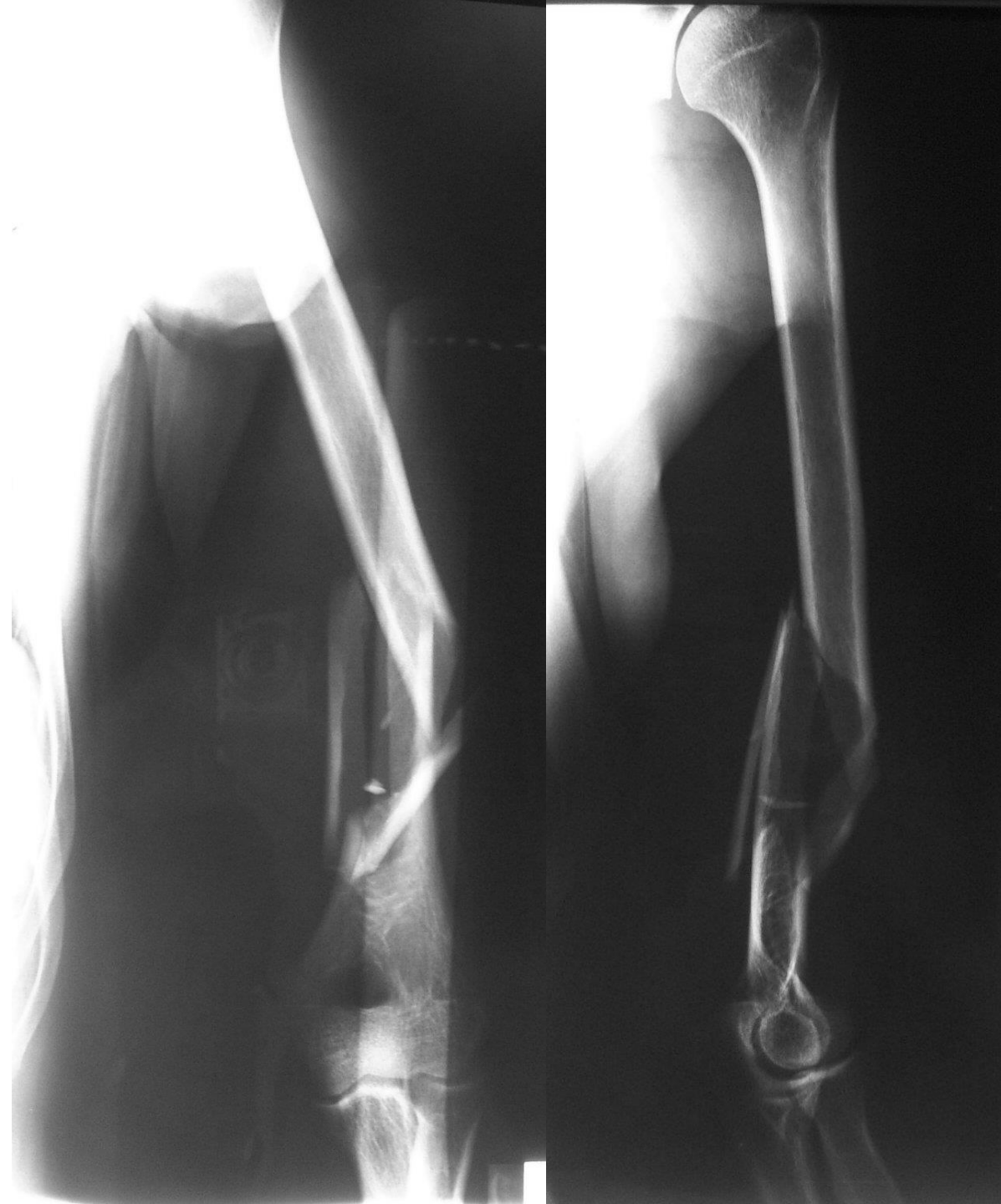APRITE!!!!

NON CONTATE I CM O LE «DITA» DAL CAPITULUM!!!

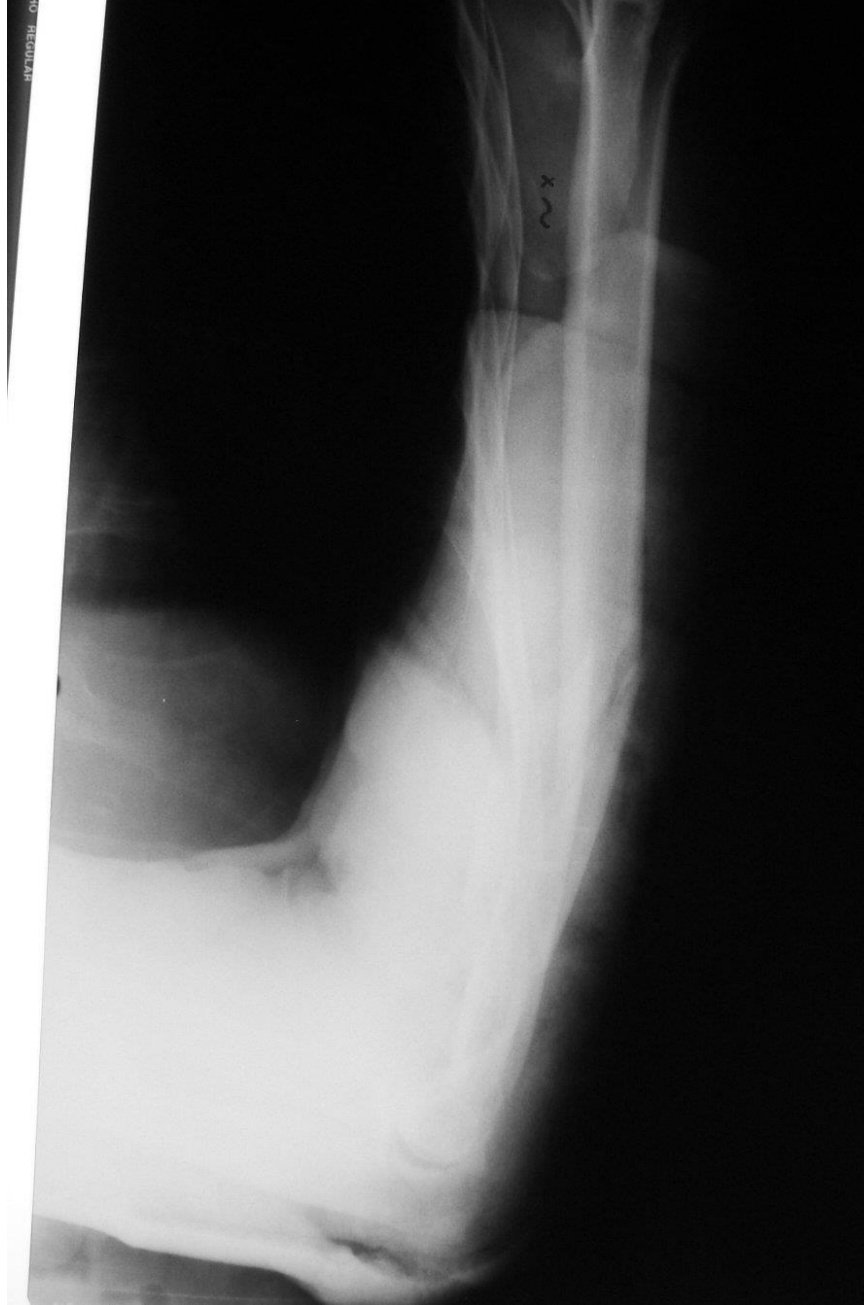
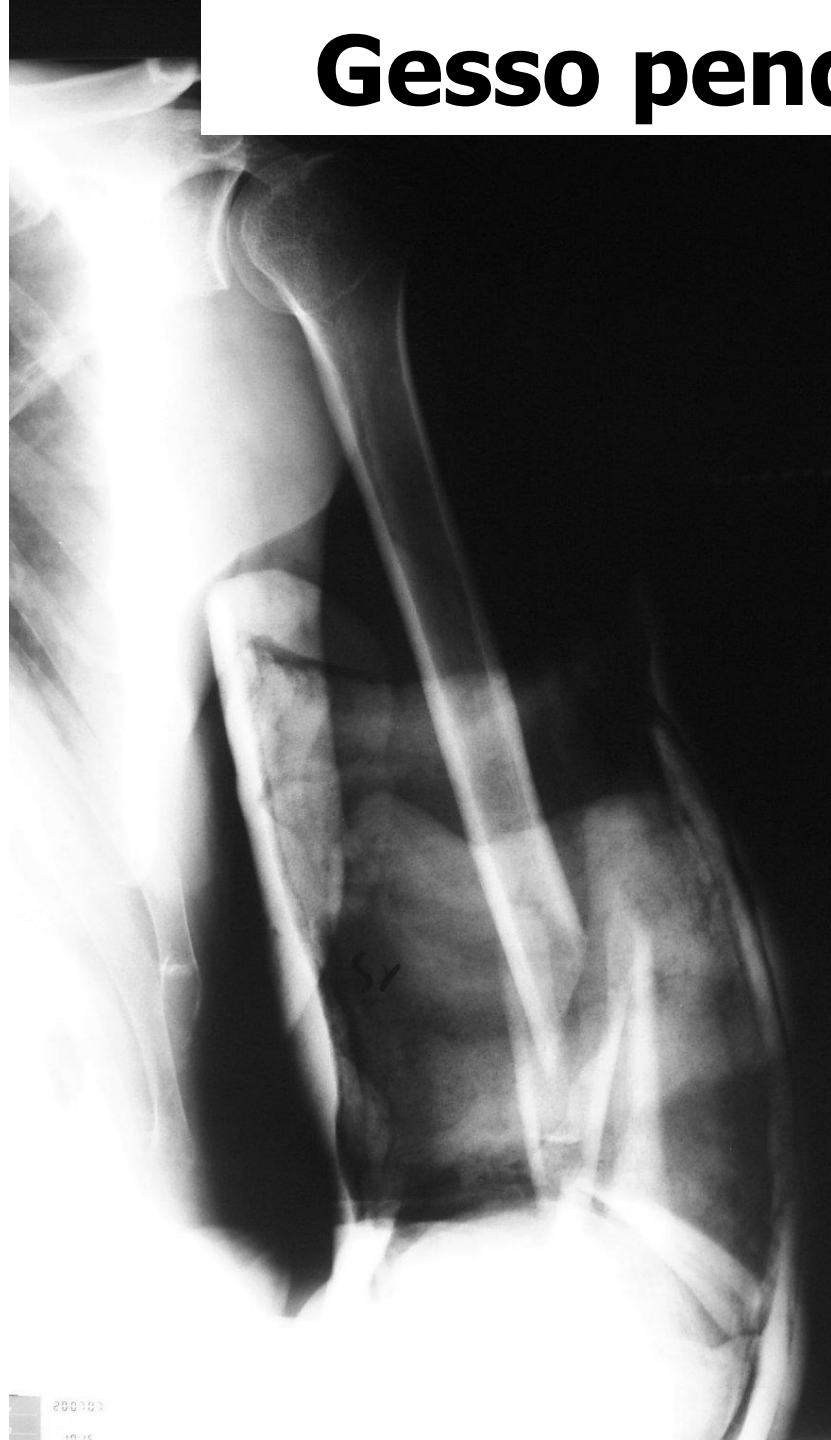**Uomo aa 54
caduta
accidentale**

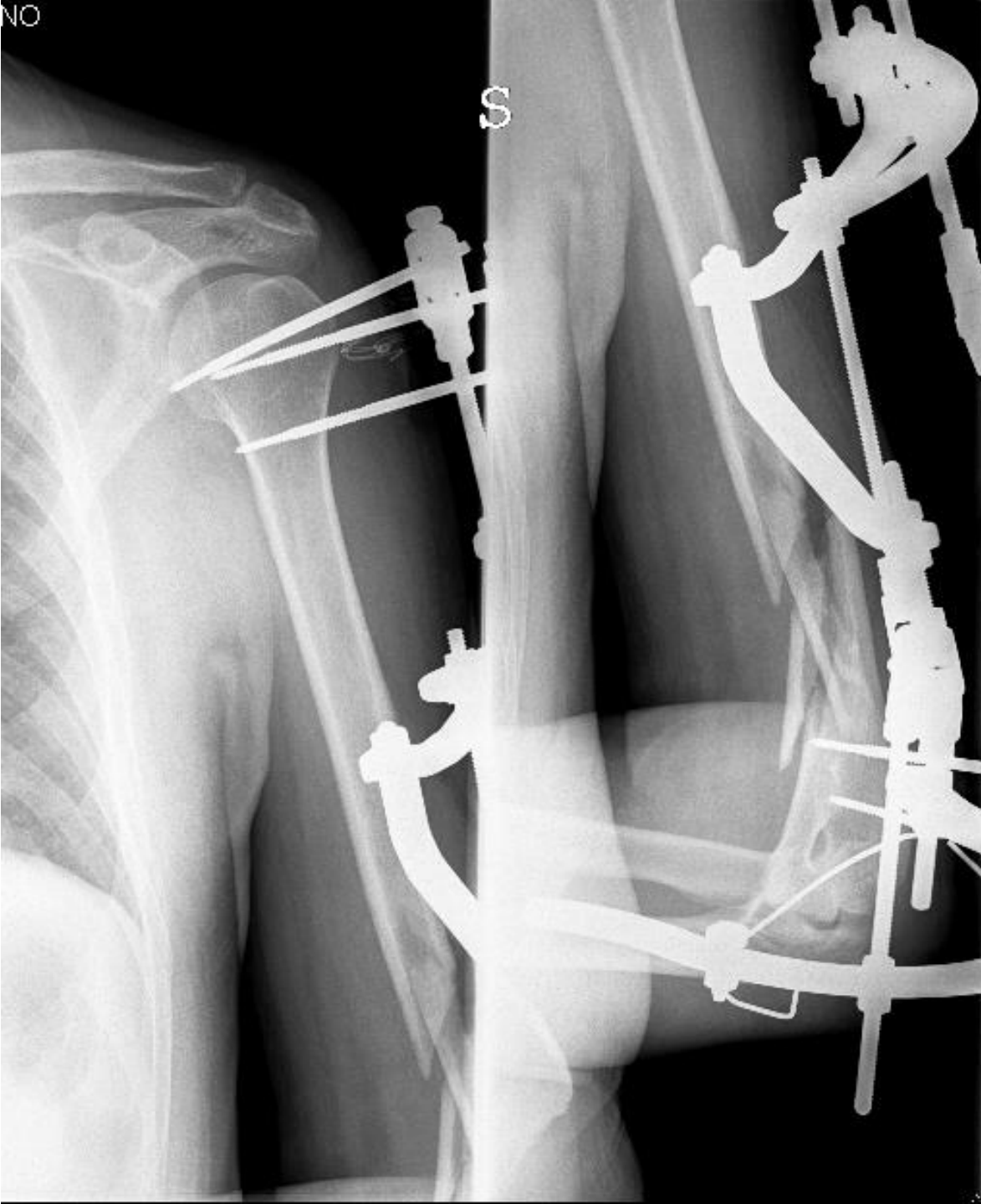**Fr chiusa
con paralisi
radiale**

lug 07



Gesso pendente – ospedale 1

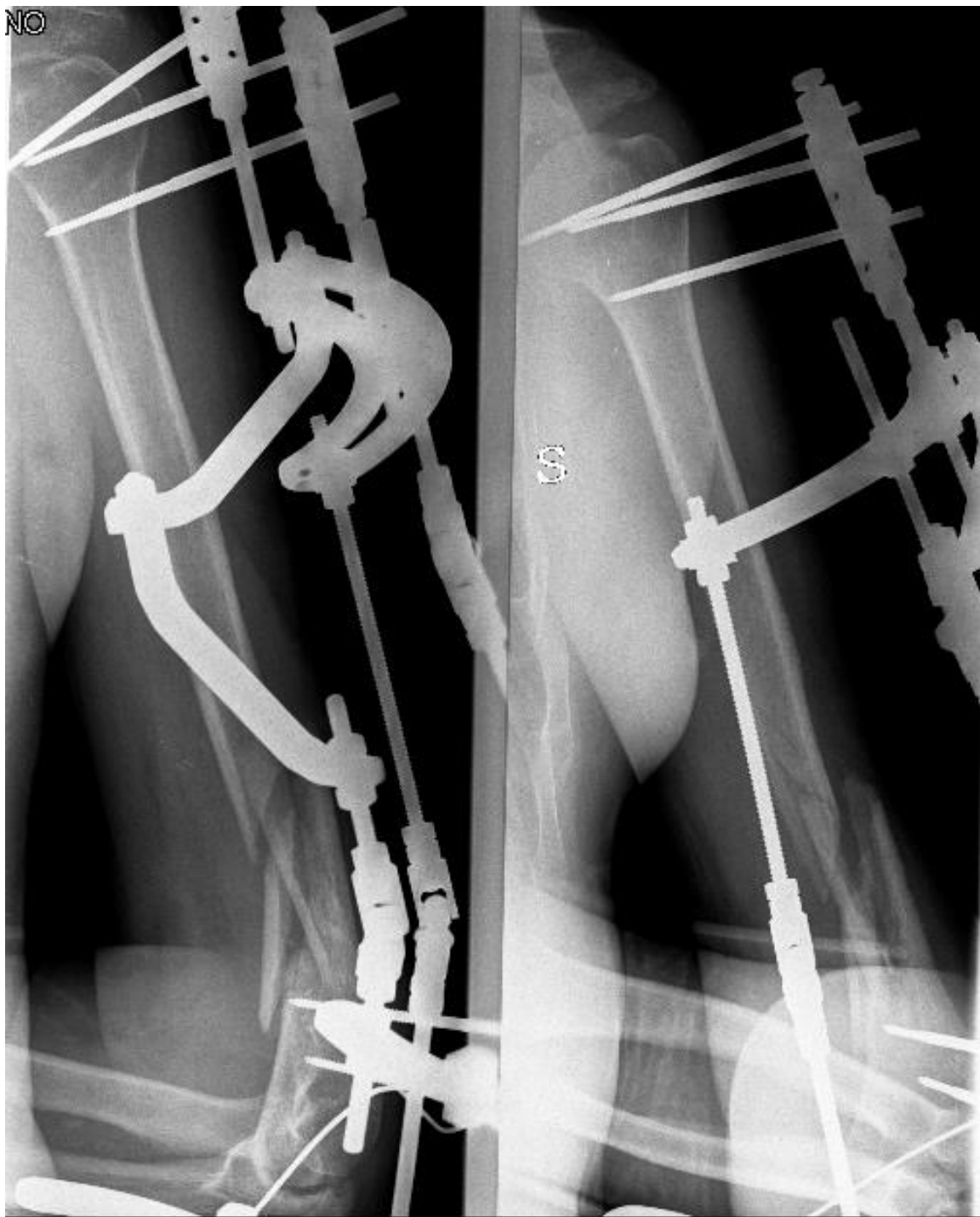



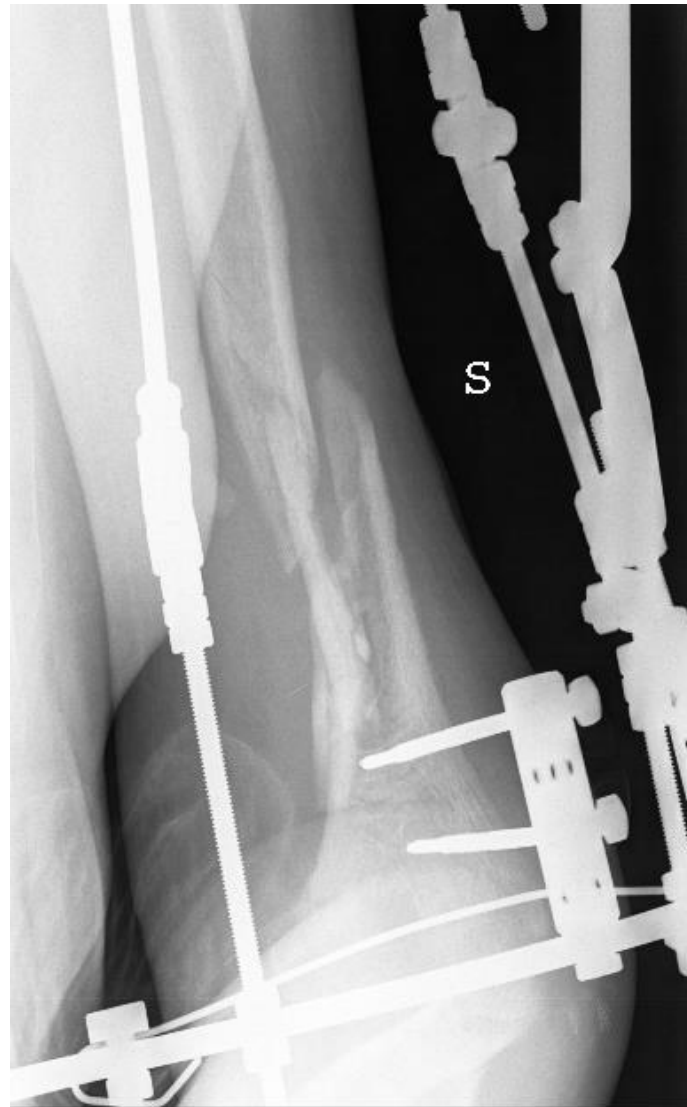
Ospedale 2

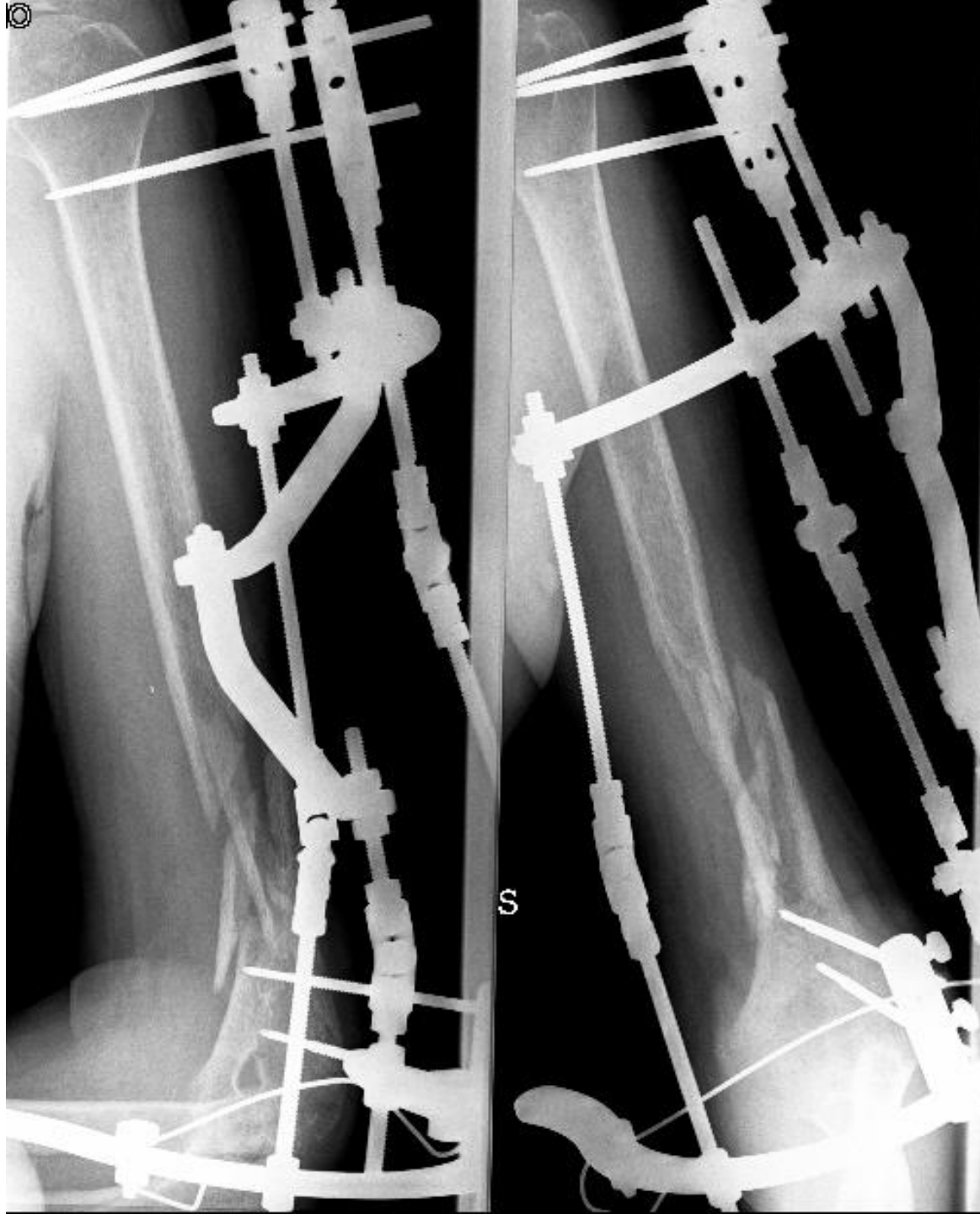**ago 07 a 1
mese**

**Ilizarov +
esplorazione
radiale =
integro**



**A 2 mesi intolleranza
e rigidità**



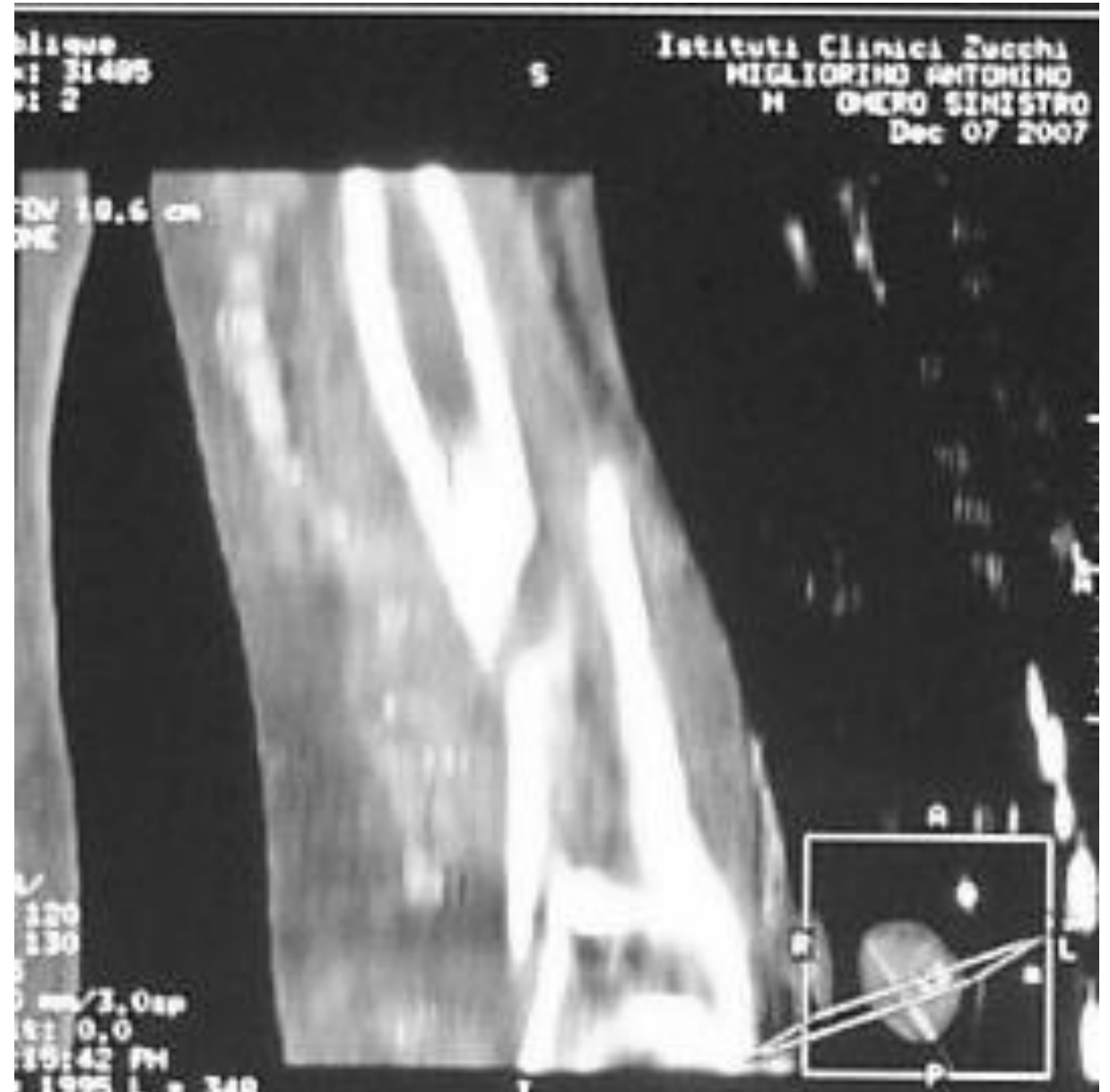

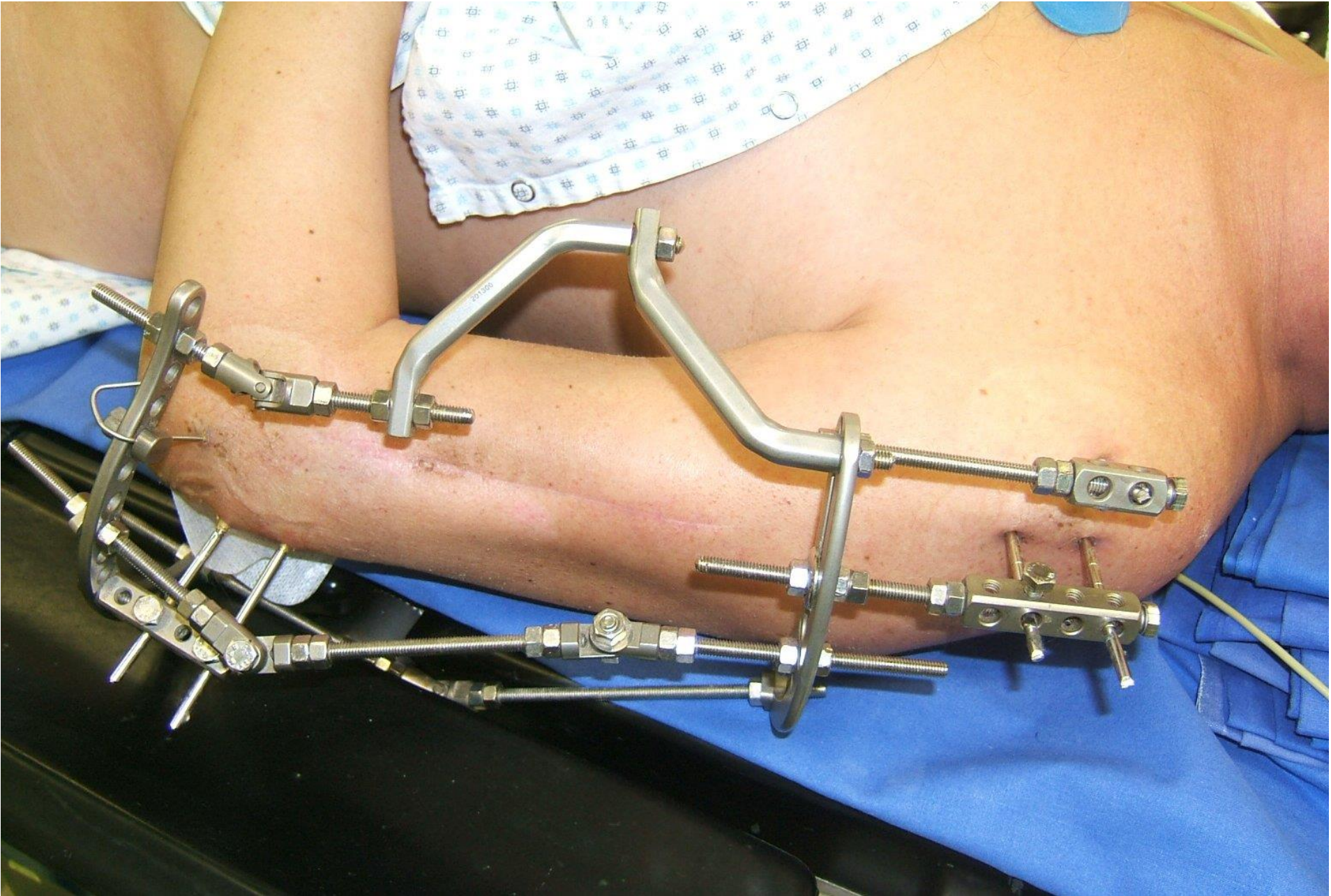
Nov 07

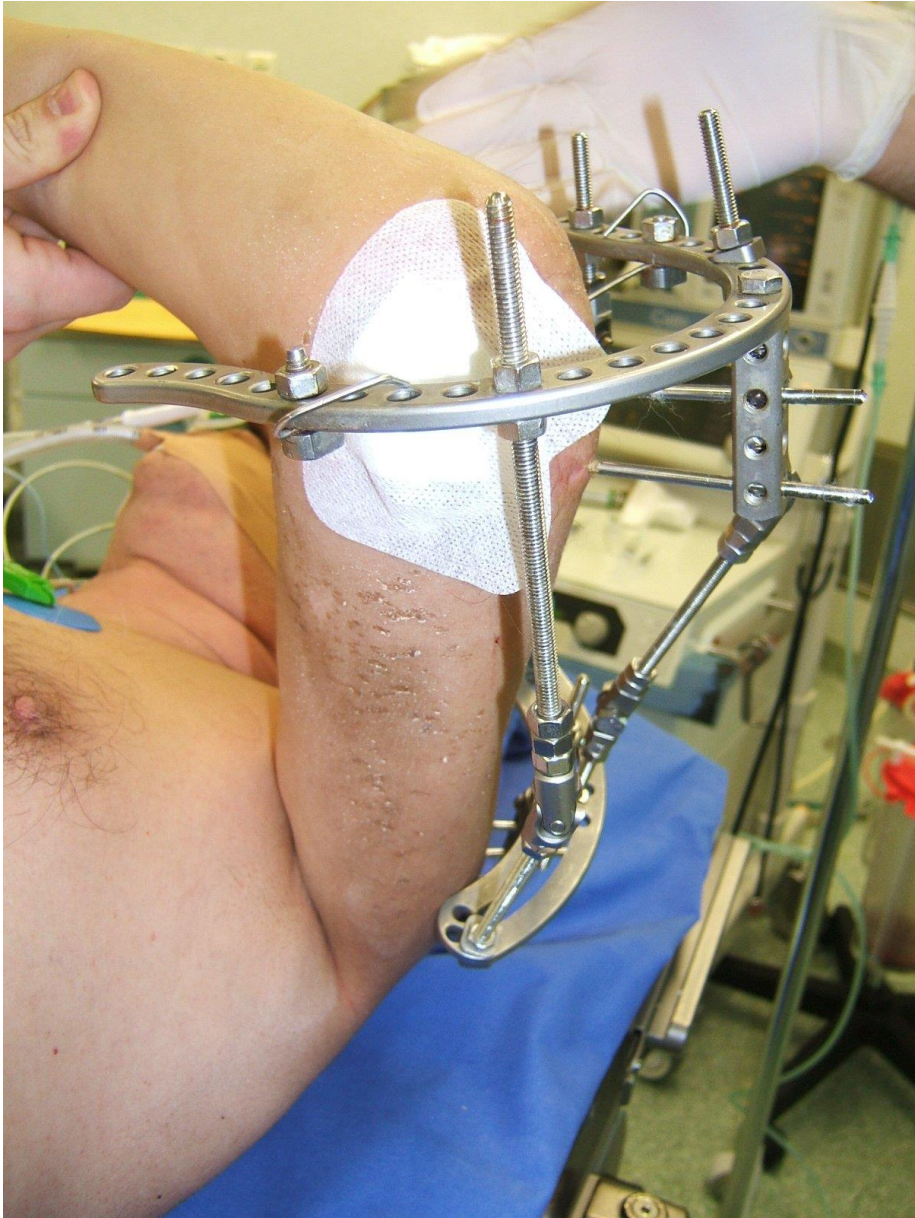
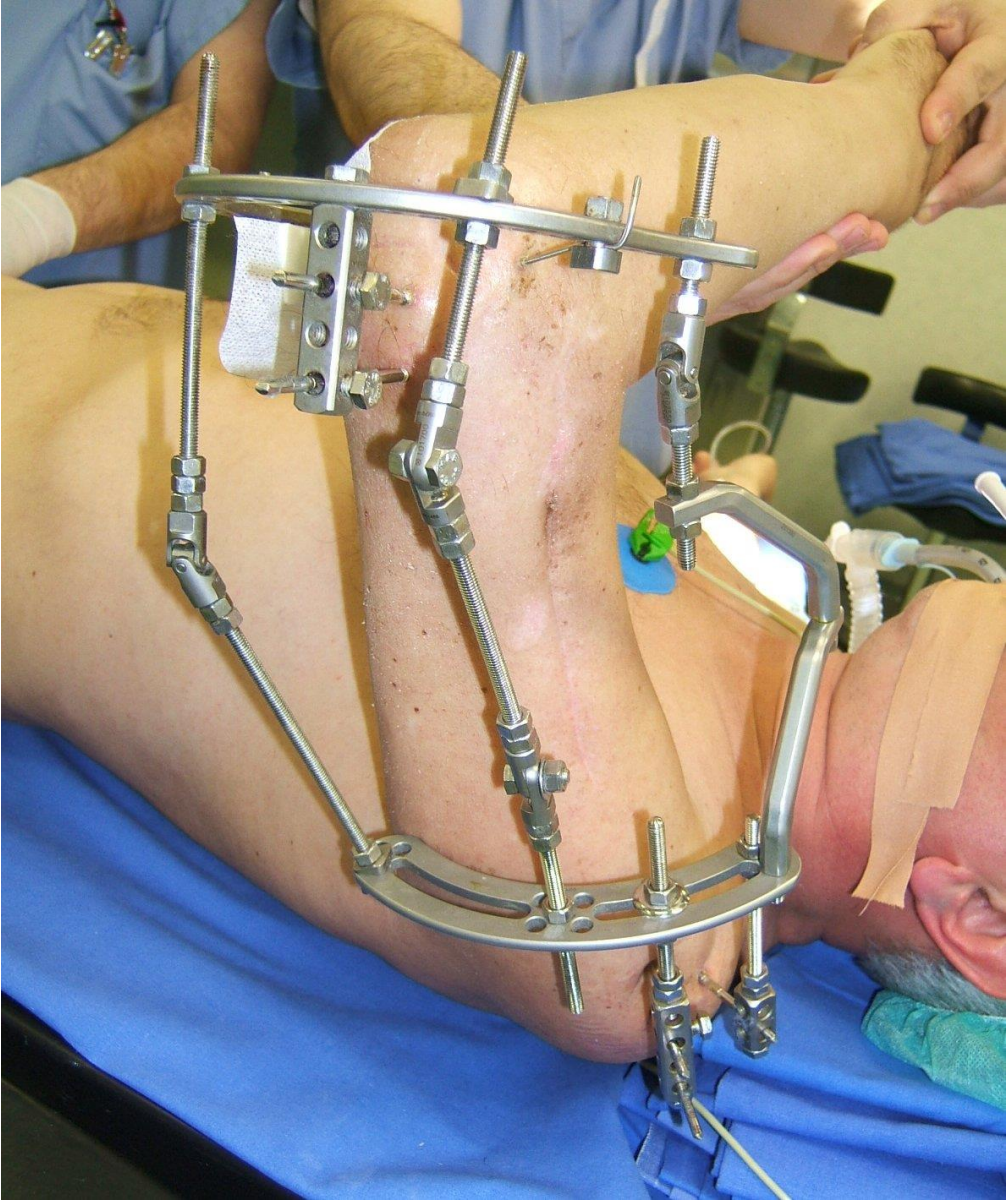
A 4 mesi

- 1. Intolleranza all'exfix**
- 2. Persiste paralisi radiale**
- 3. Spalla rigida e dolente**
- 4. Dubbio sulla consolidazione**

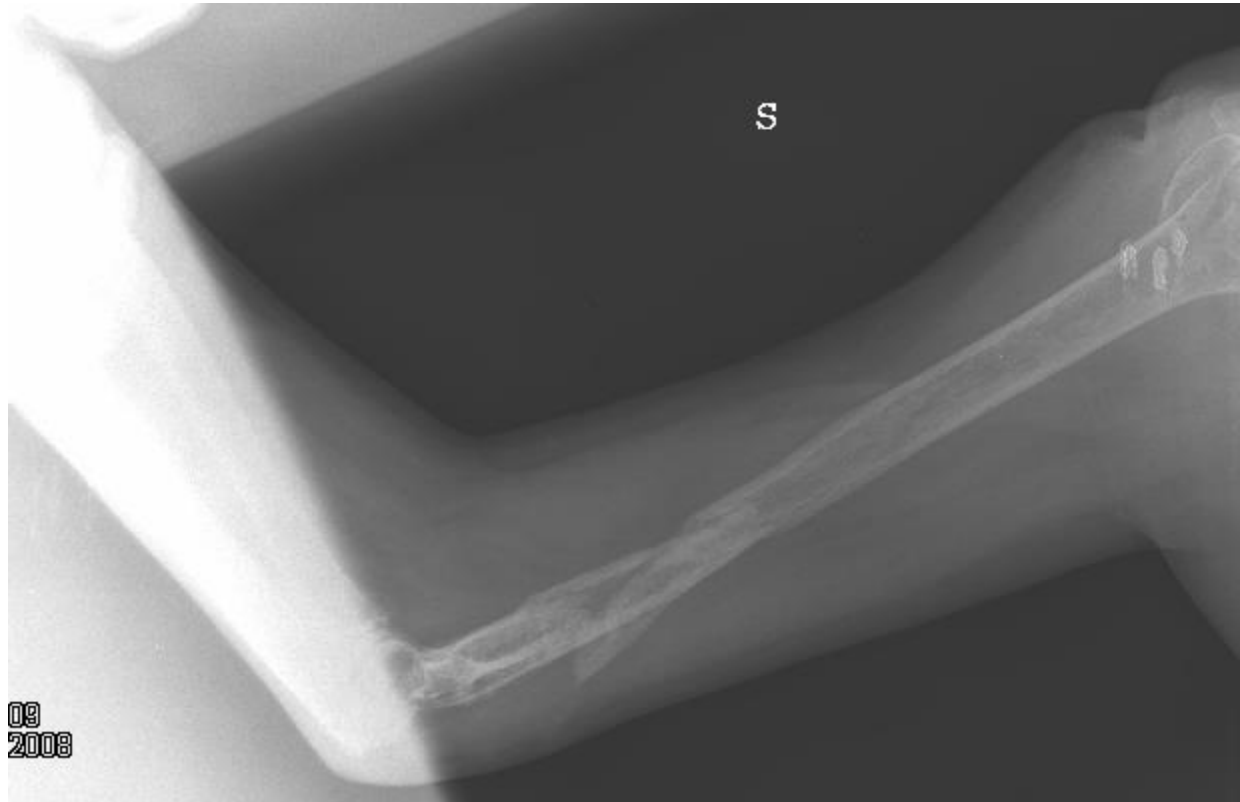
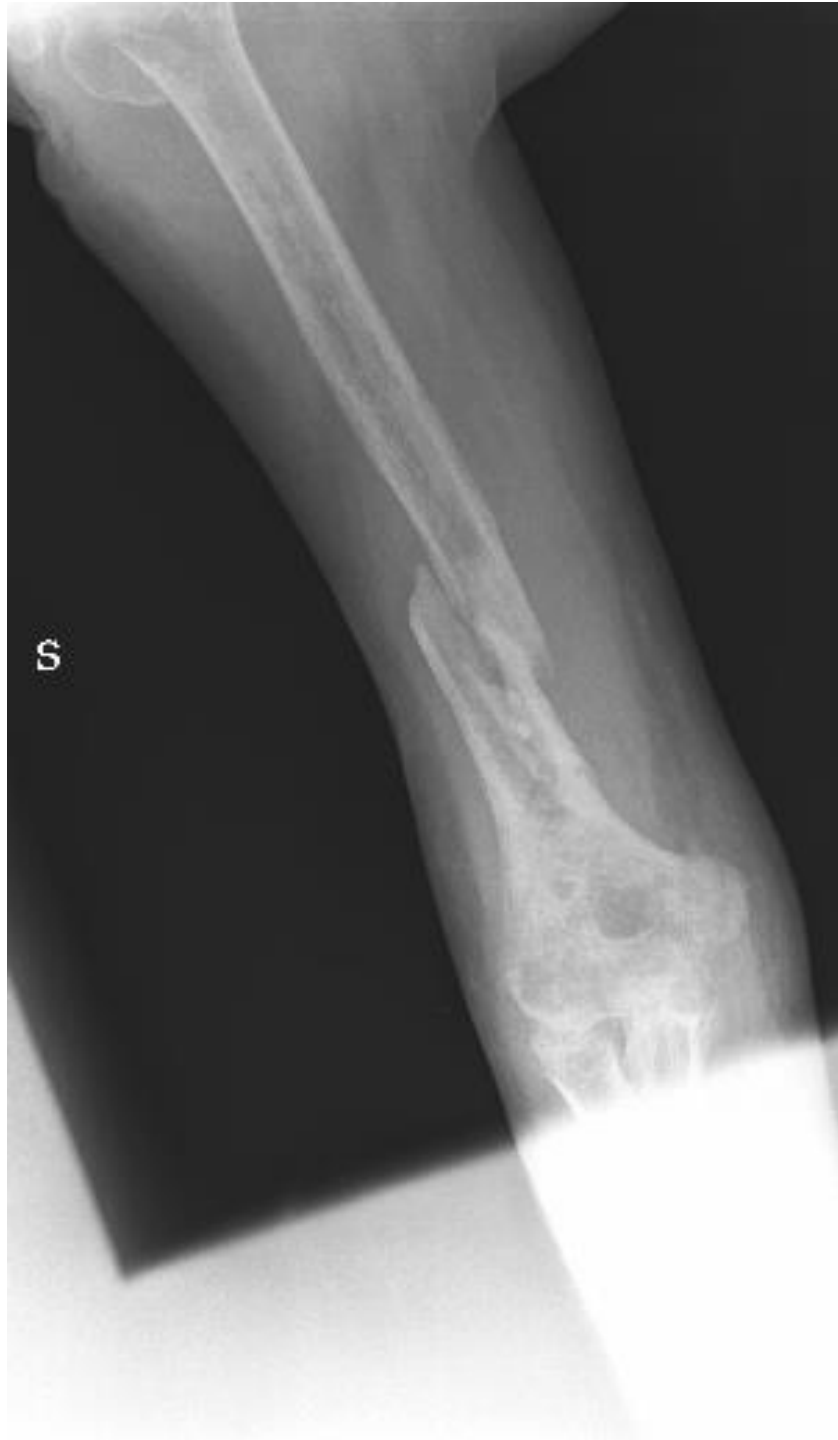TAC
Pseudartrosi
Spalla e gomito
rigidi

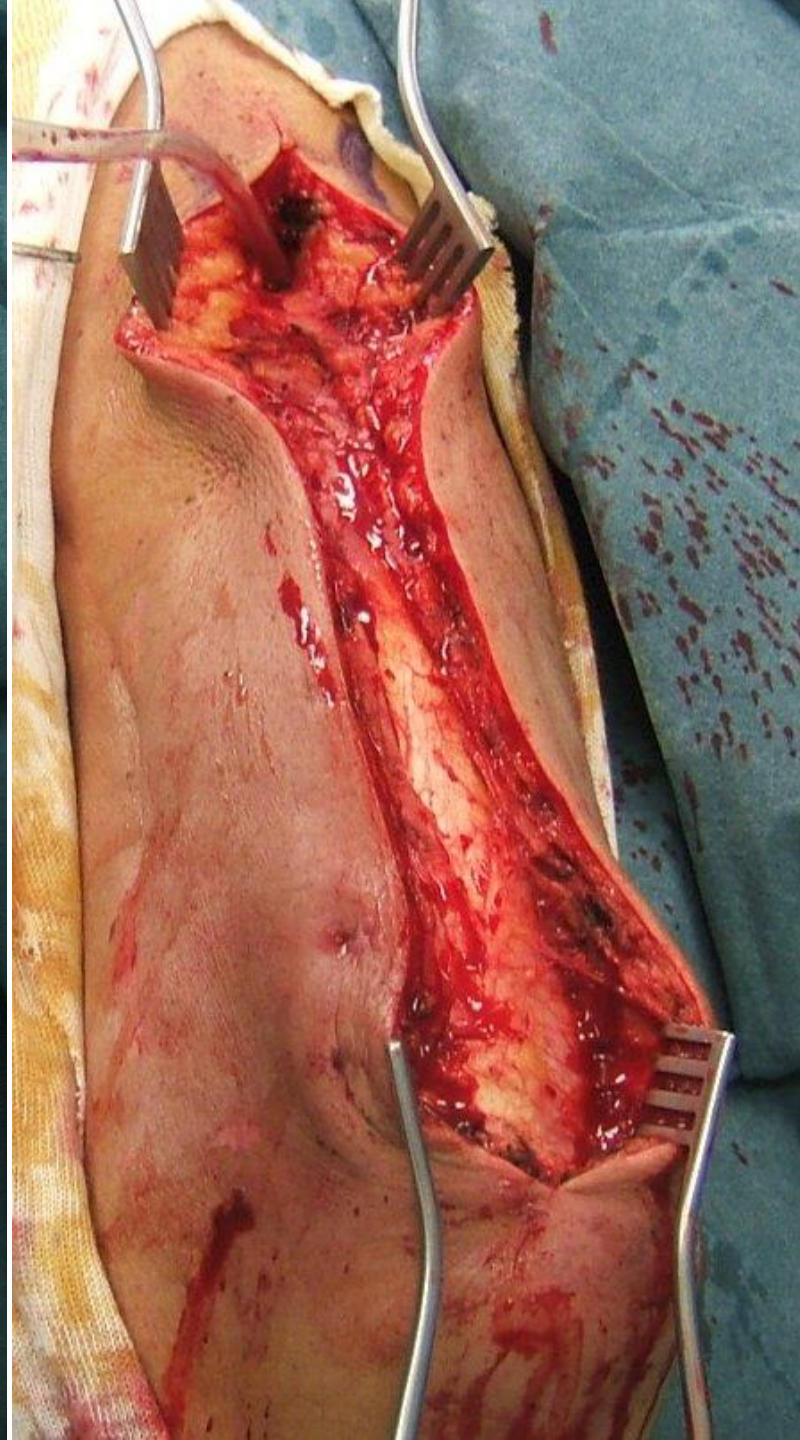
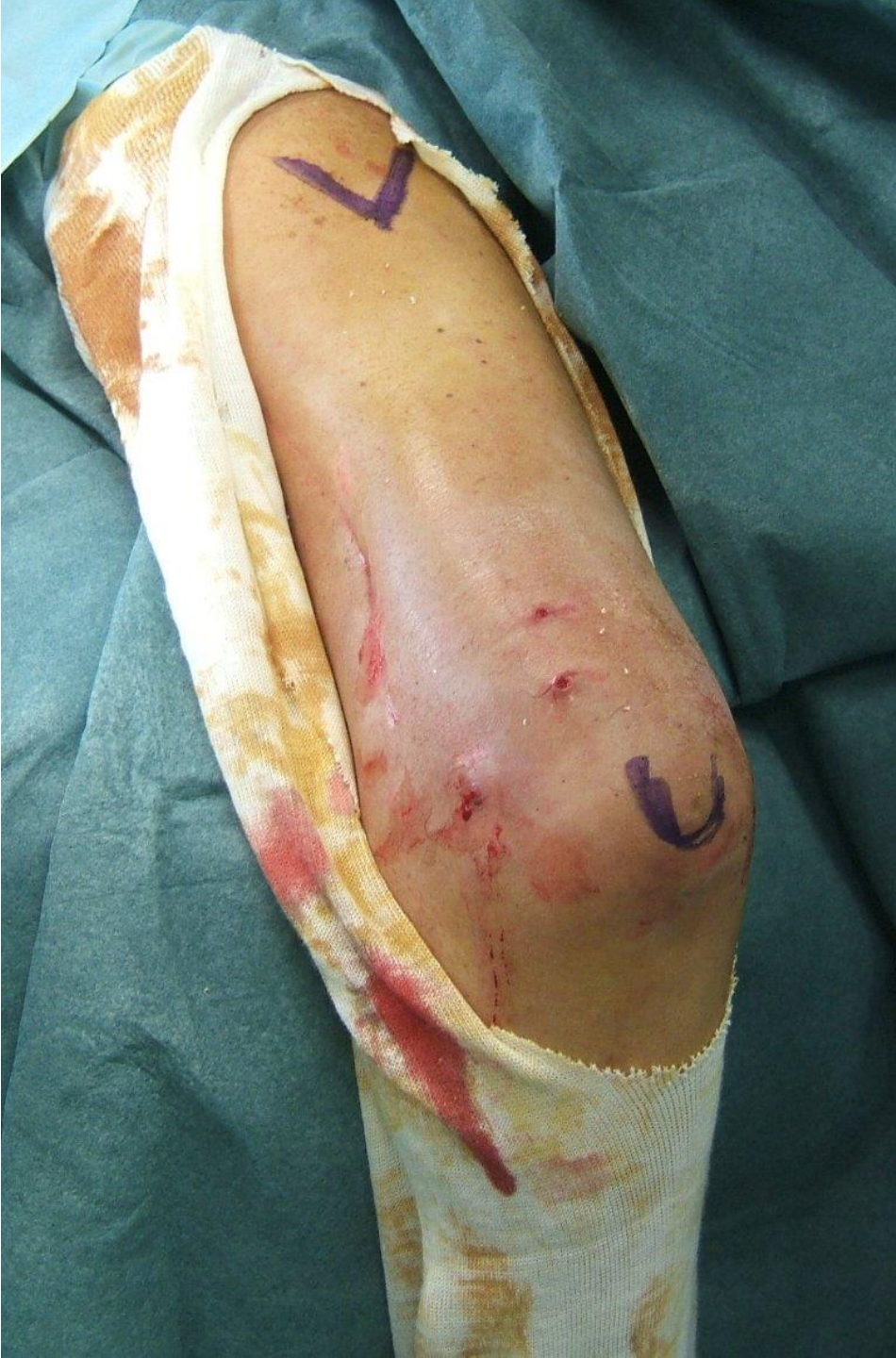
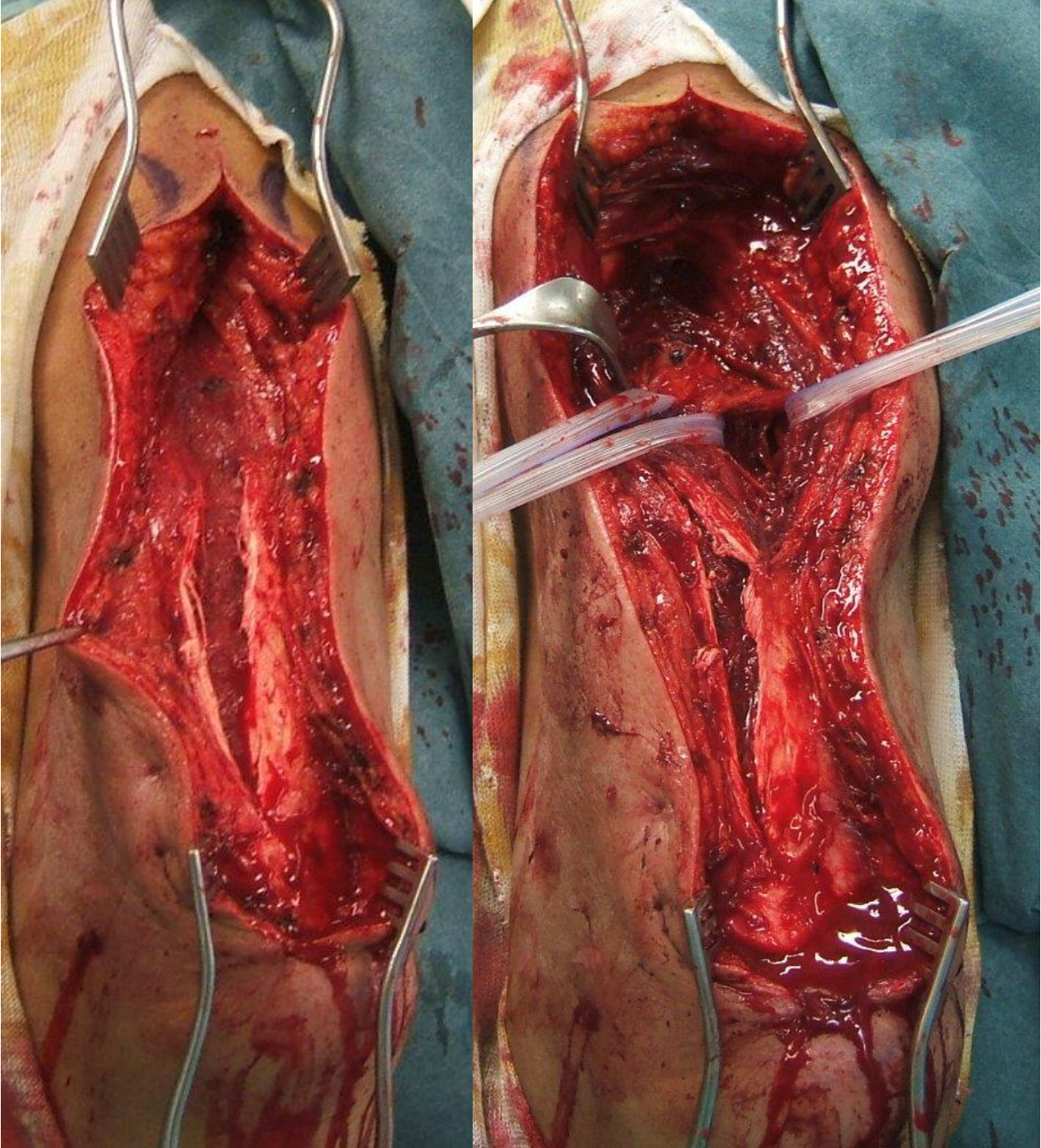


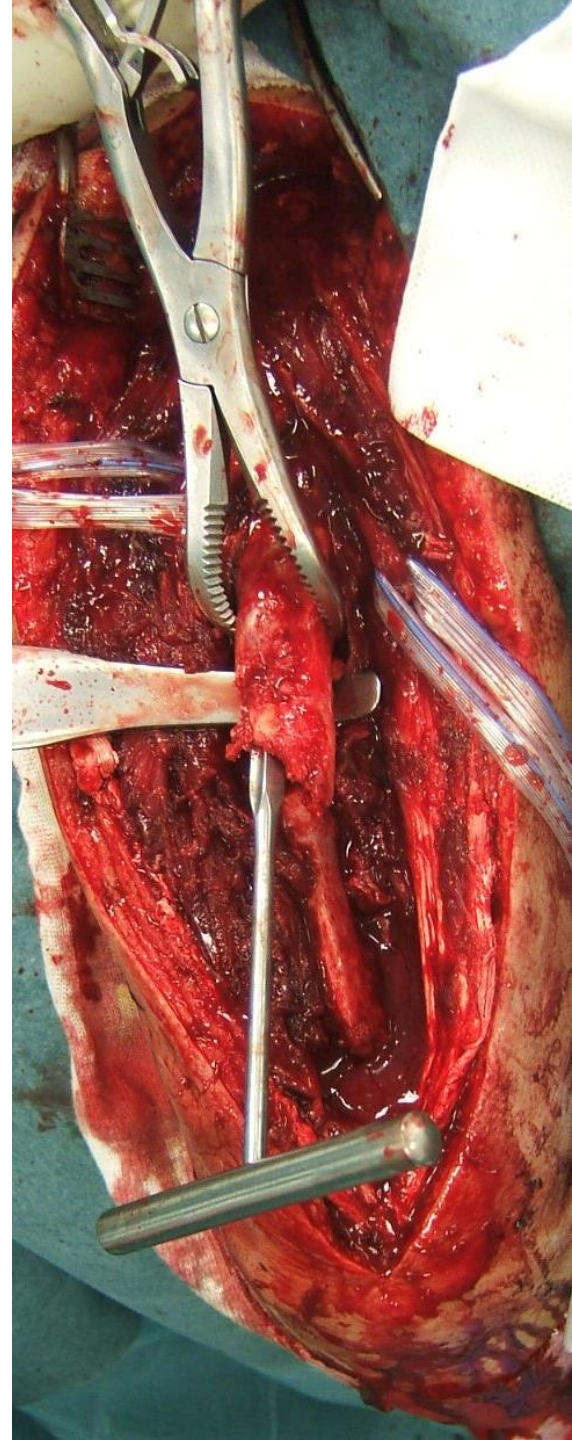
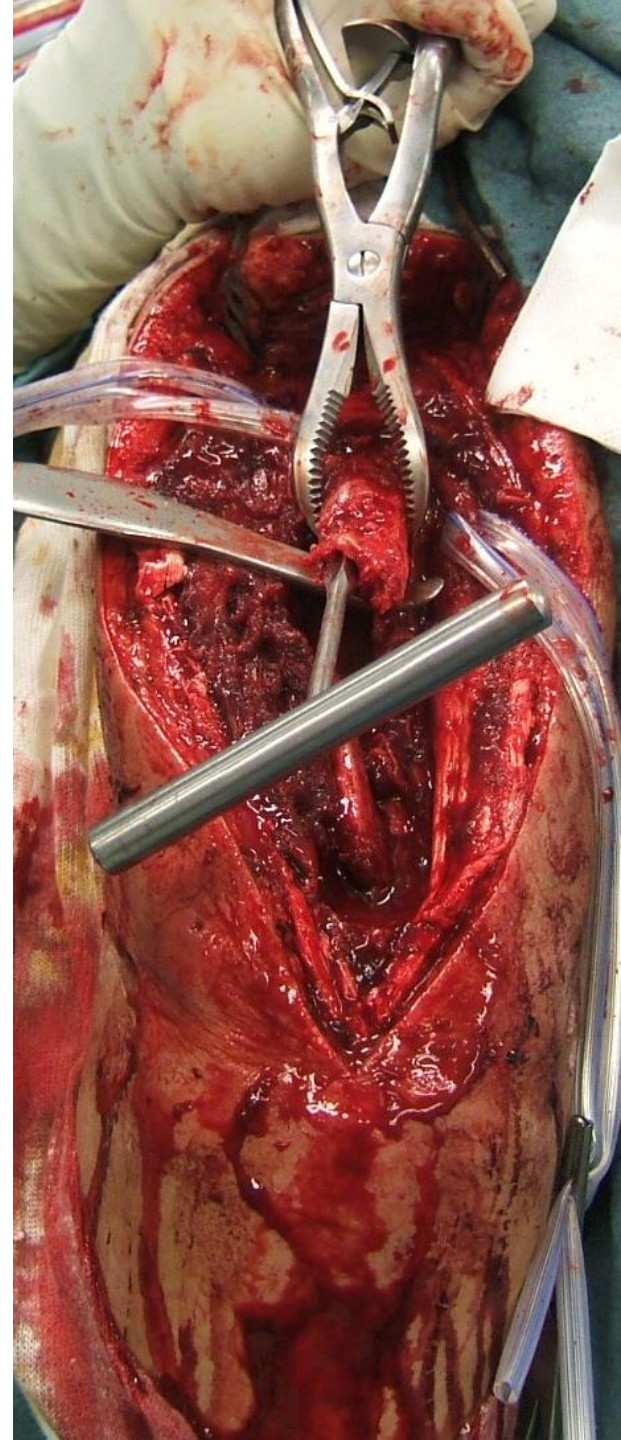


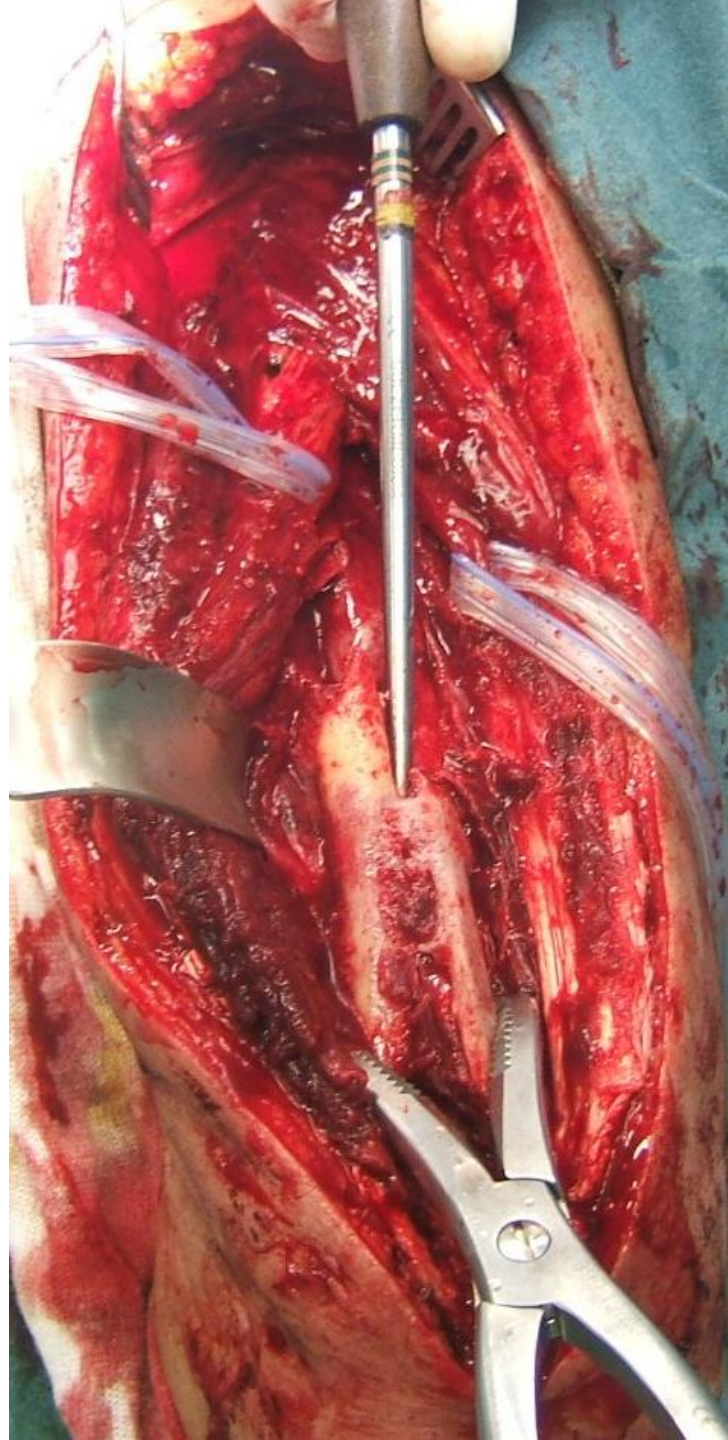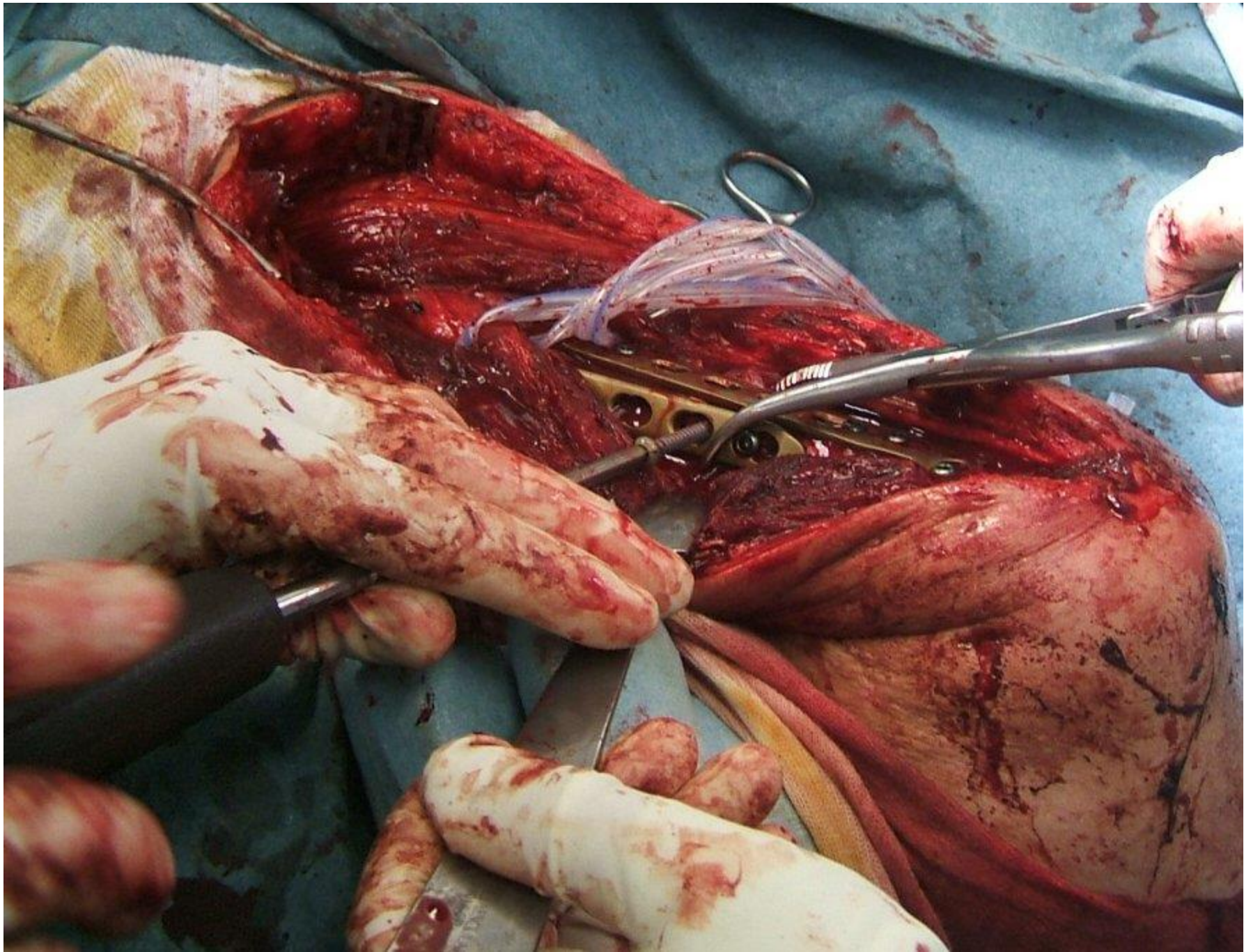
Pseudartrosi atrofica

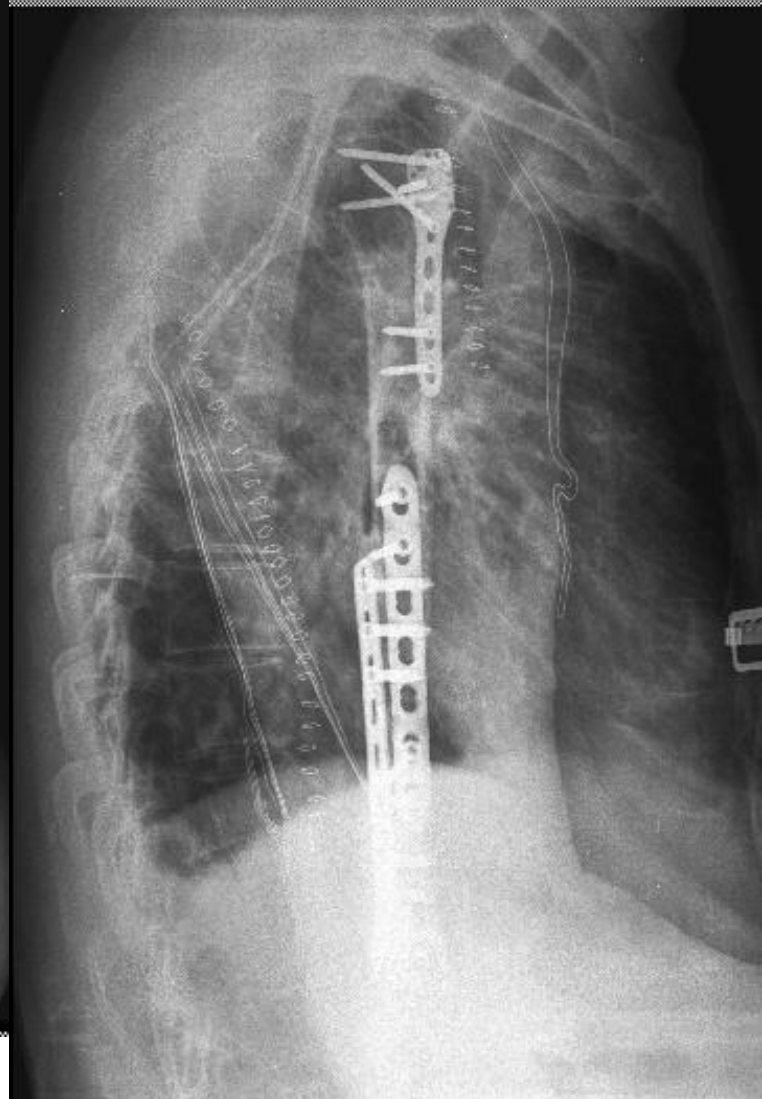
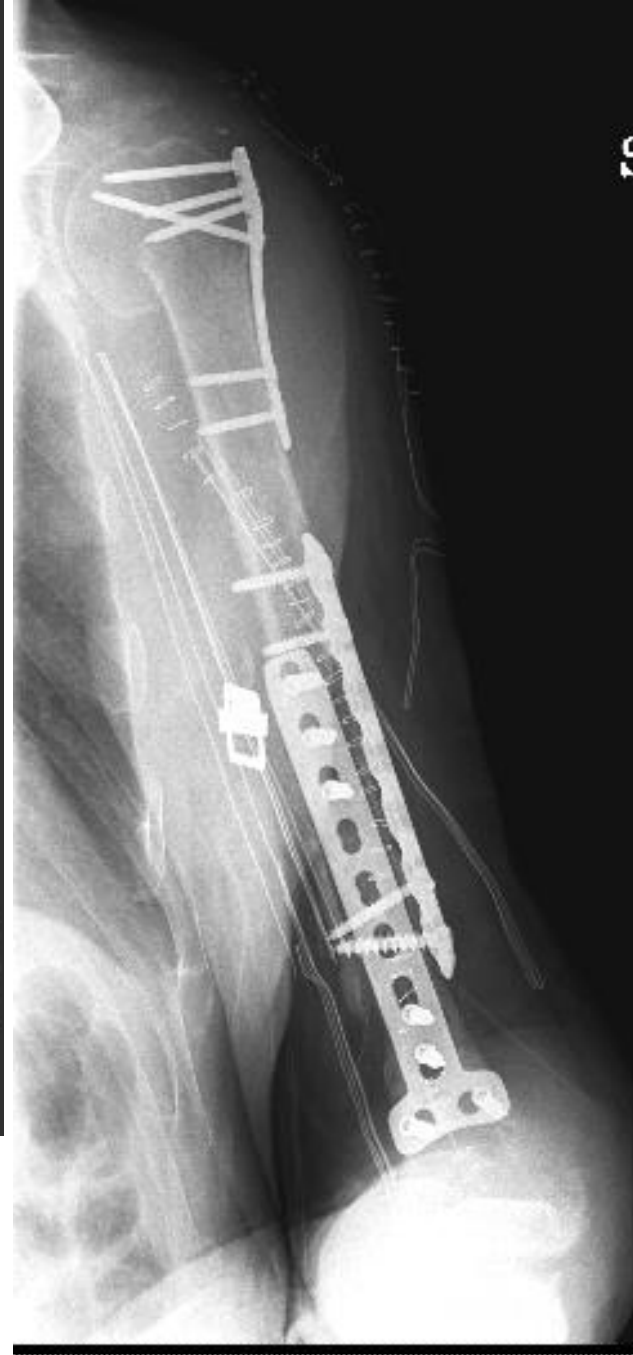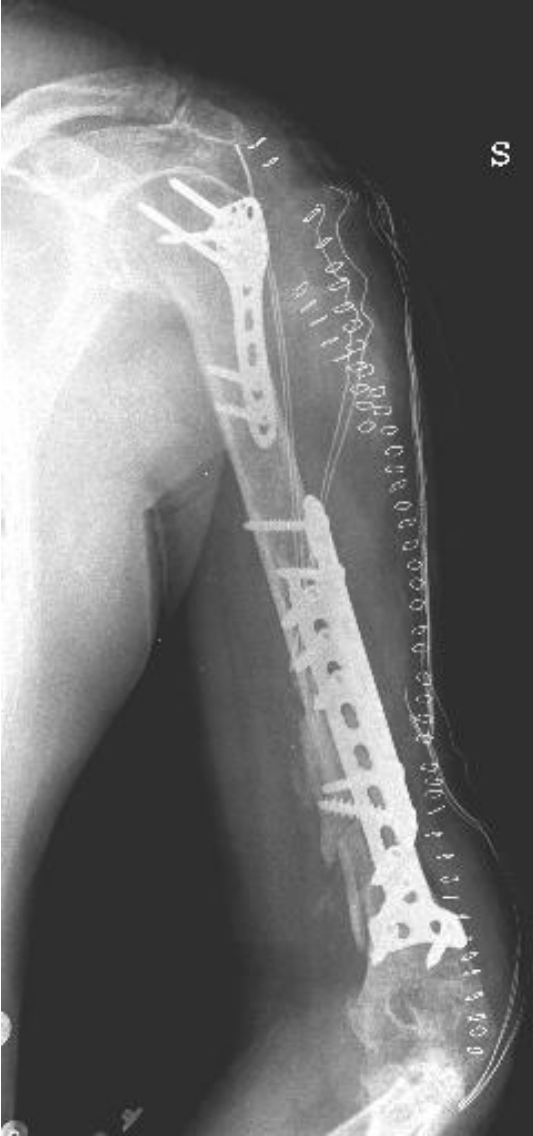


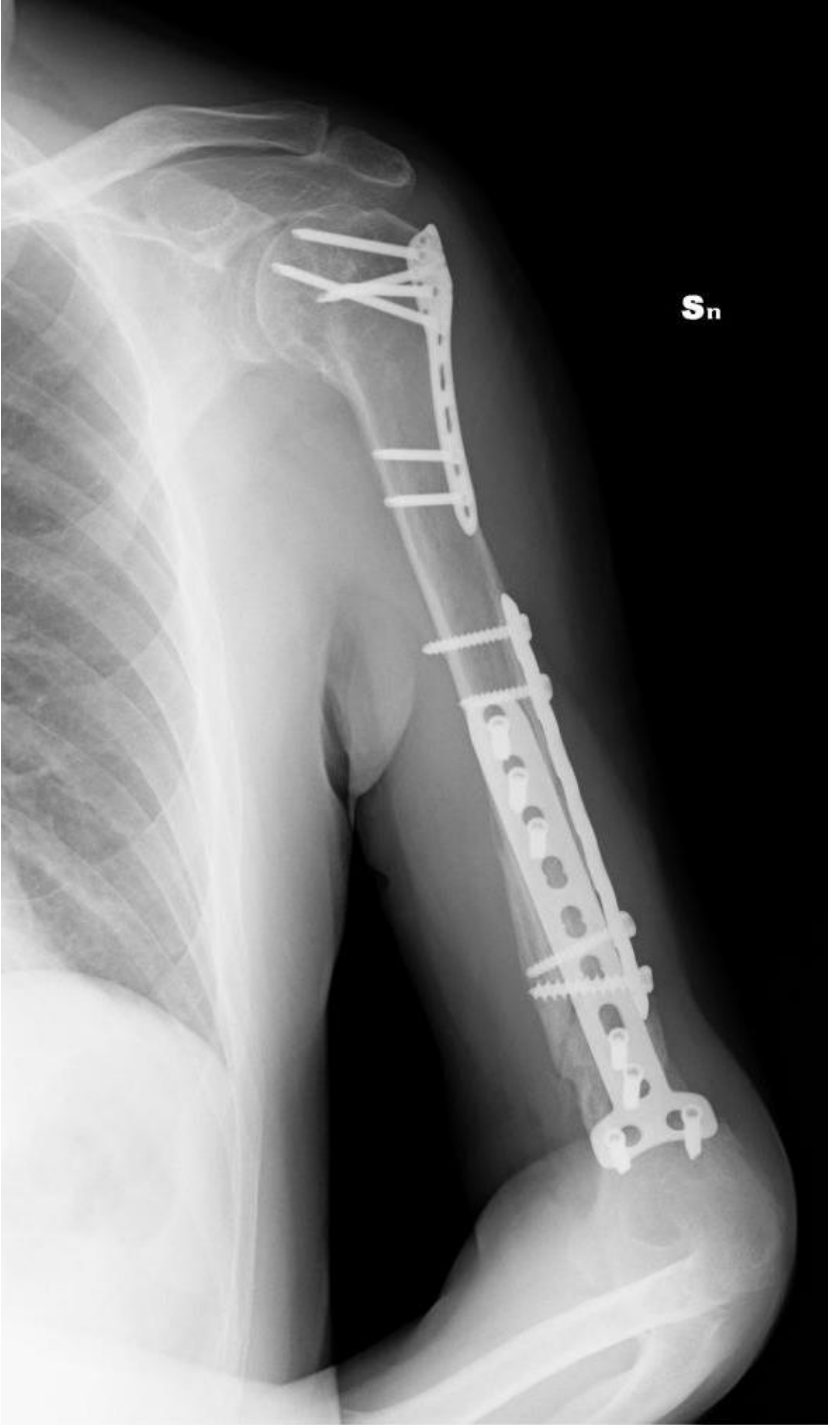







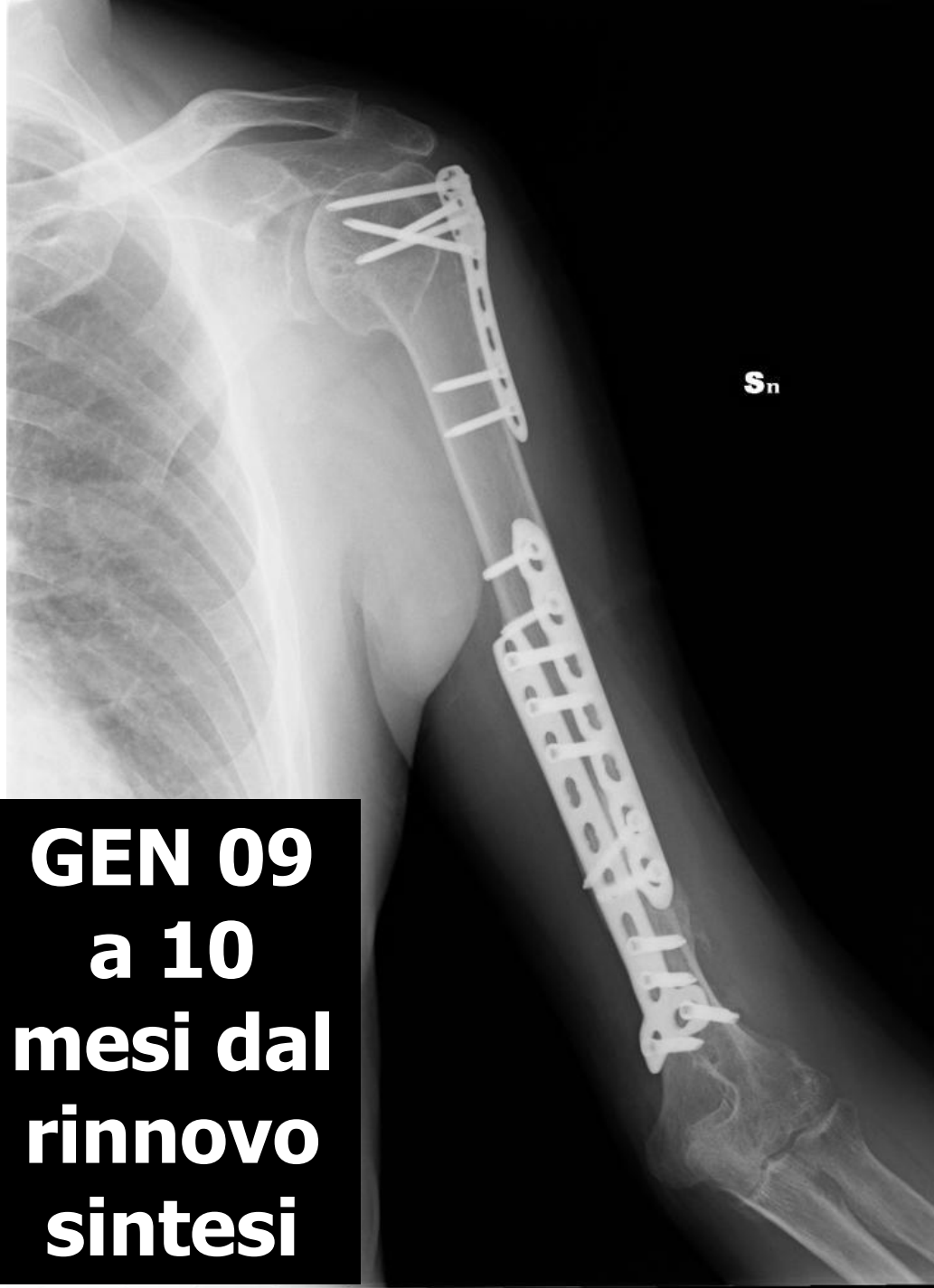




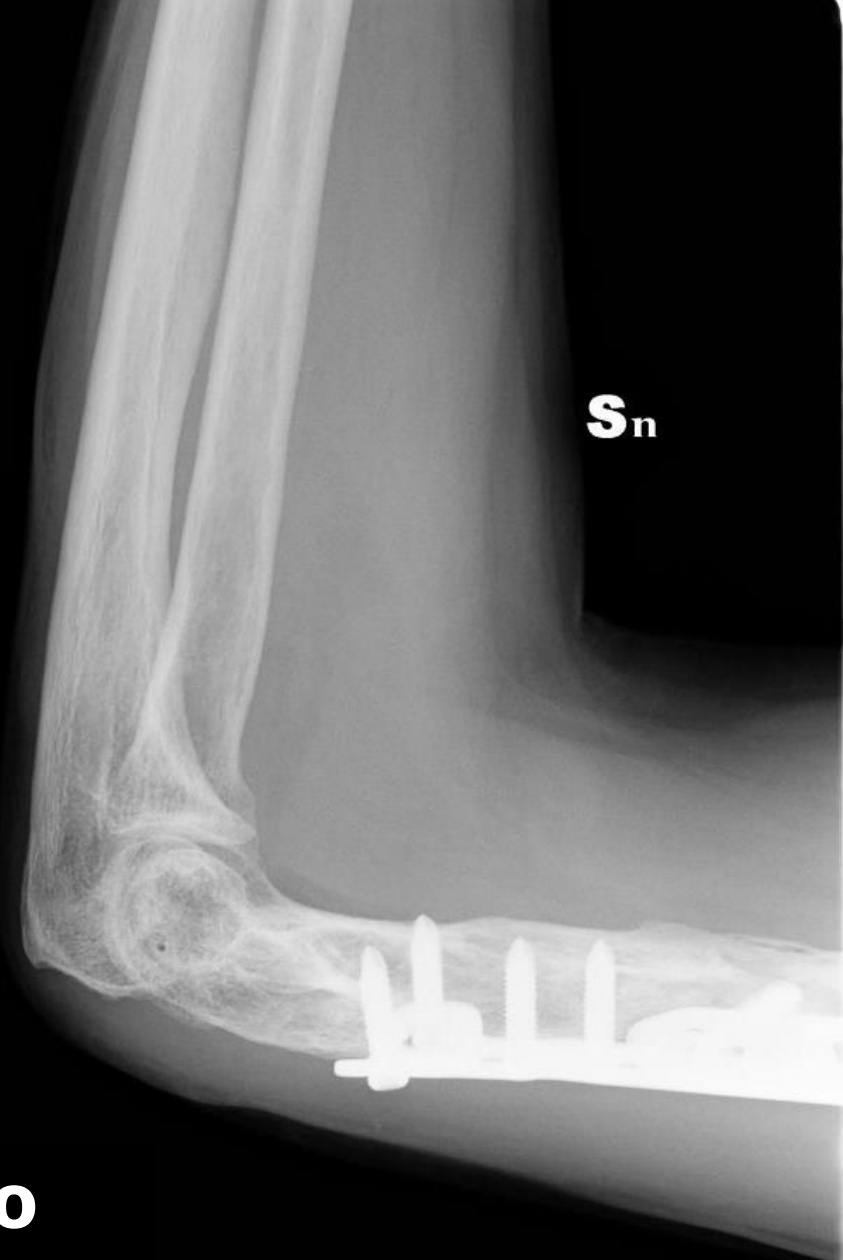
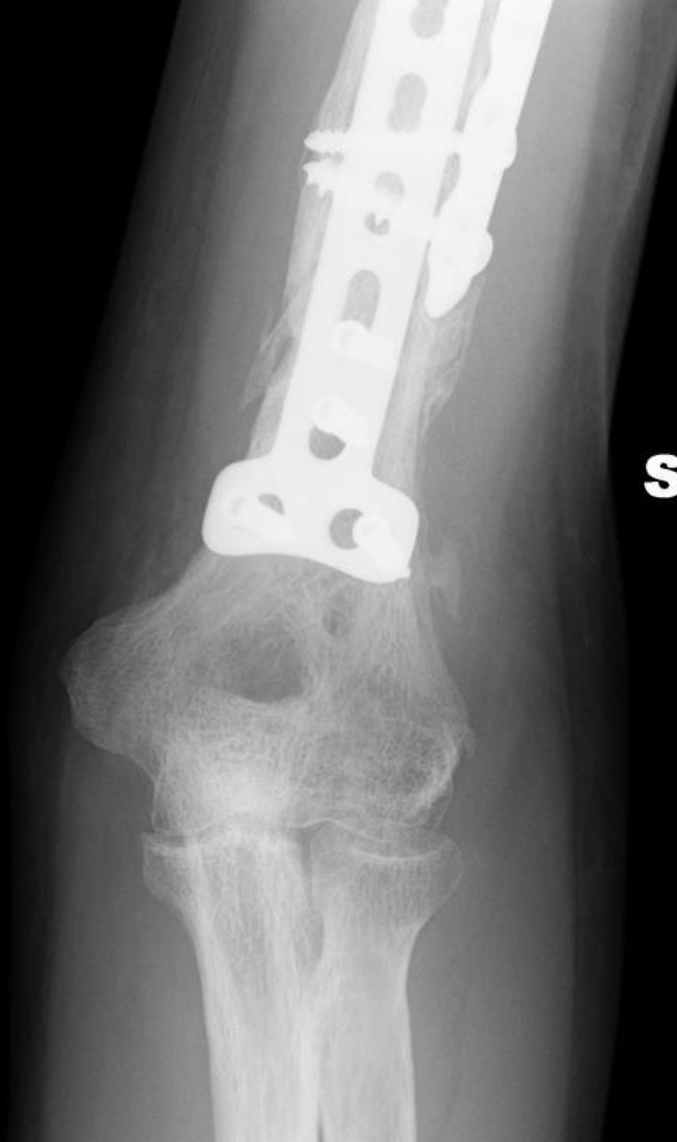S_n

**GEN 09
a 10
mesi dal
rinnovo
sintesi**



S_n

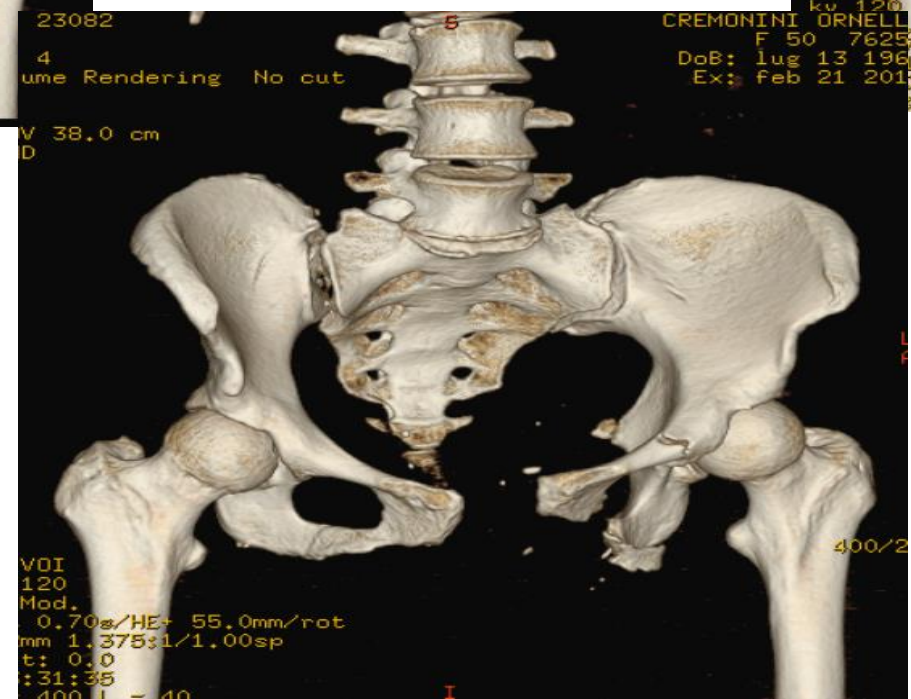
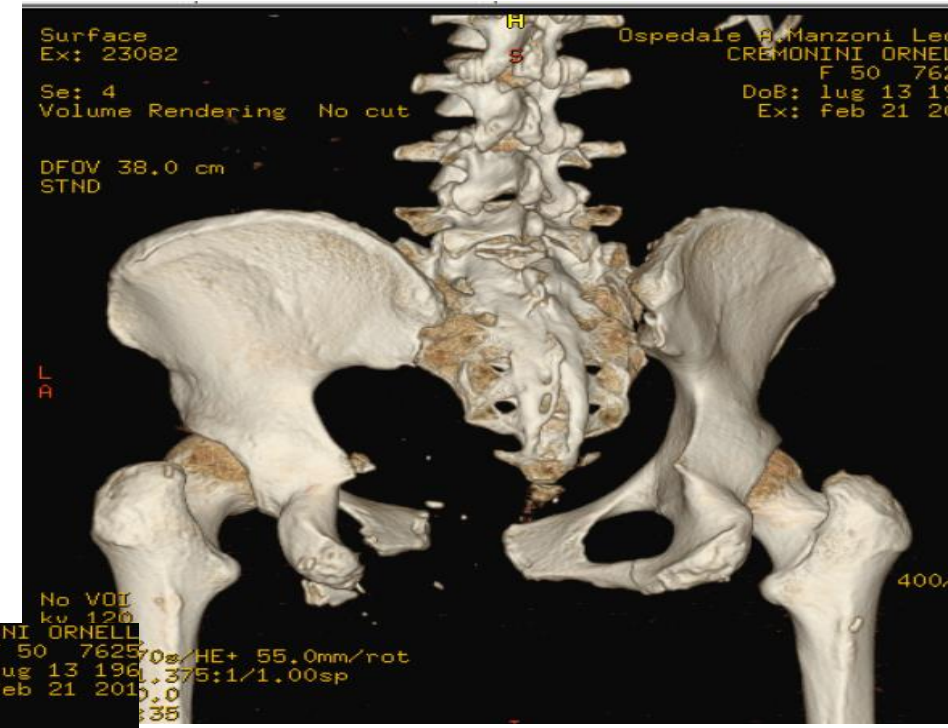
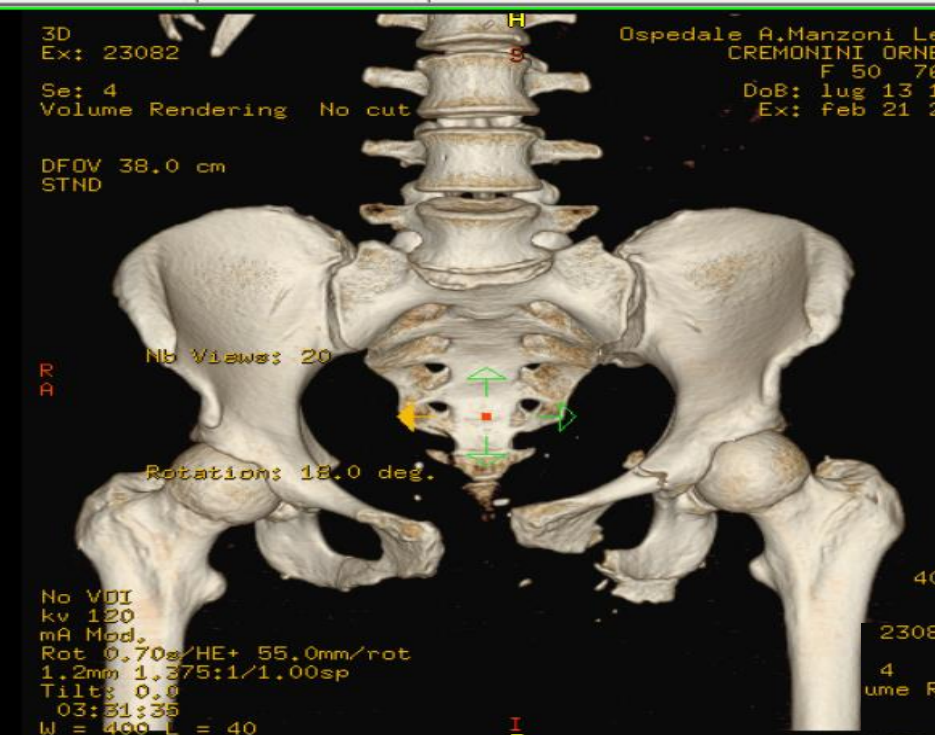


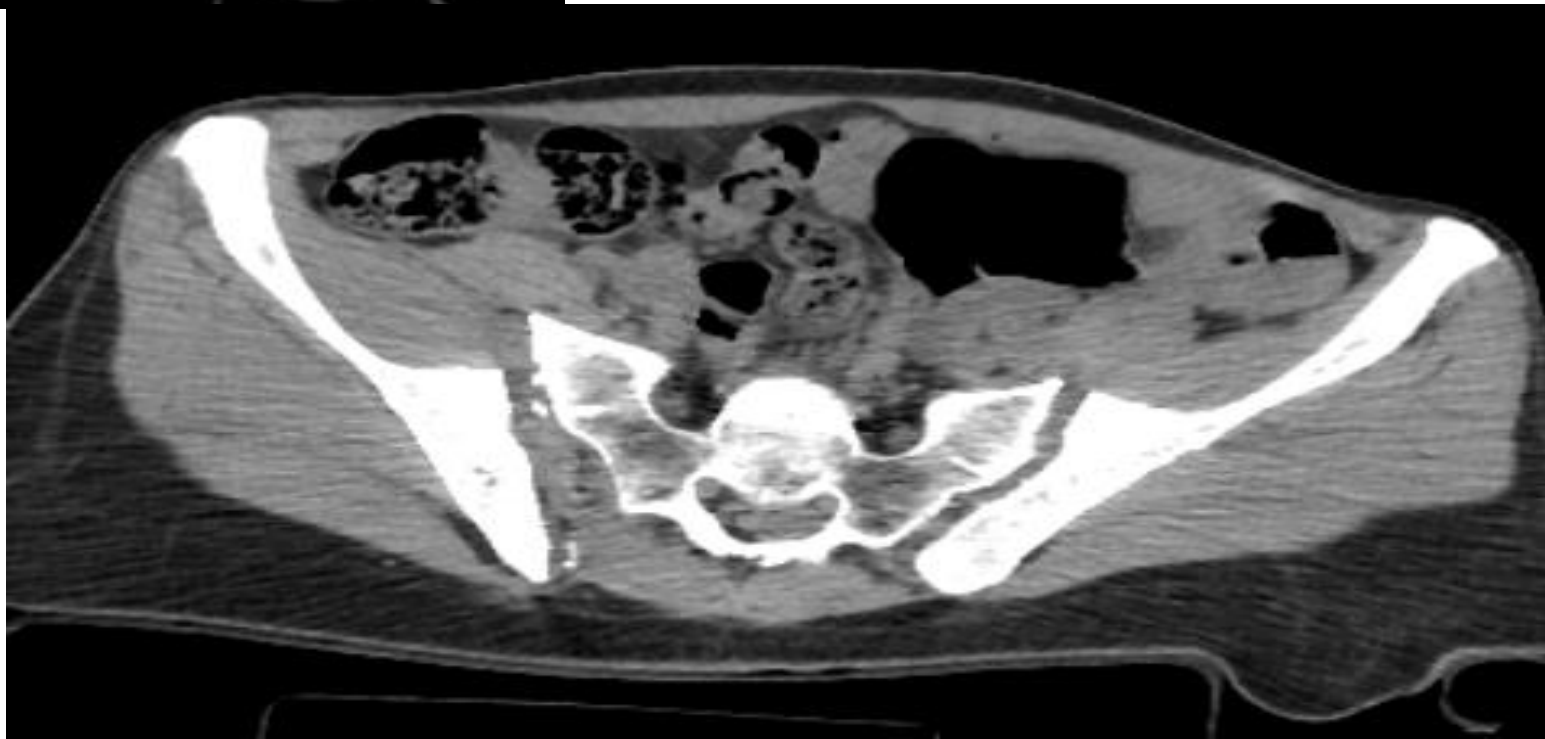
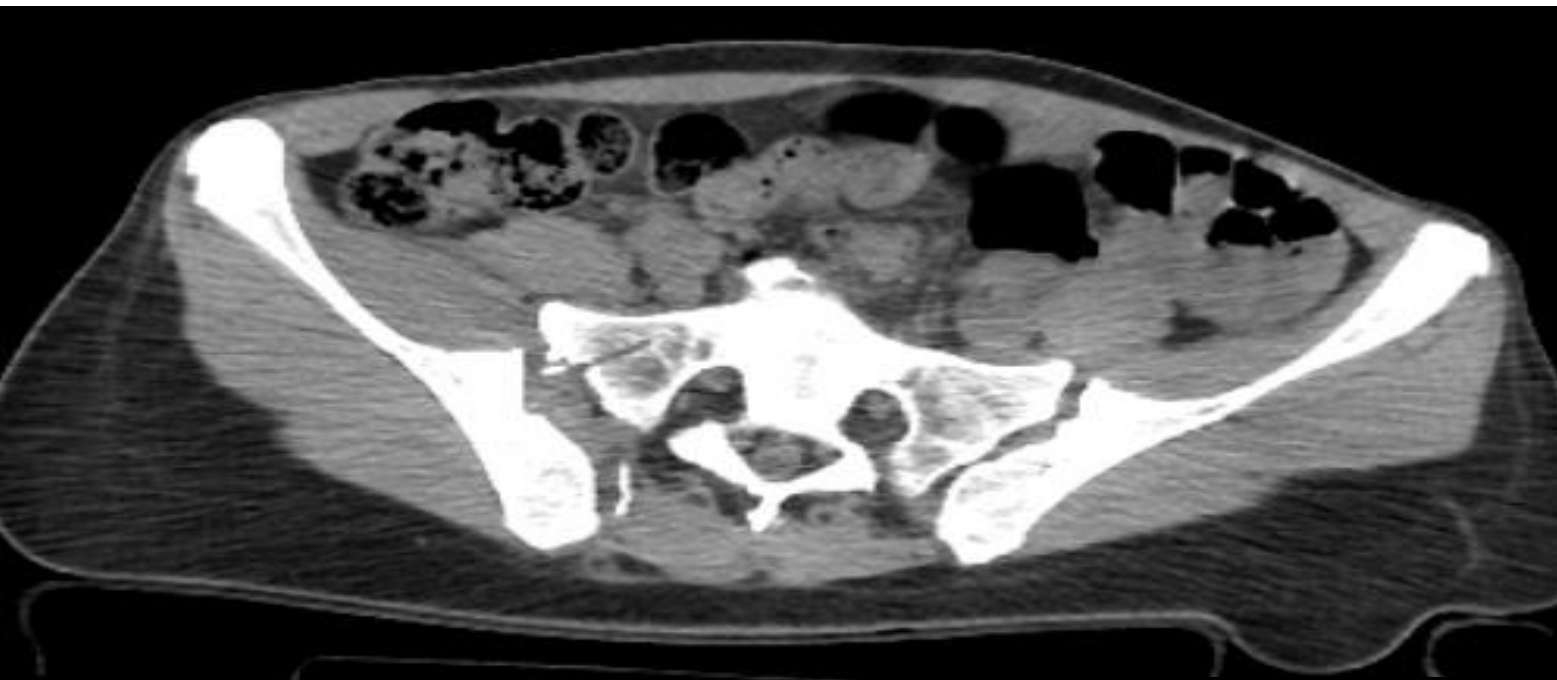
**Mobilità di spalla e gomito
completa + ripresa completa
del n. radiale**

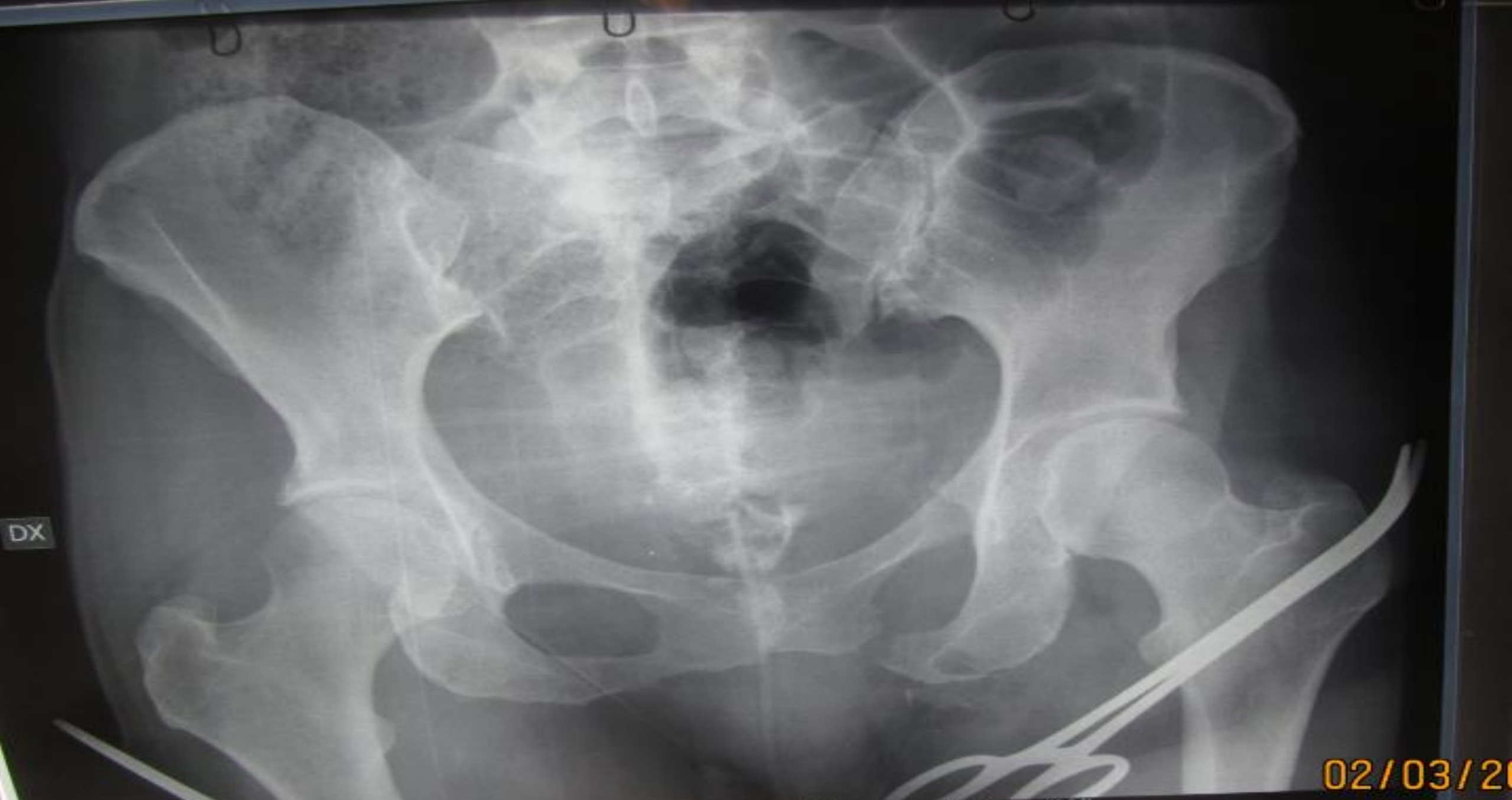**Riduzione e stabilità devono consentire la
mobilizzazione precoce
ANCHE
Con l'»apparato»**

Diagnosi

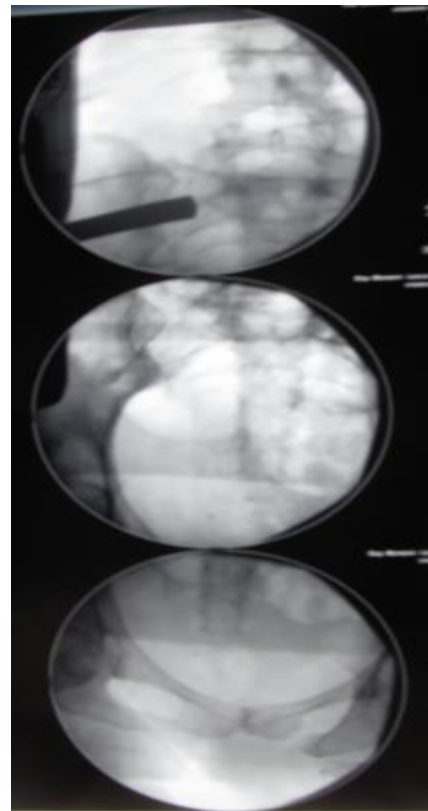
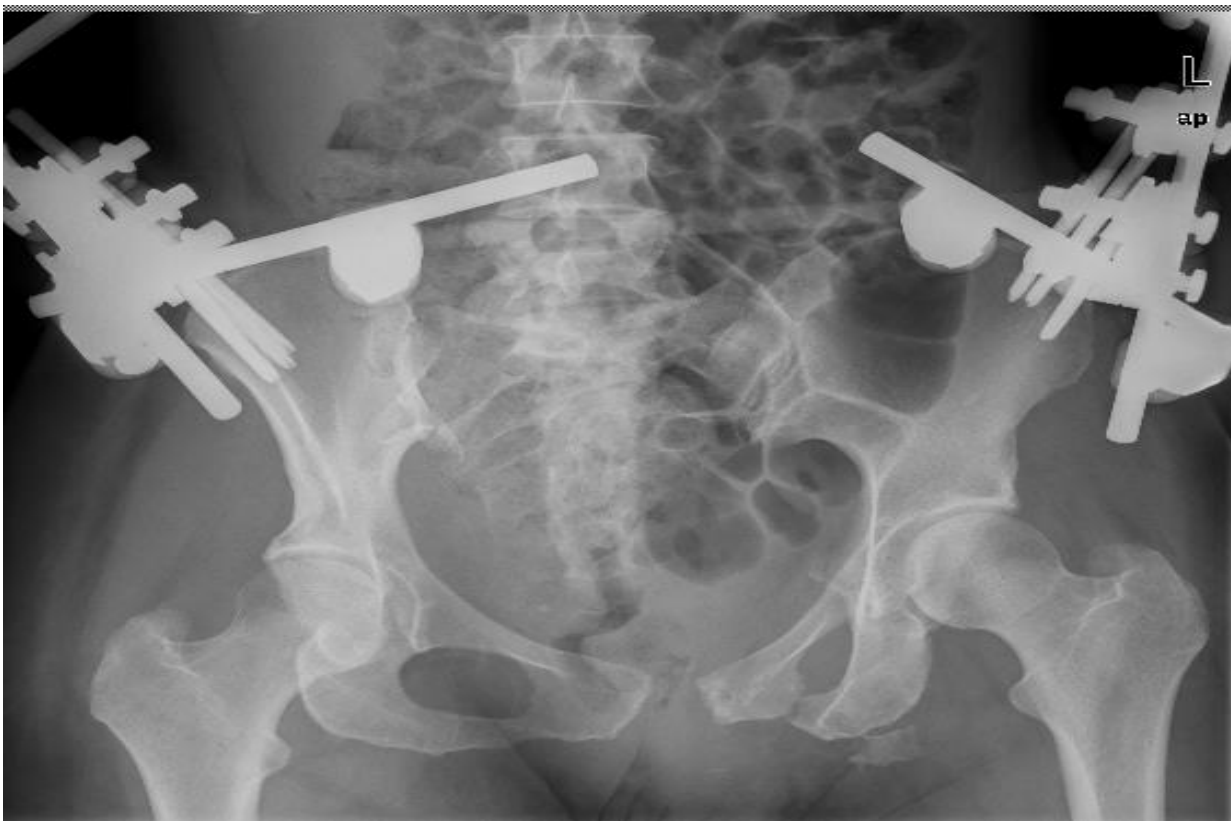
Donna aa 51 marzo 2014 incidente MACCHINA IN DISCESA FRENO A MANO MESSO MALE



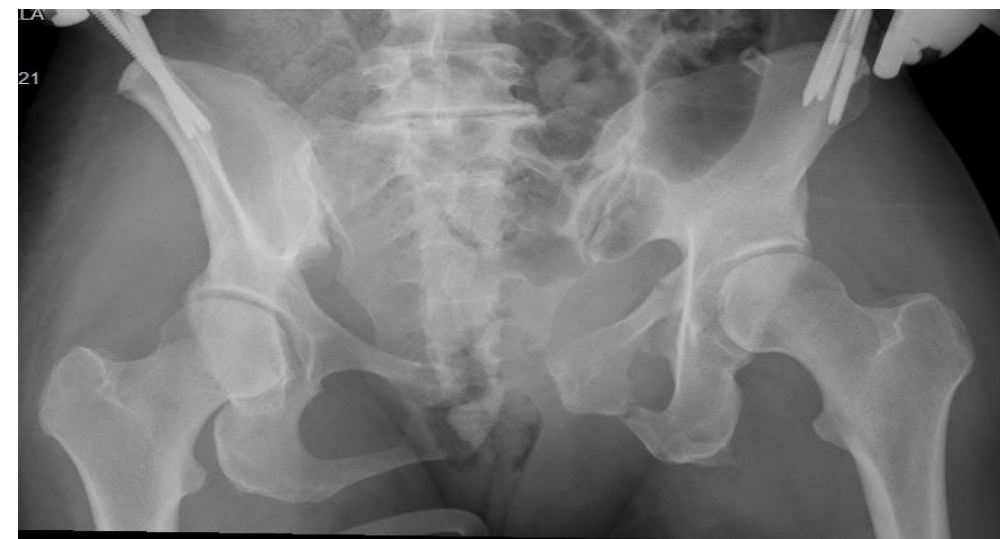
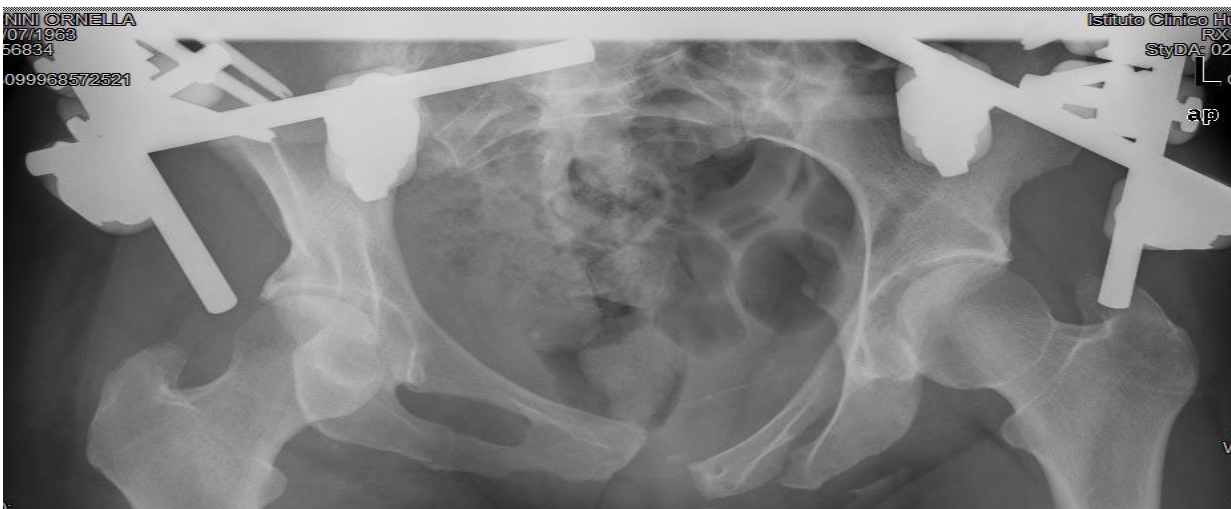

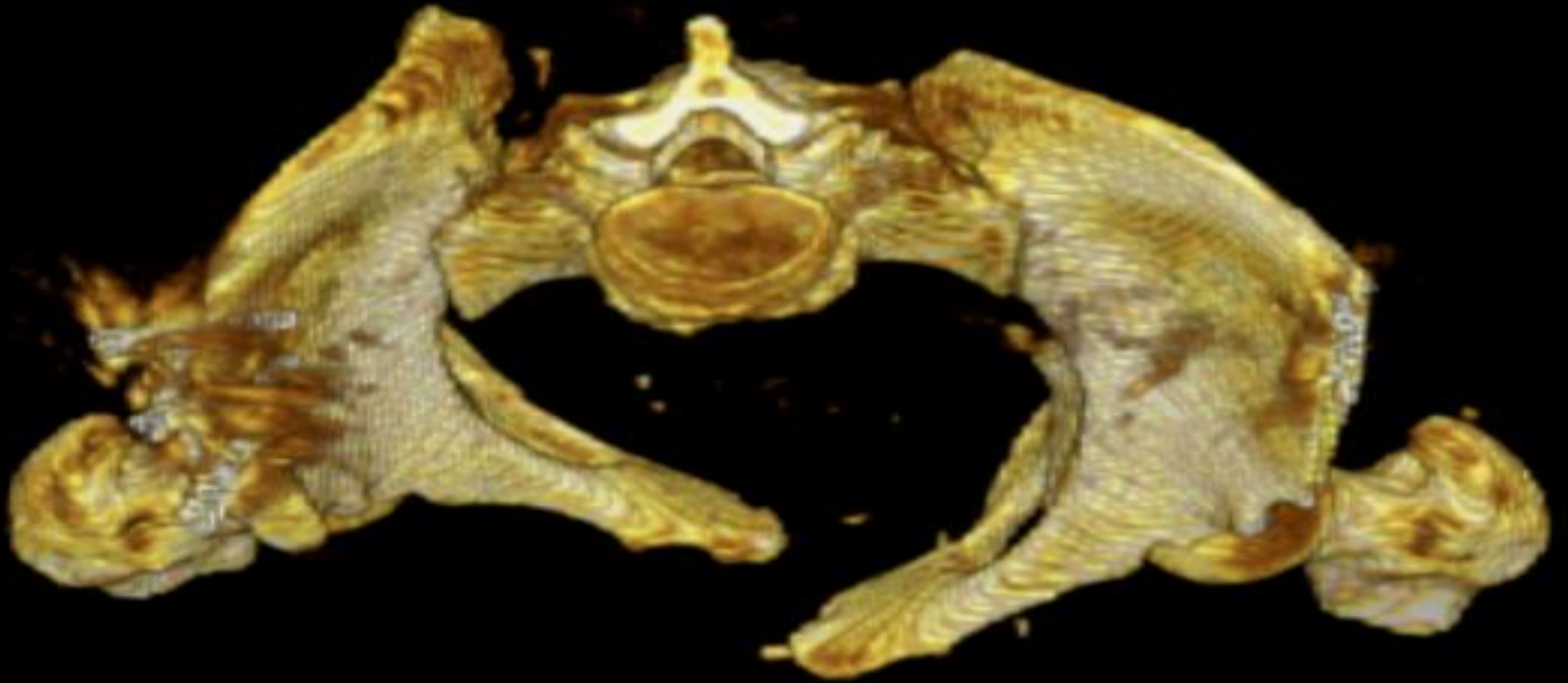


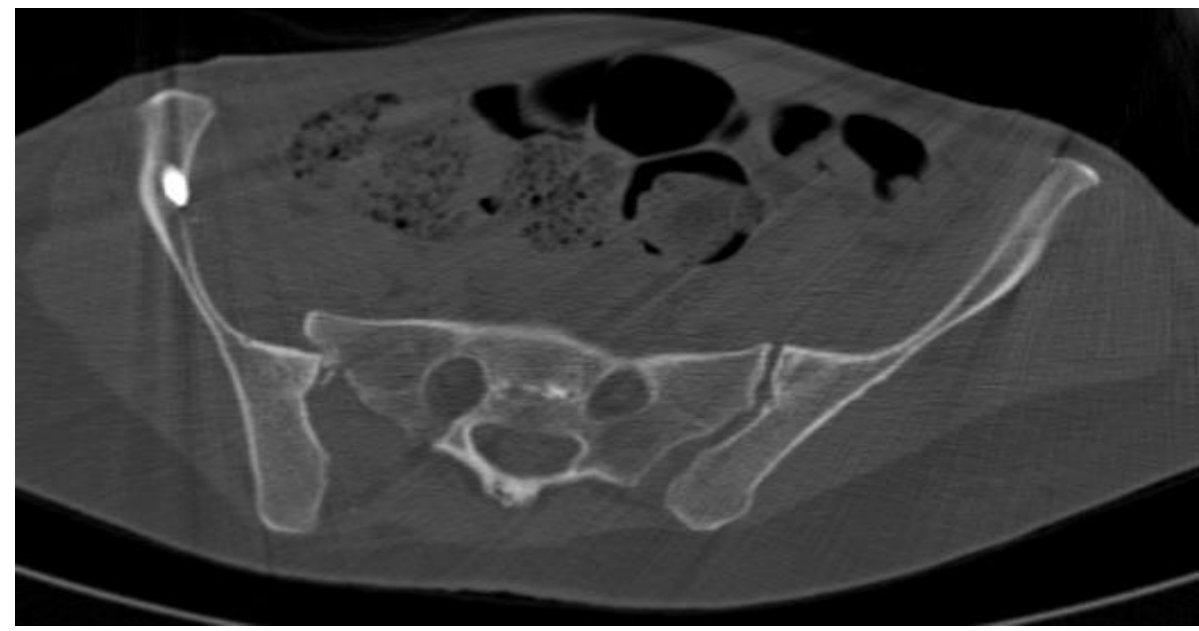
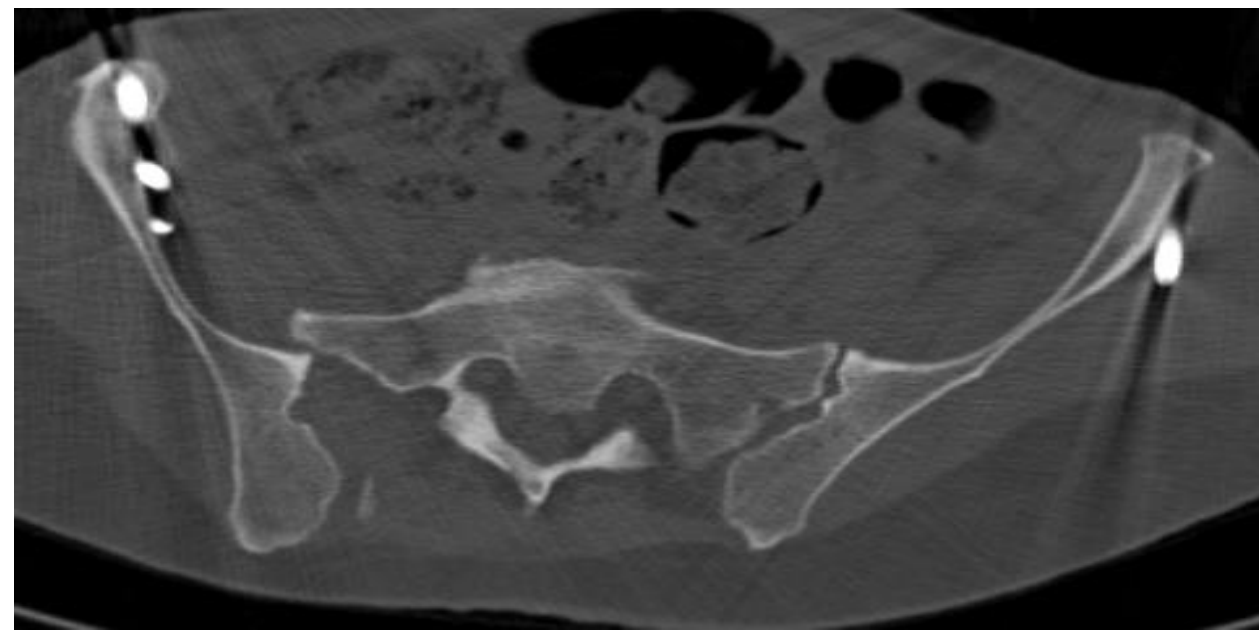
Ospedale 1: instabilità emodinamica - In urgenza lenzuolo



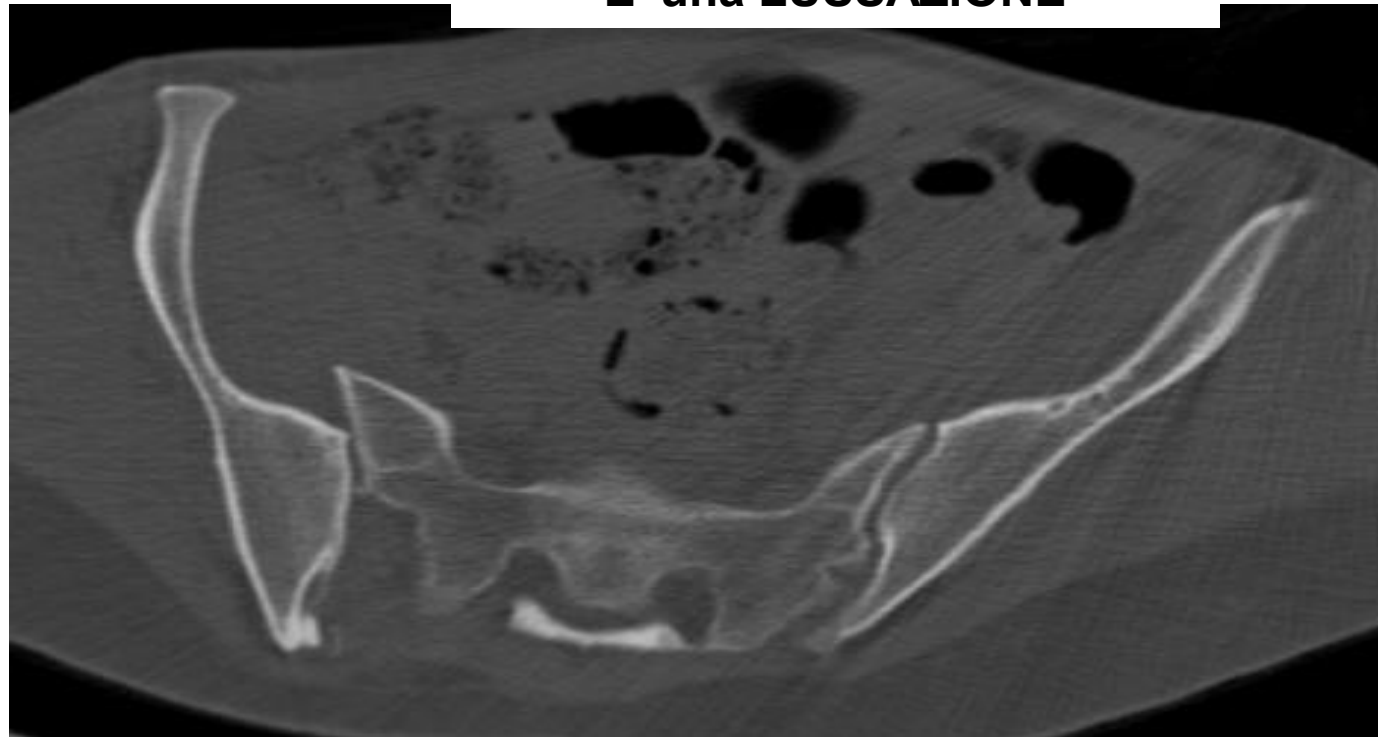
Dopo 2gg riduzione (?) ed exfix





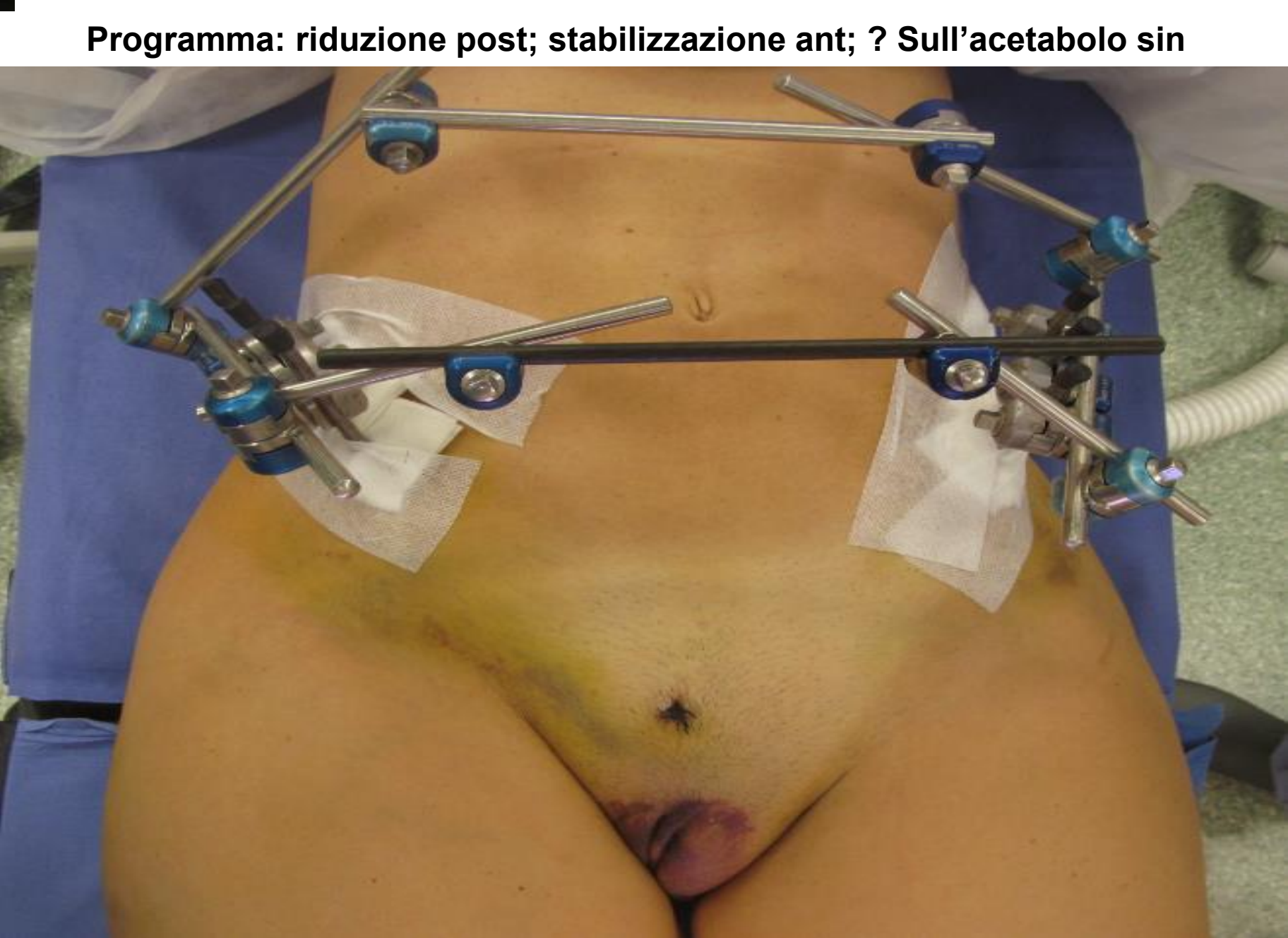
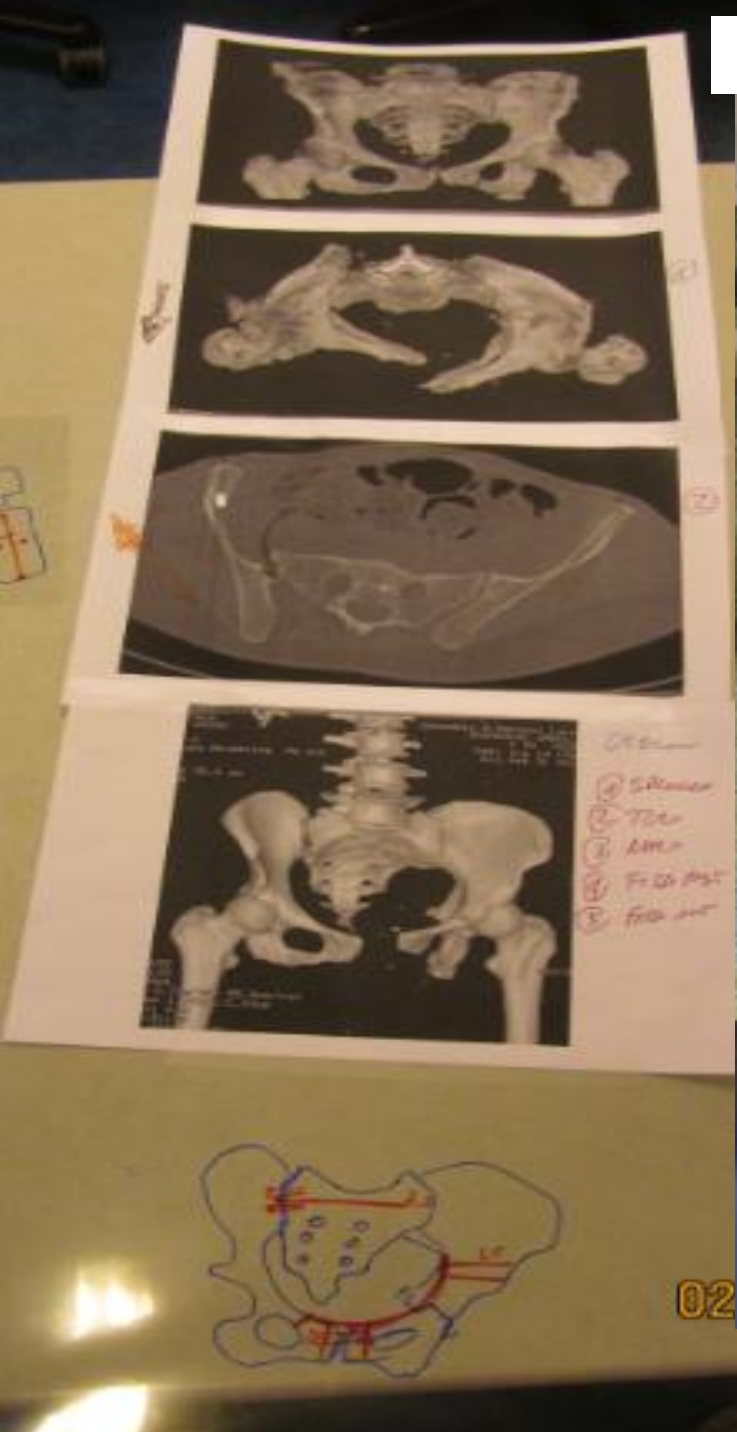

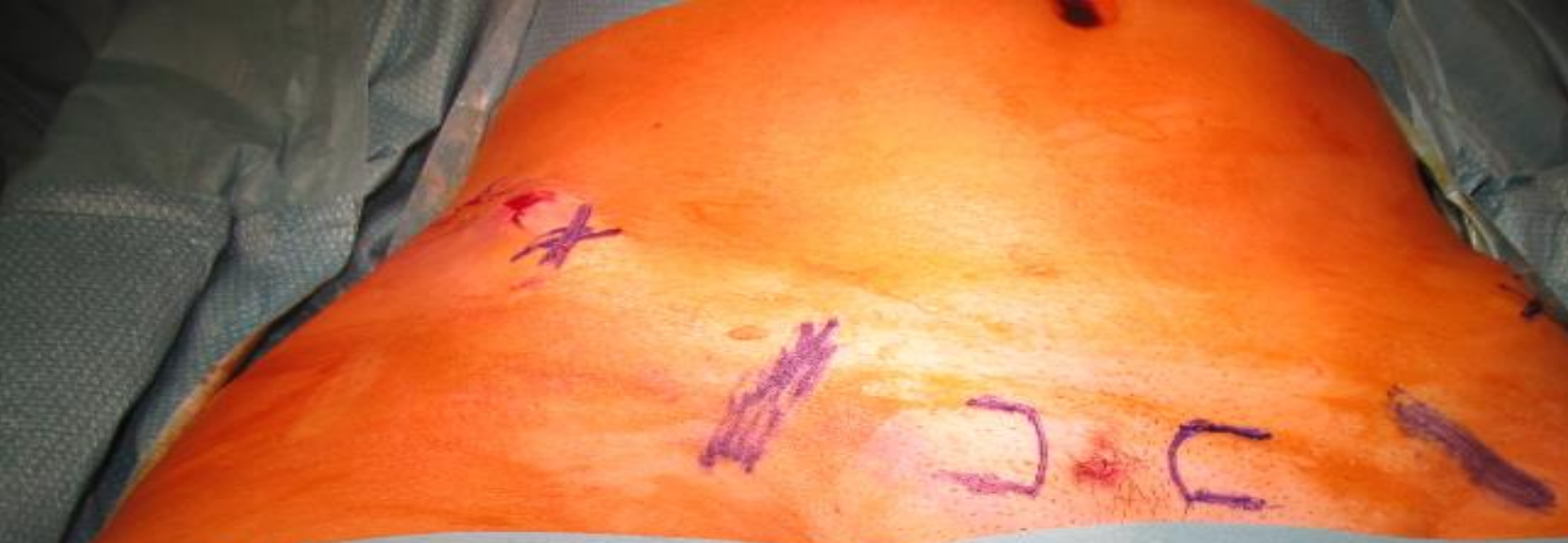E' una LUSSAZIONE



AO

Programma: riduzione post; stabilizzazione ant; ? Sull'acetabolo sin

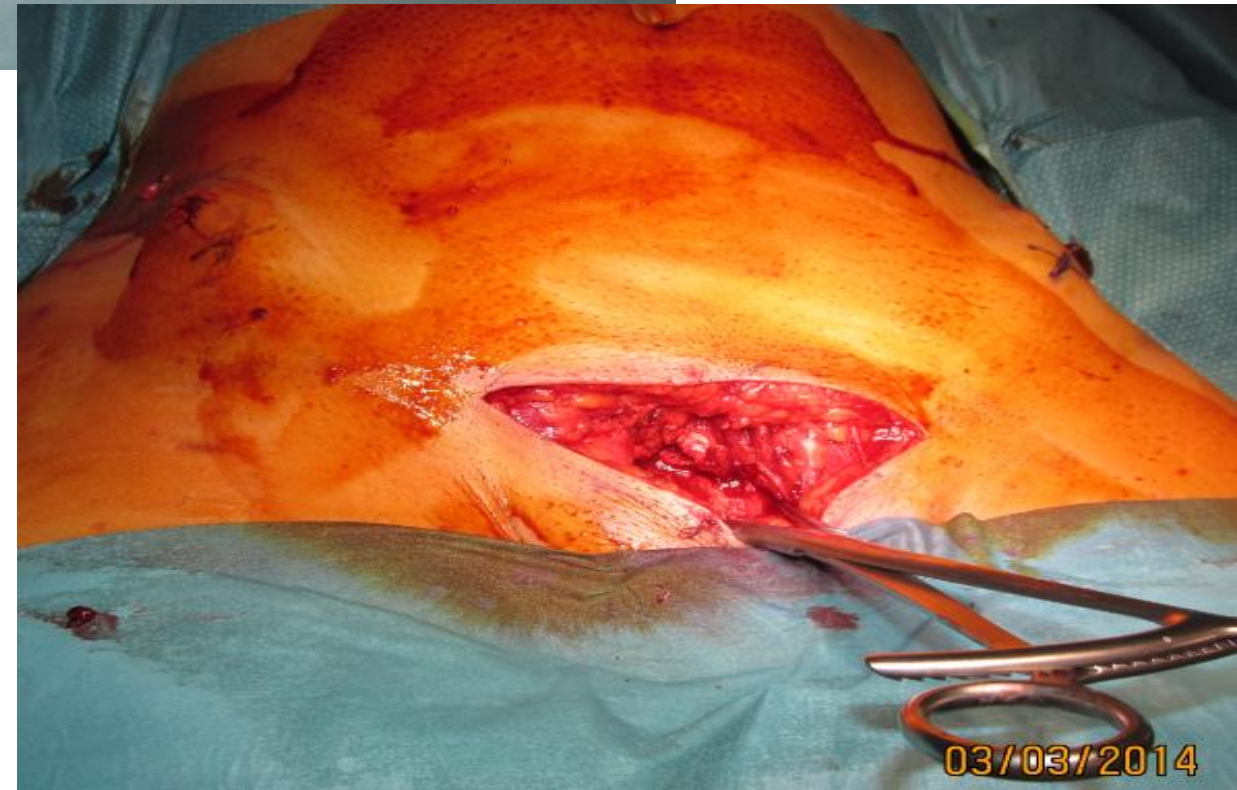
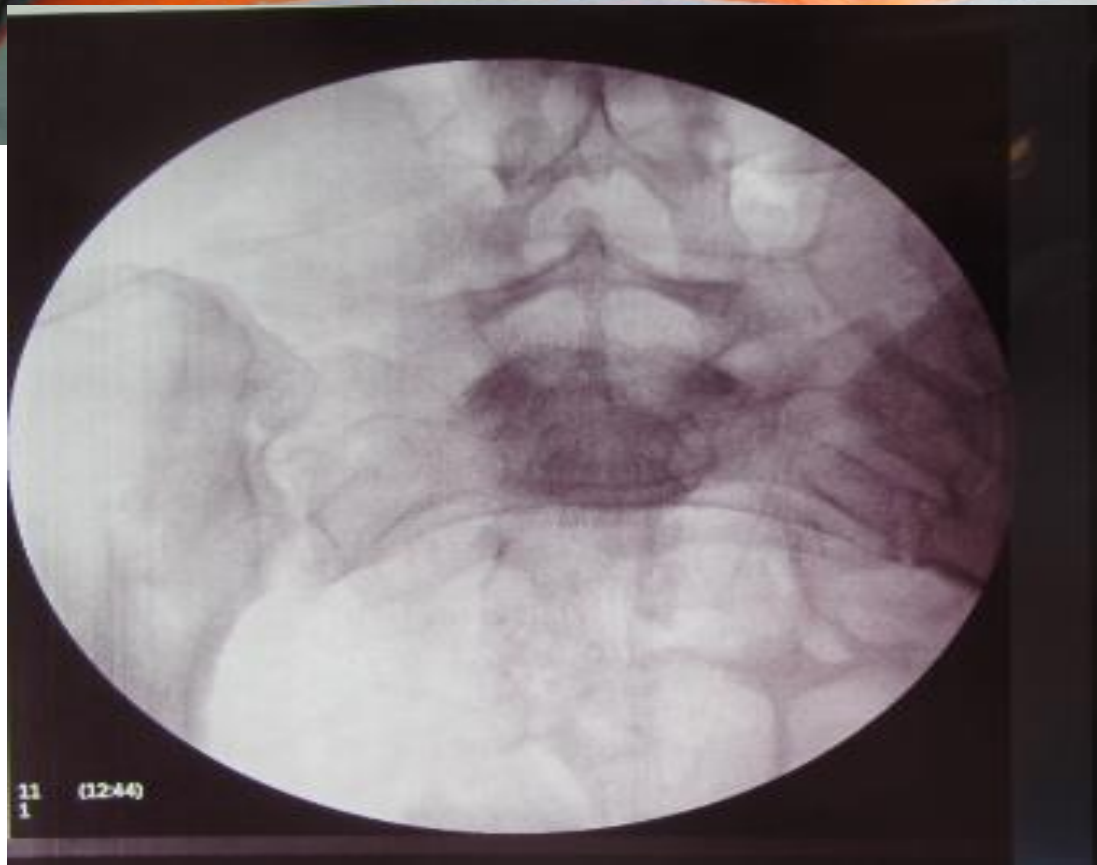




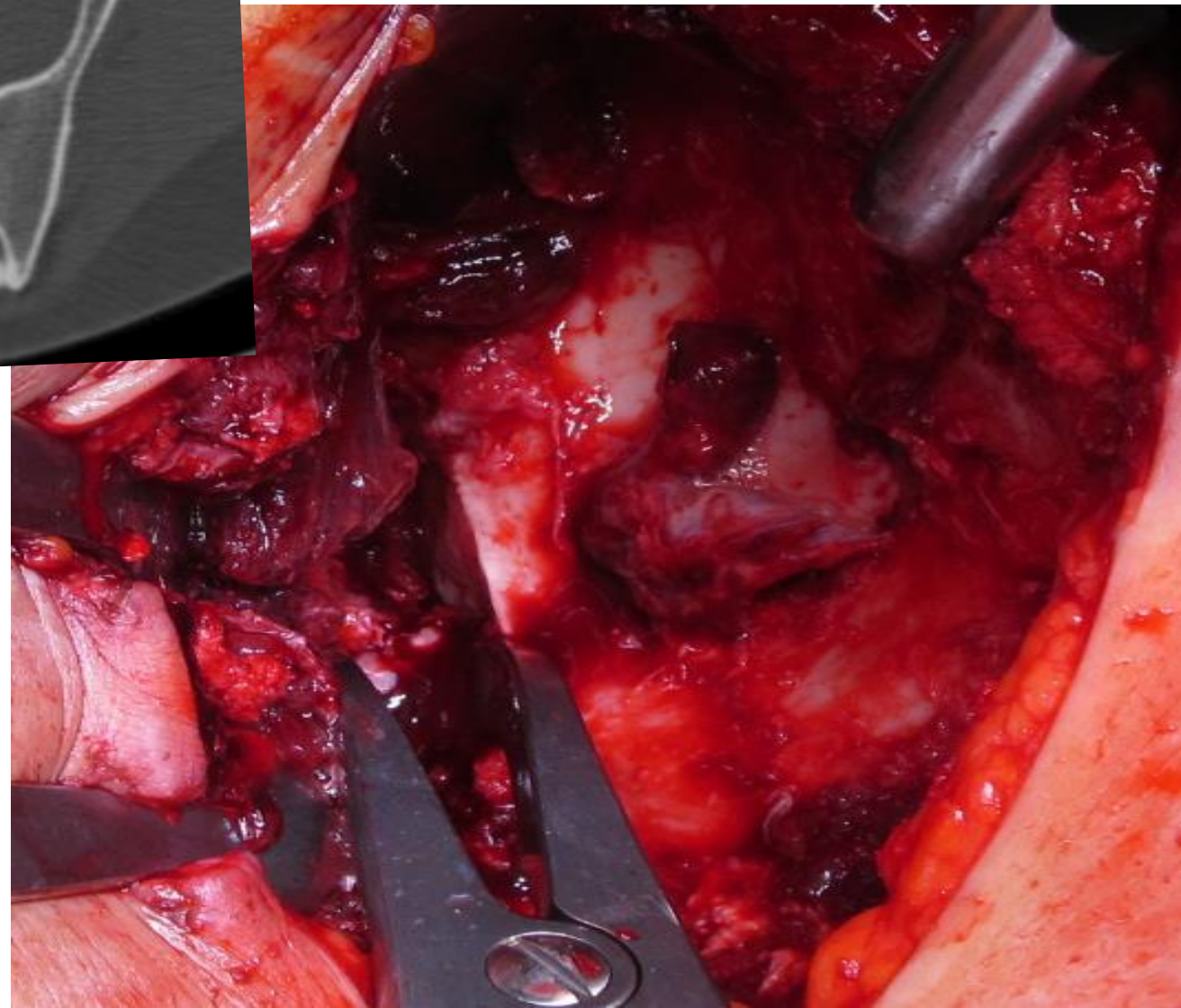
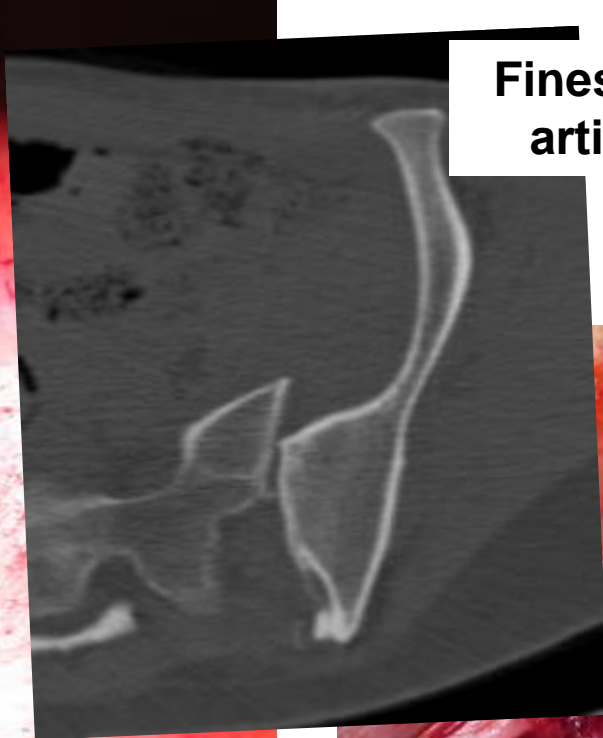
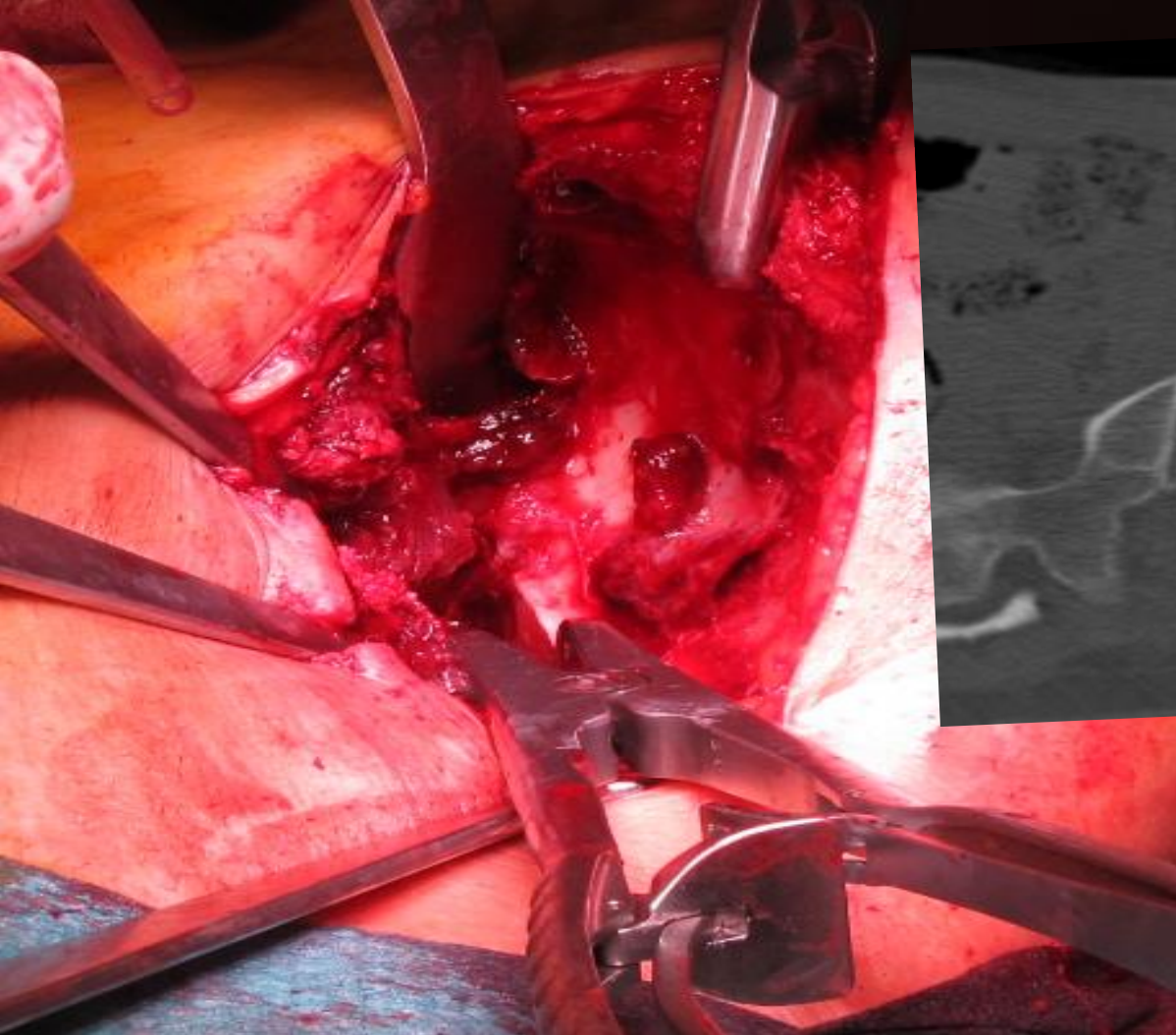
Proviamo a fare quello che hanno fatto a cielo chiuso per mettere l'exfix.

Tentativo di riduzione x via anteriore tramite Pfannestiel + trazione arto....

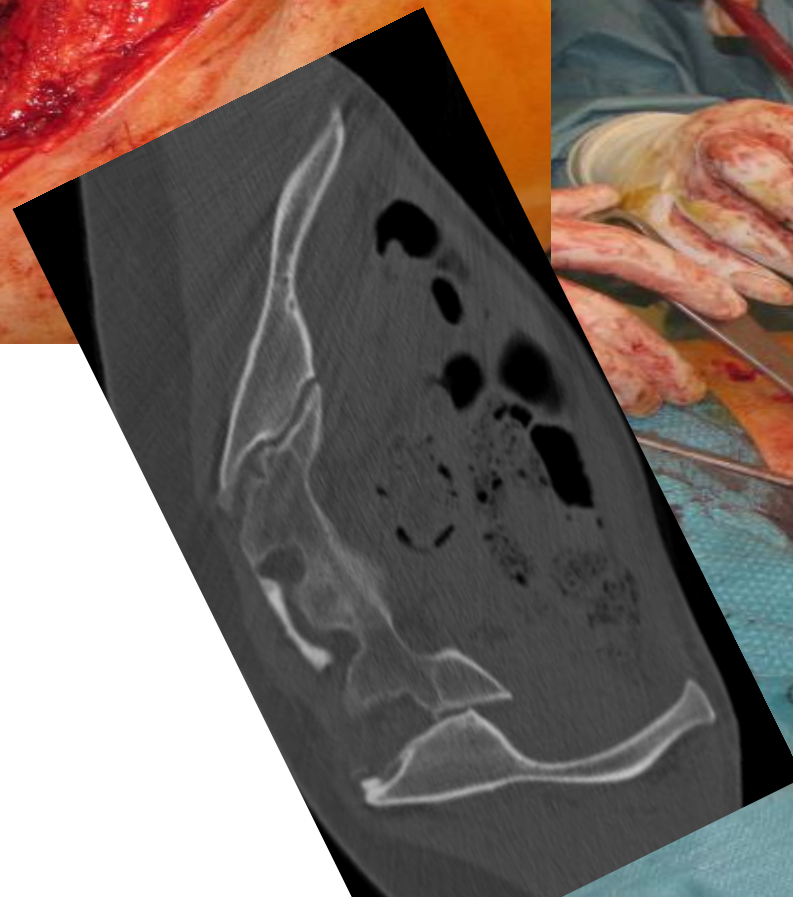
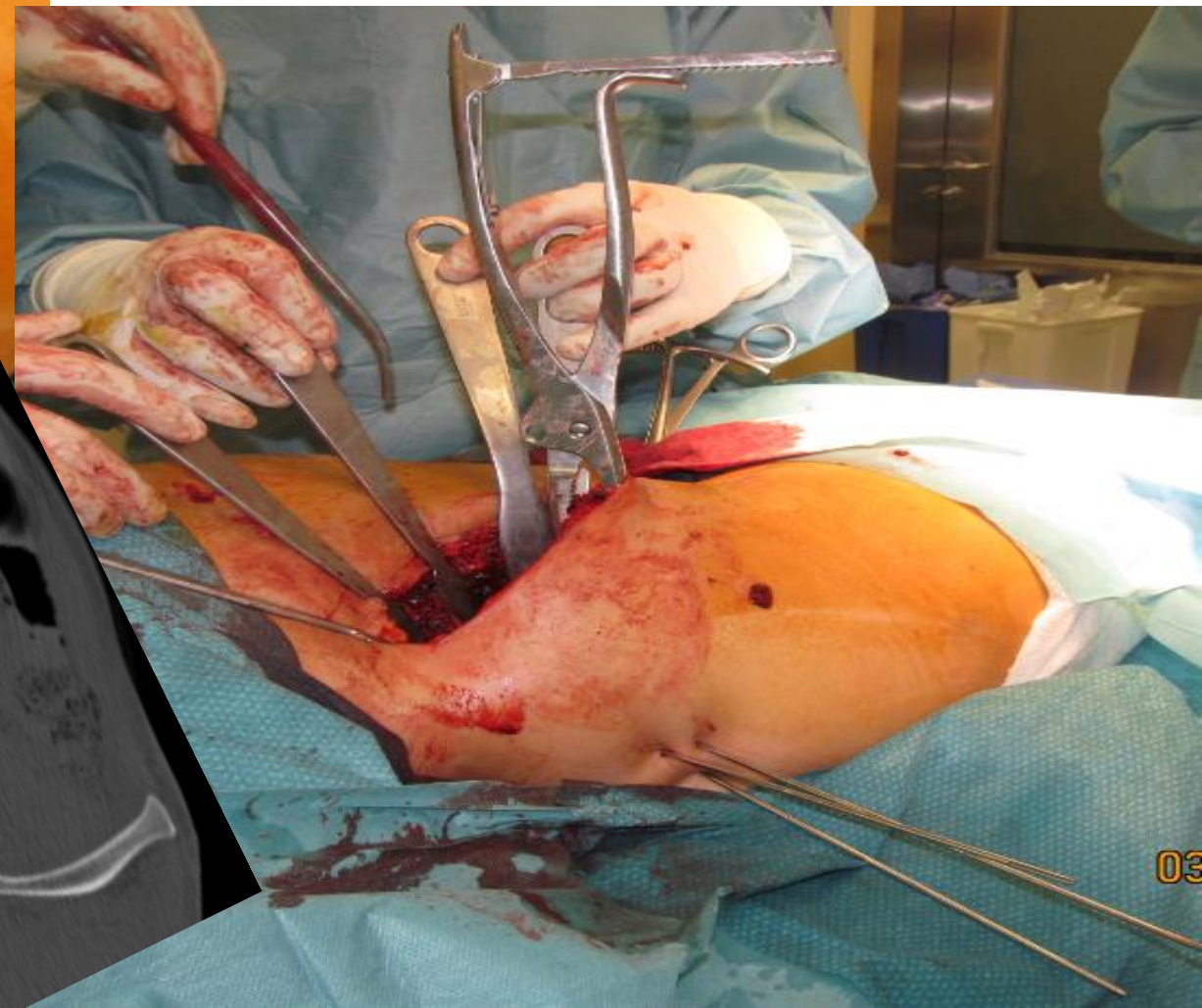
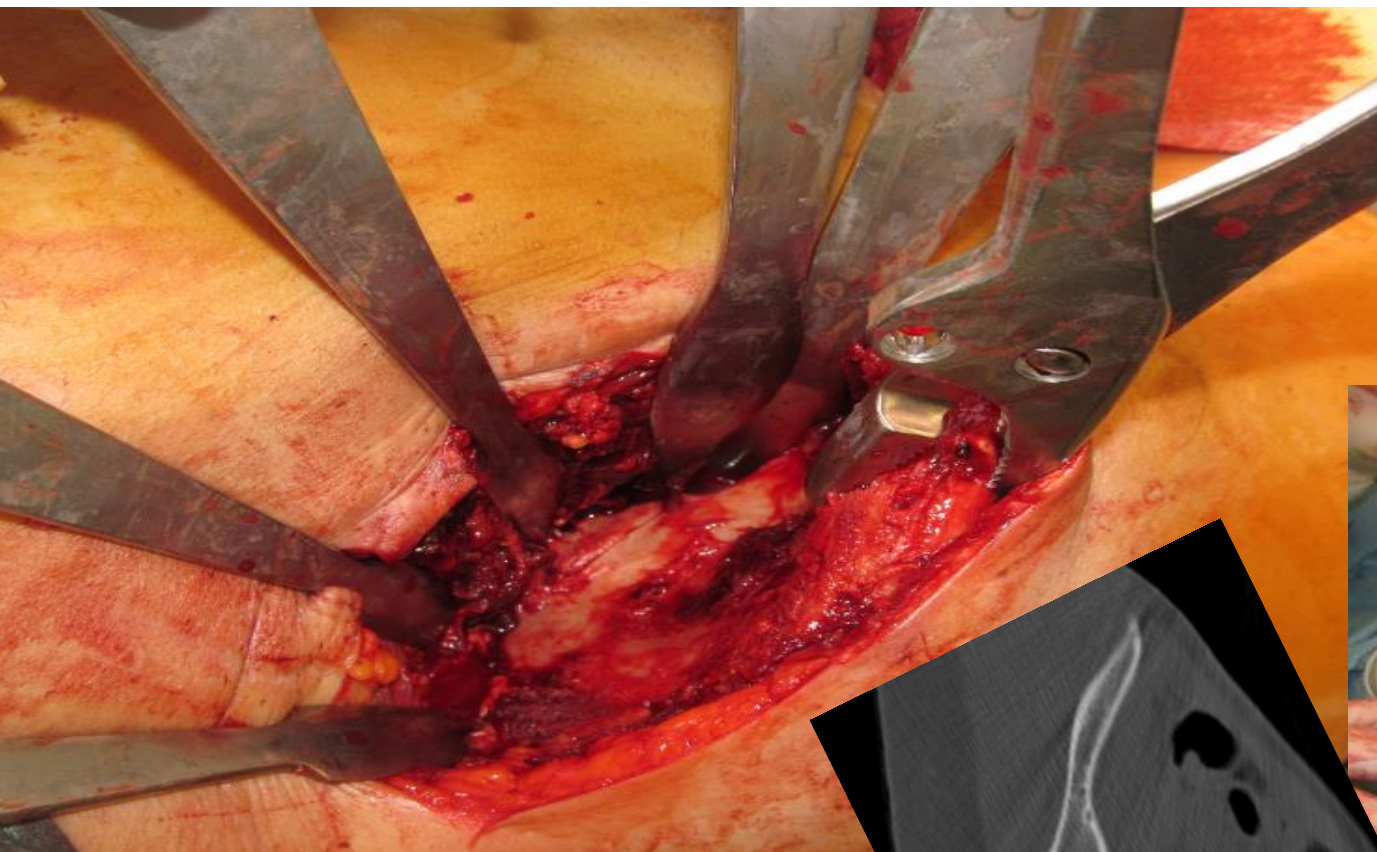
Non si sposta!!!

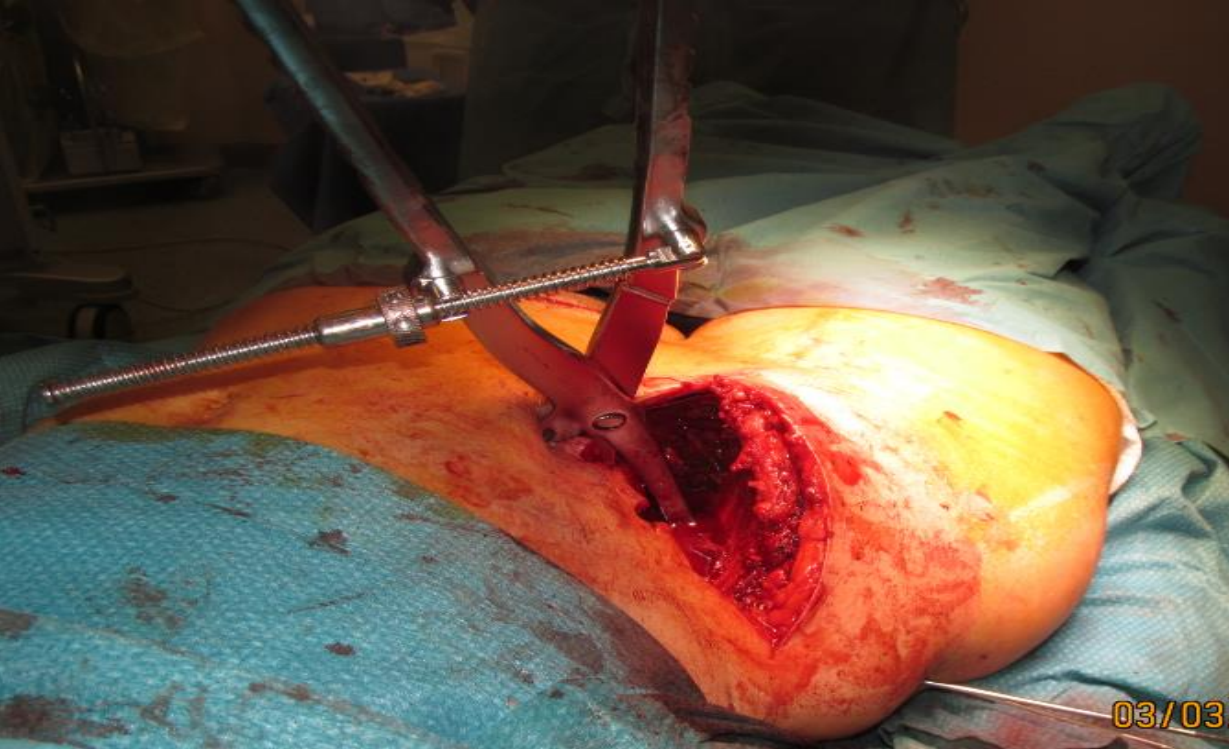


Finestra laterale della ileoinguinale e revisione articolare e disincastrare l'ala con spreader

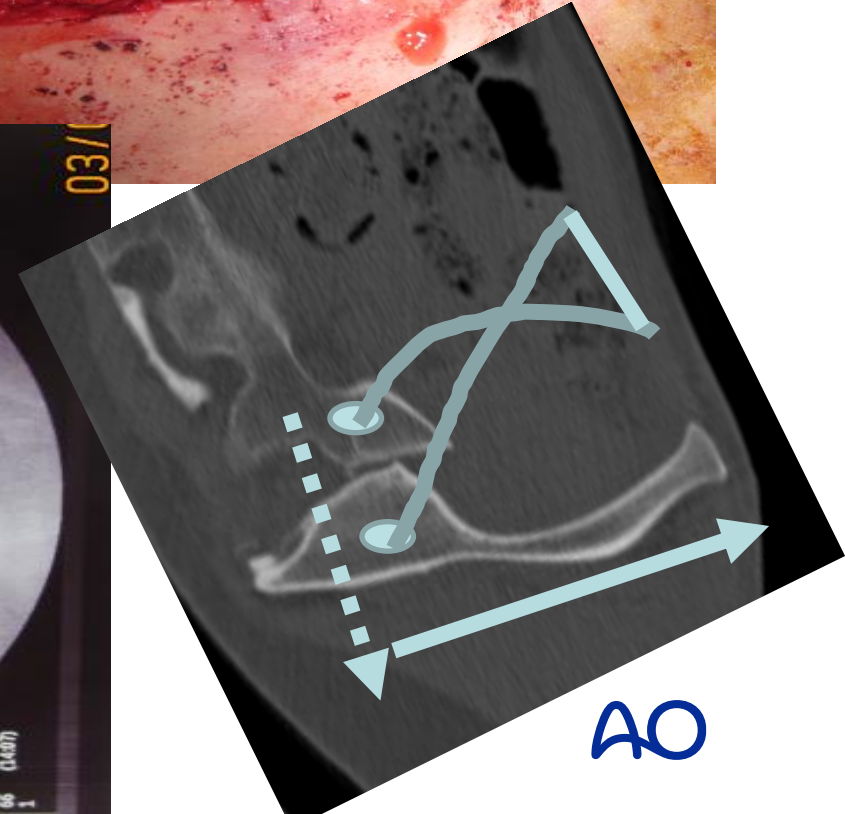
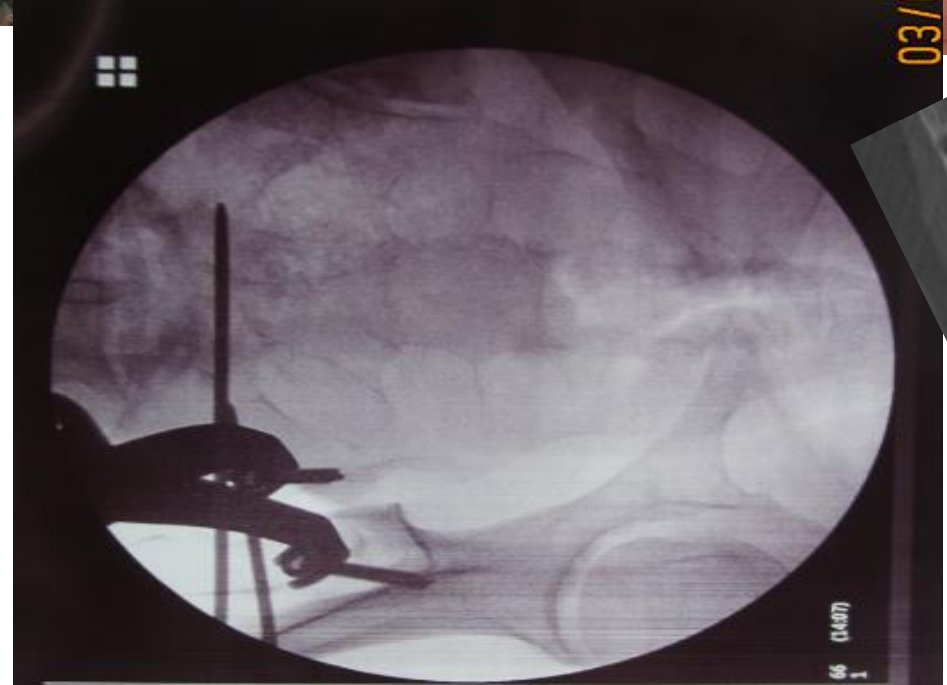
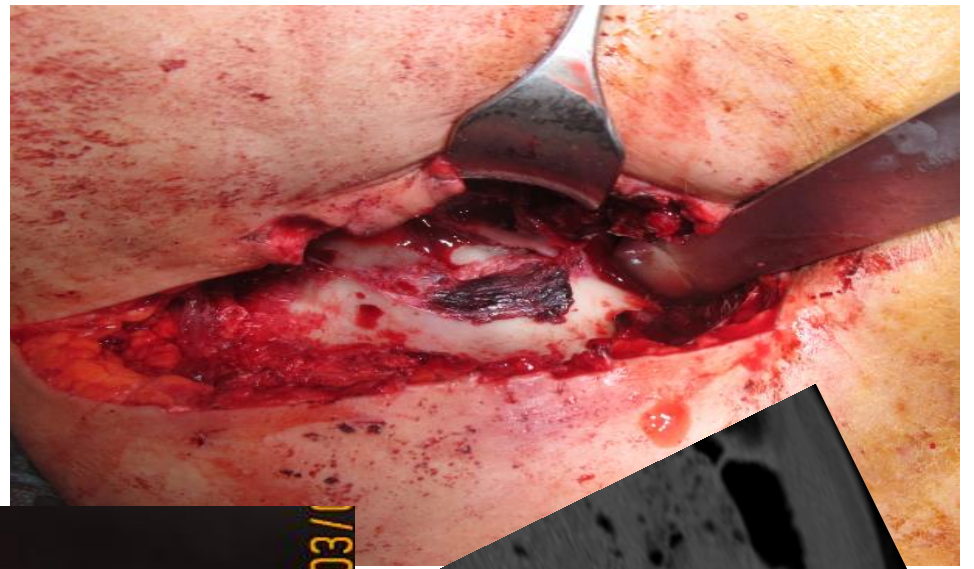

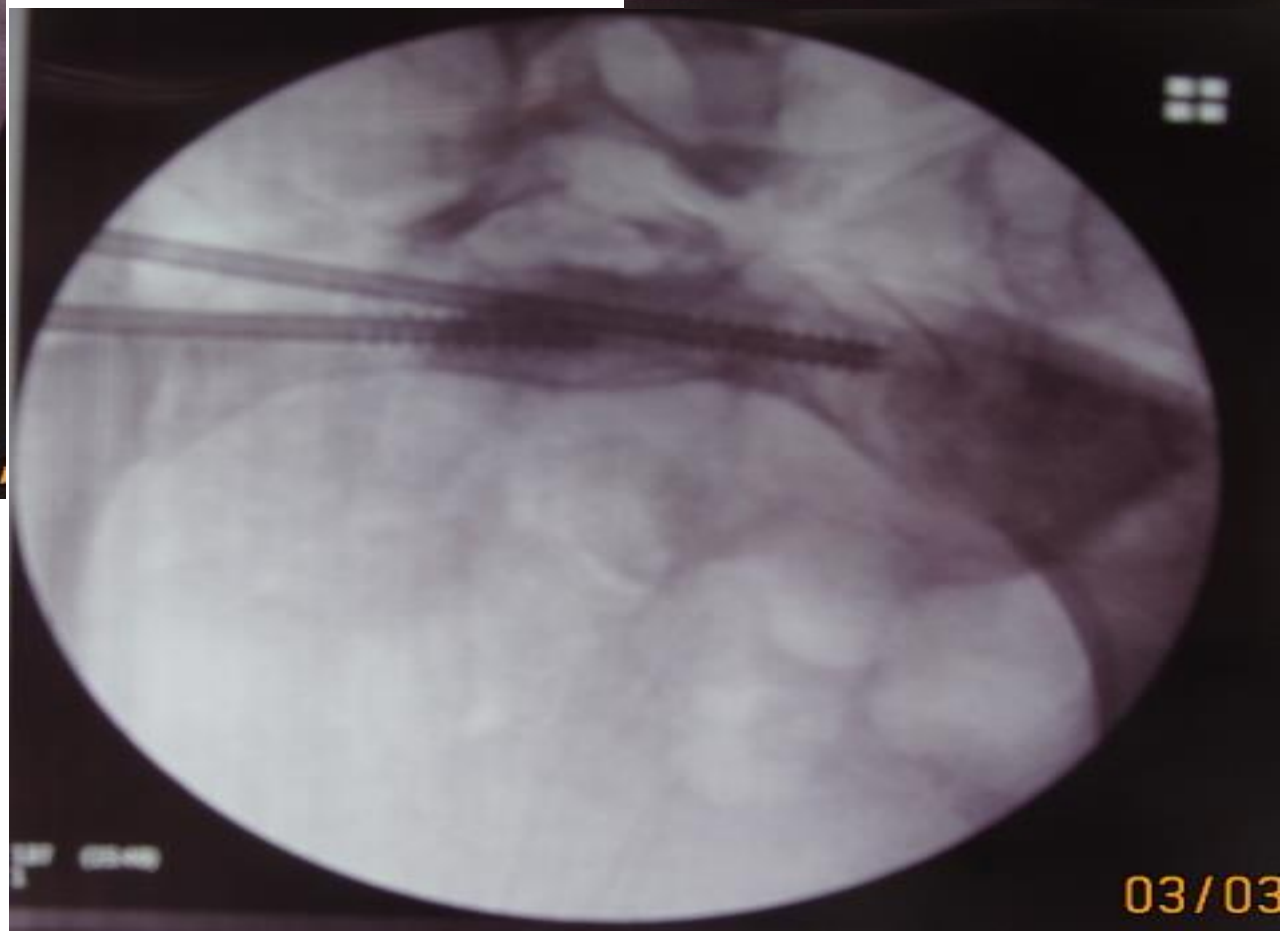
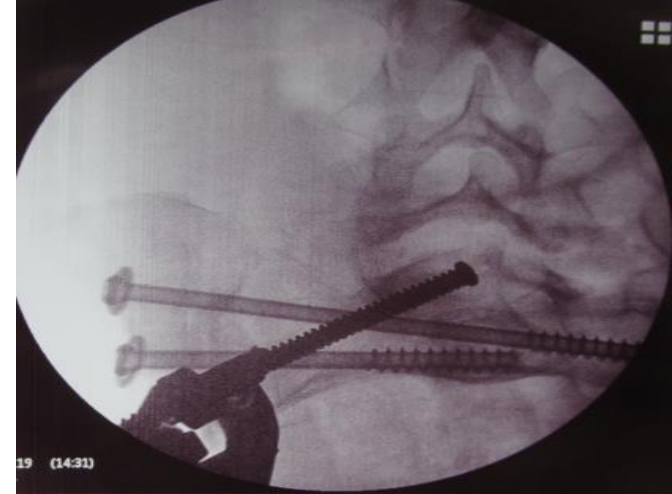
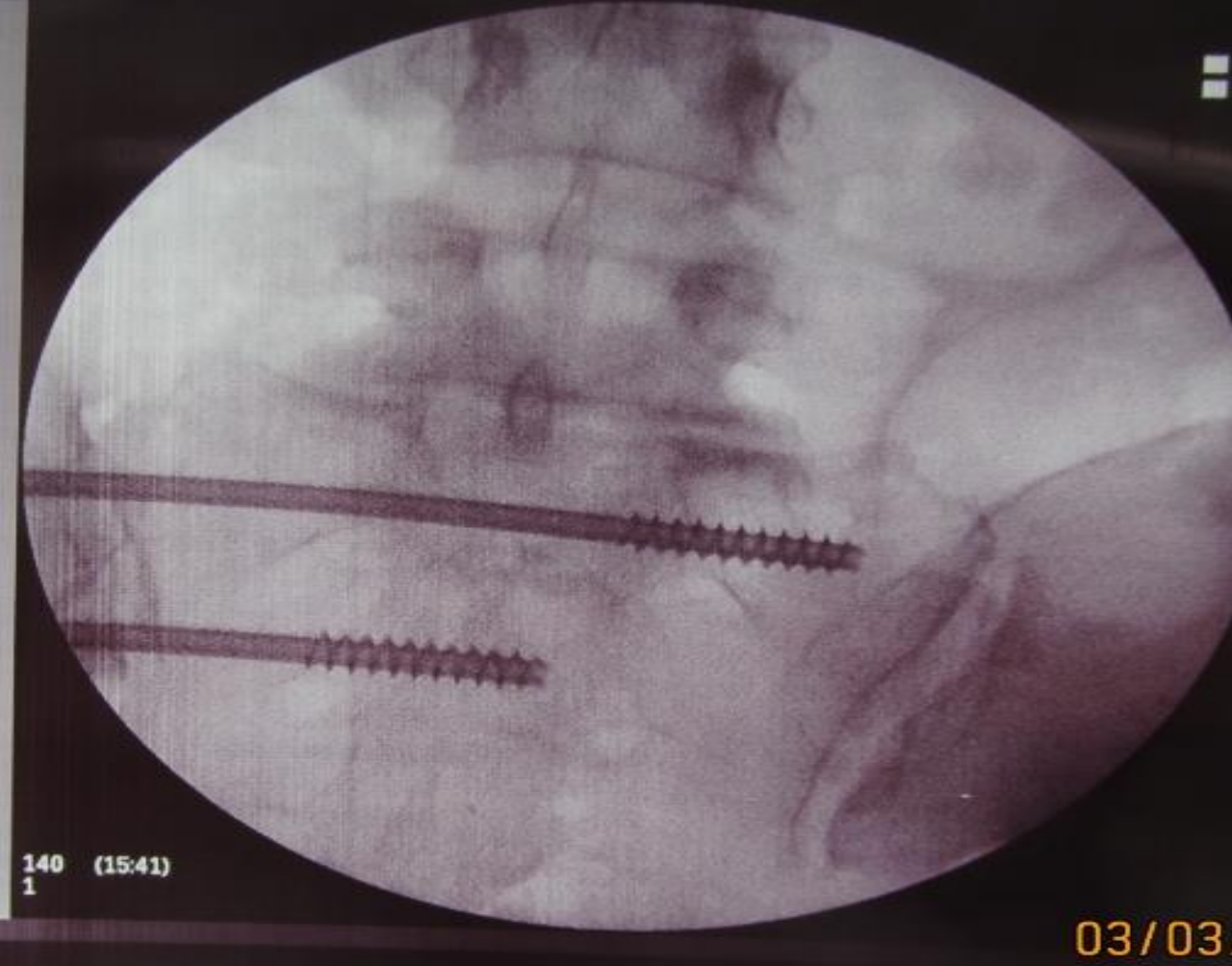
Riduzione con la pinza di Farabeuf a chiudere e sintesi provvisoria con fili guida viti cannulate



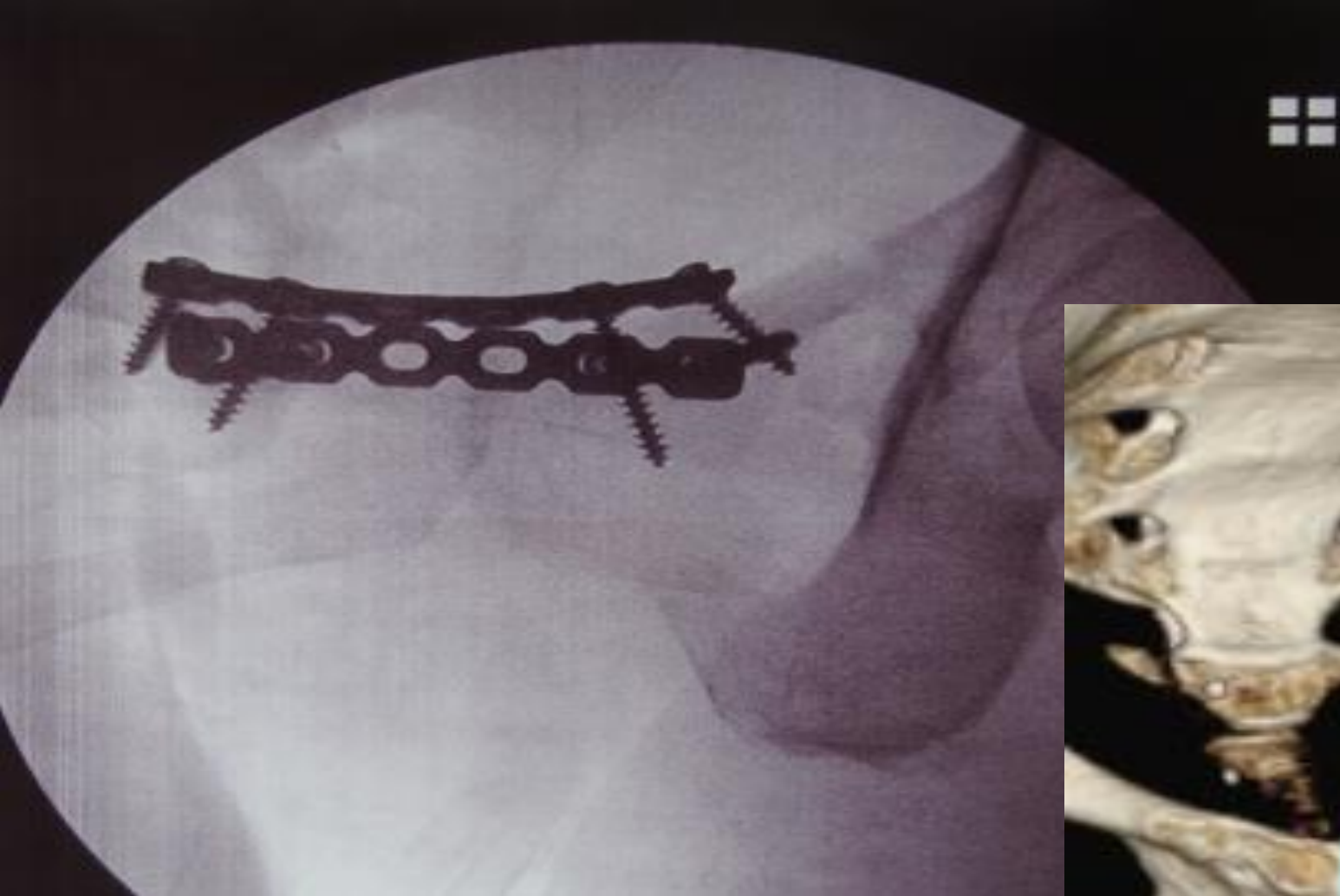


Riduzione insufficiente per cui si usa la Jungbluth (doppio movimento) + trazione manuale

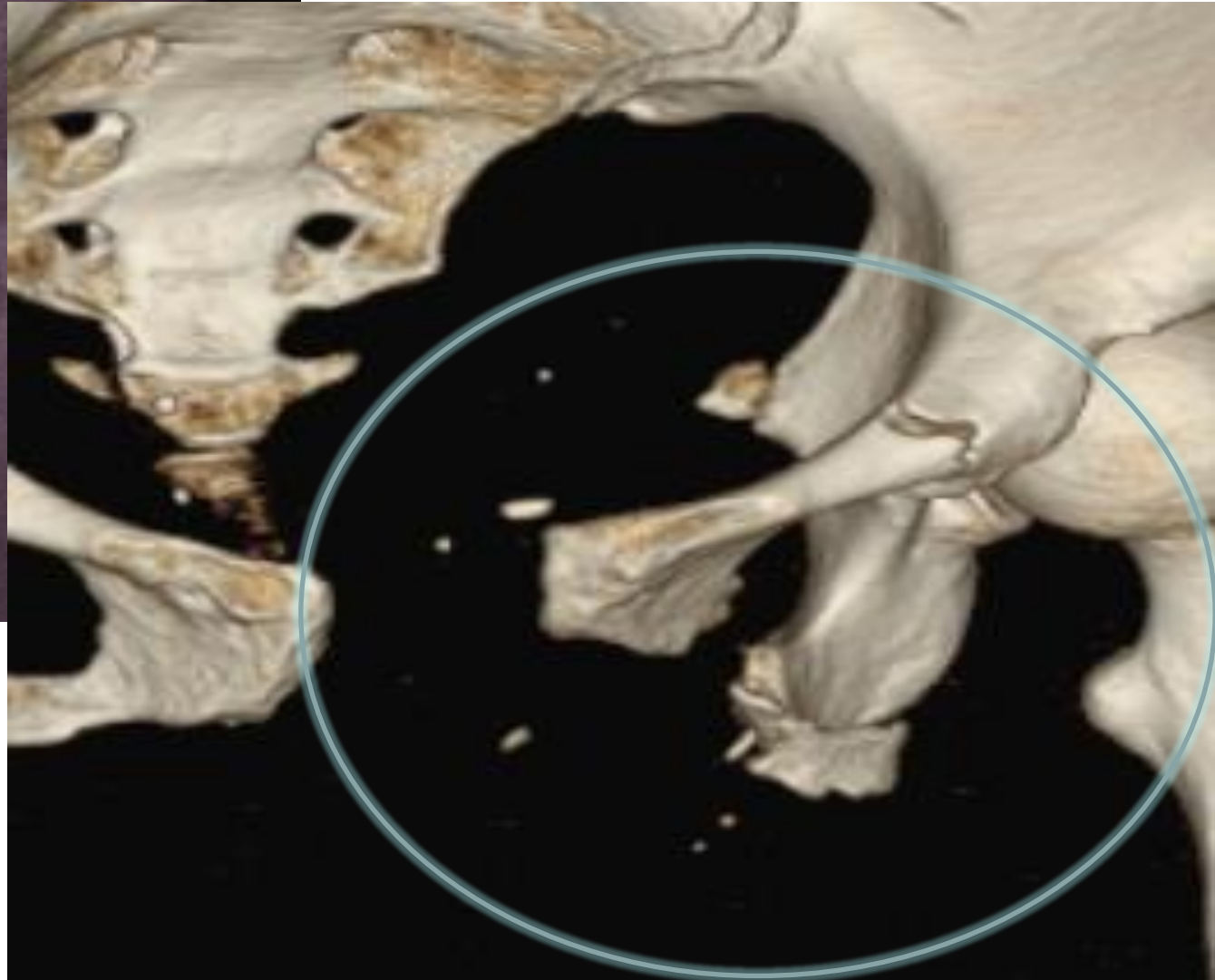


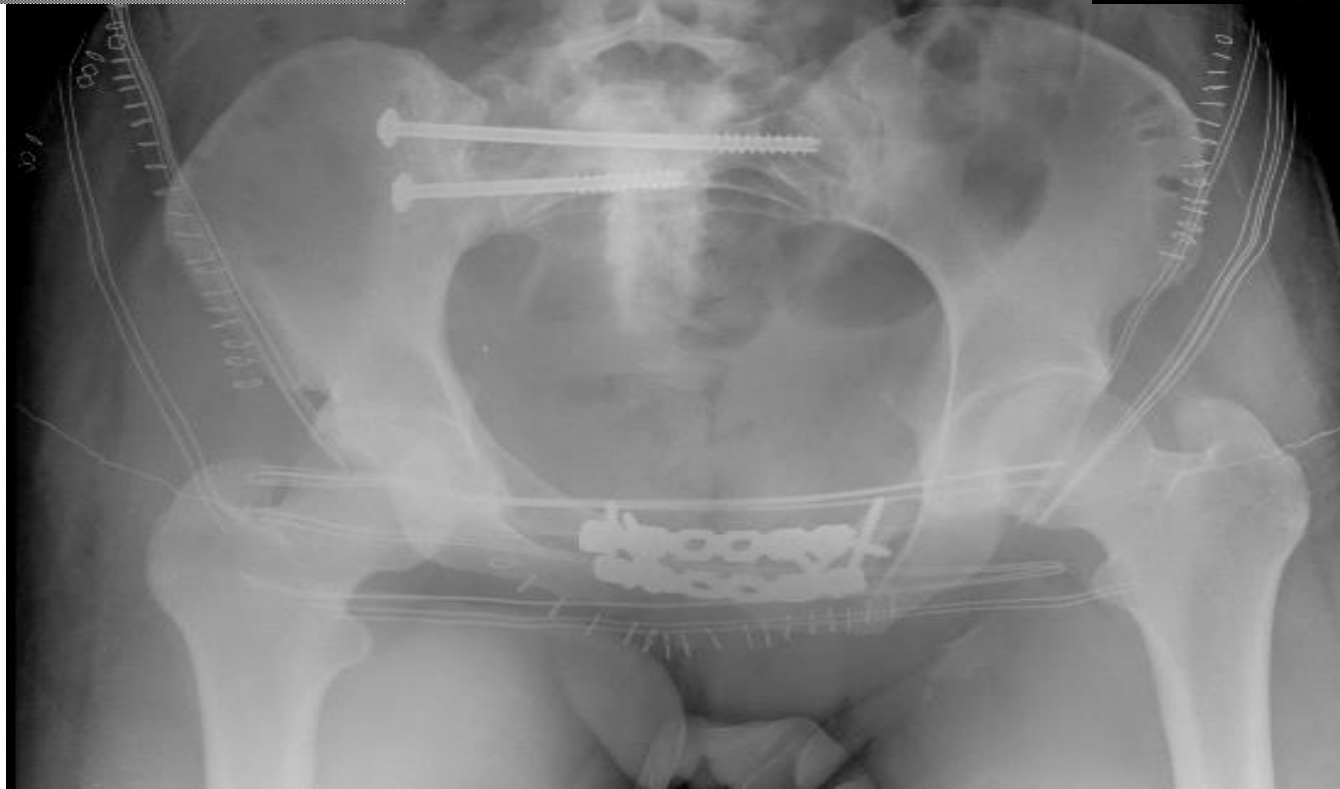
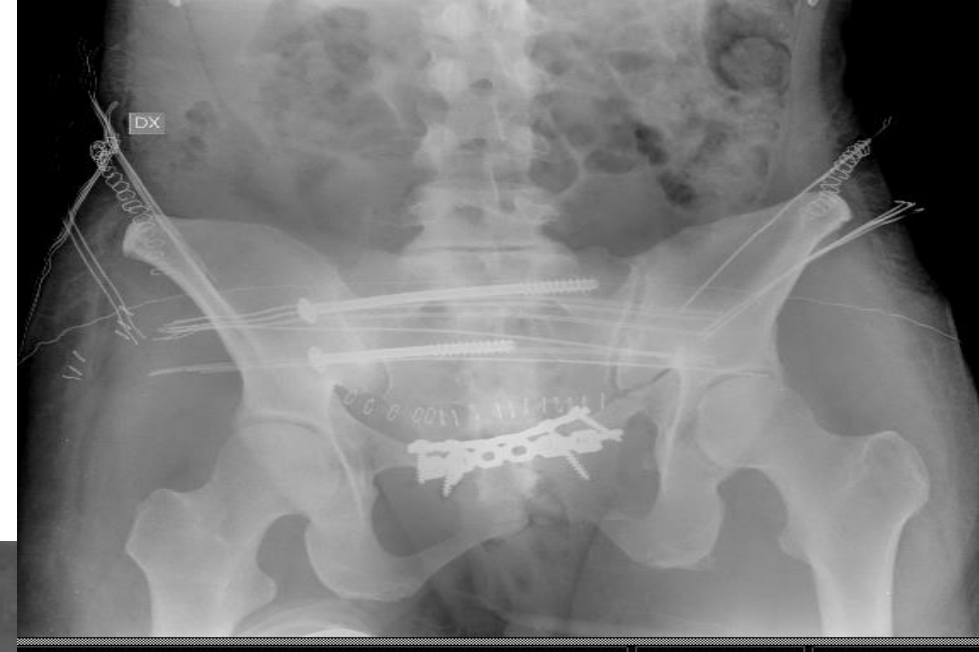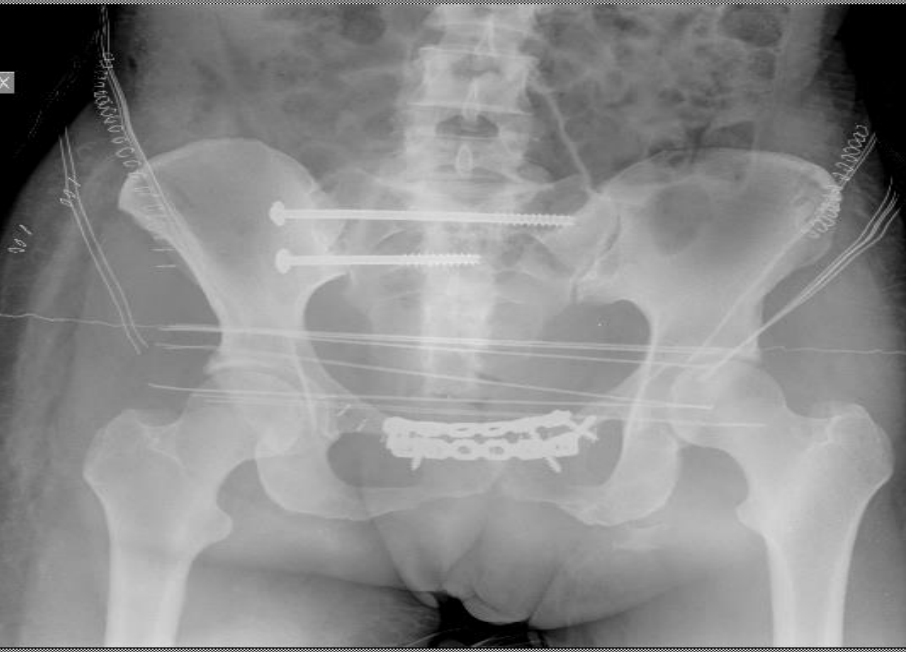


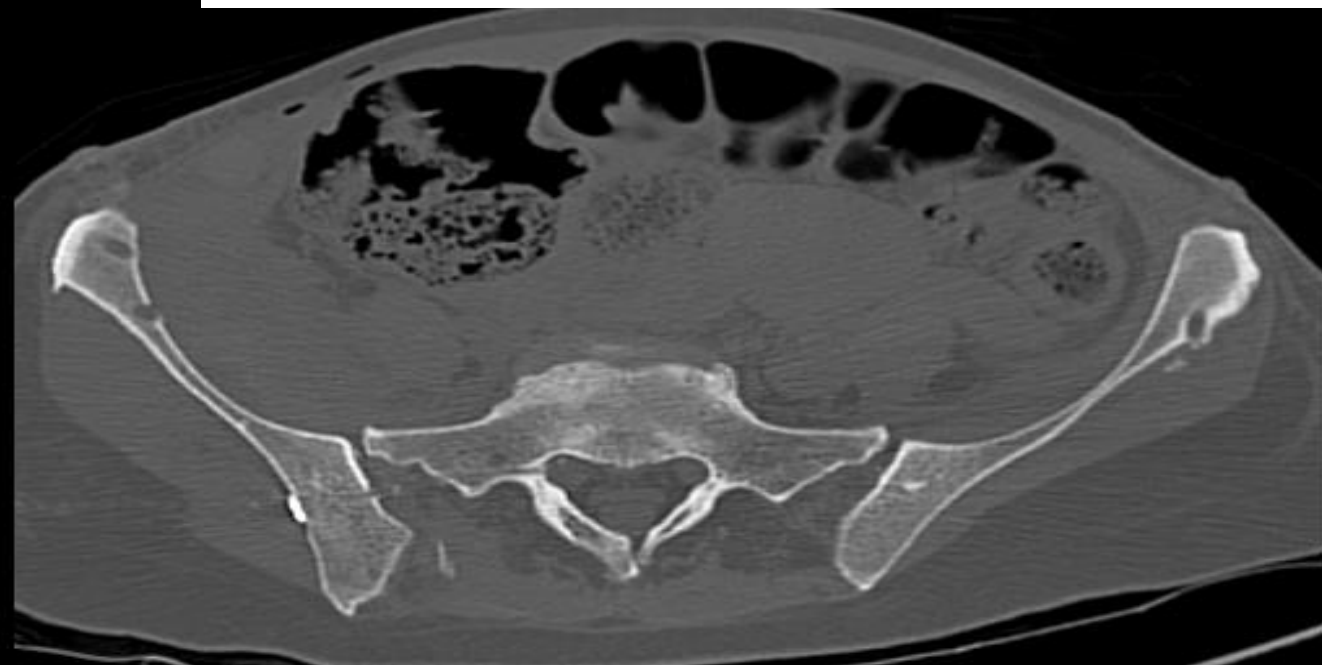
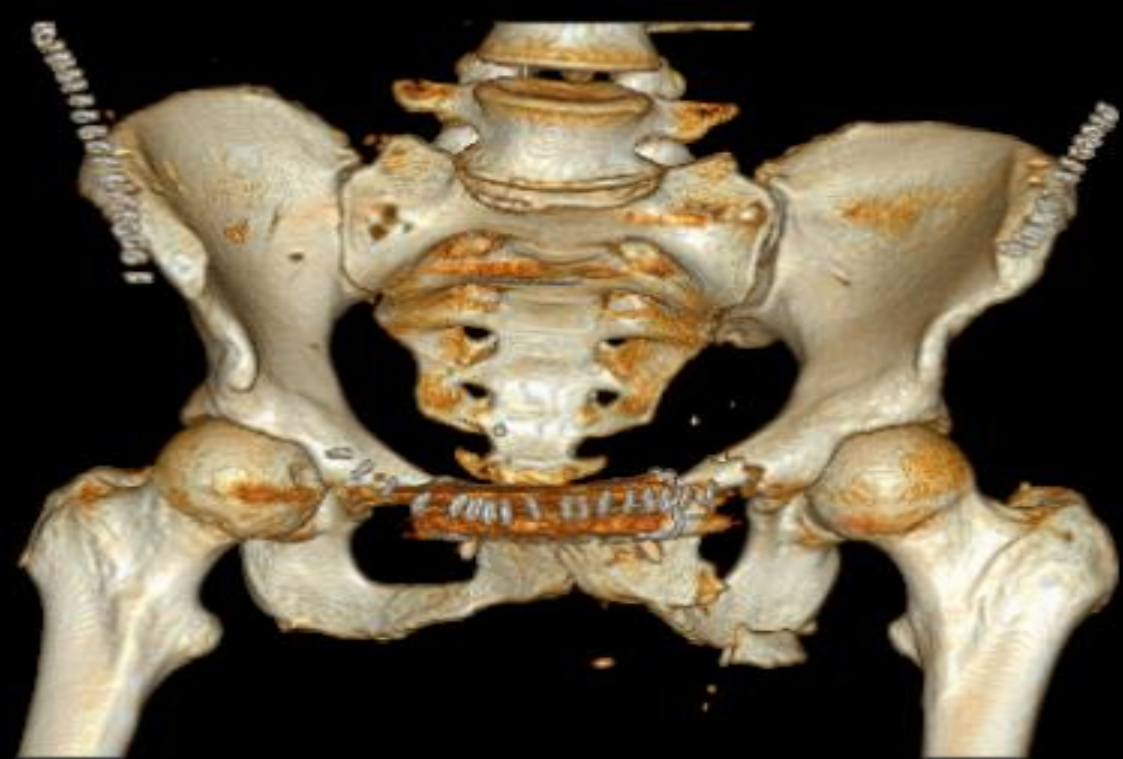Stabilizzazione finale con viti



**Stabilizzazione anteriore
Difficile riduzione per
scomposizione della branca
ischiopubica**







GET

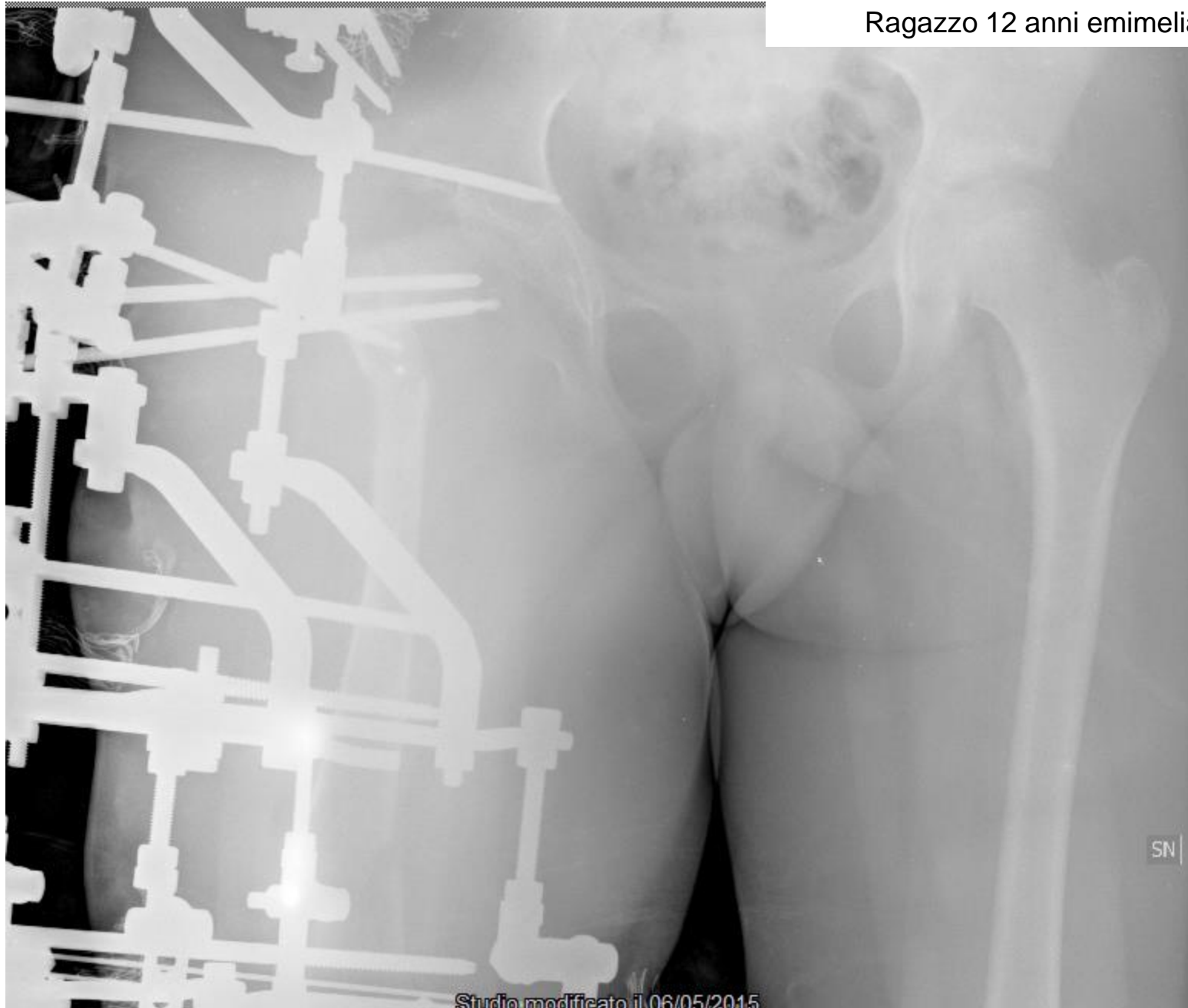
CHECK

SET

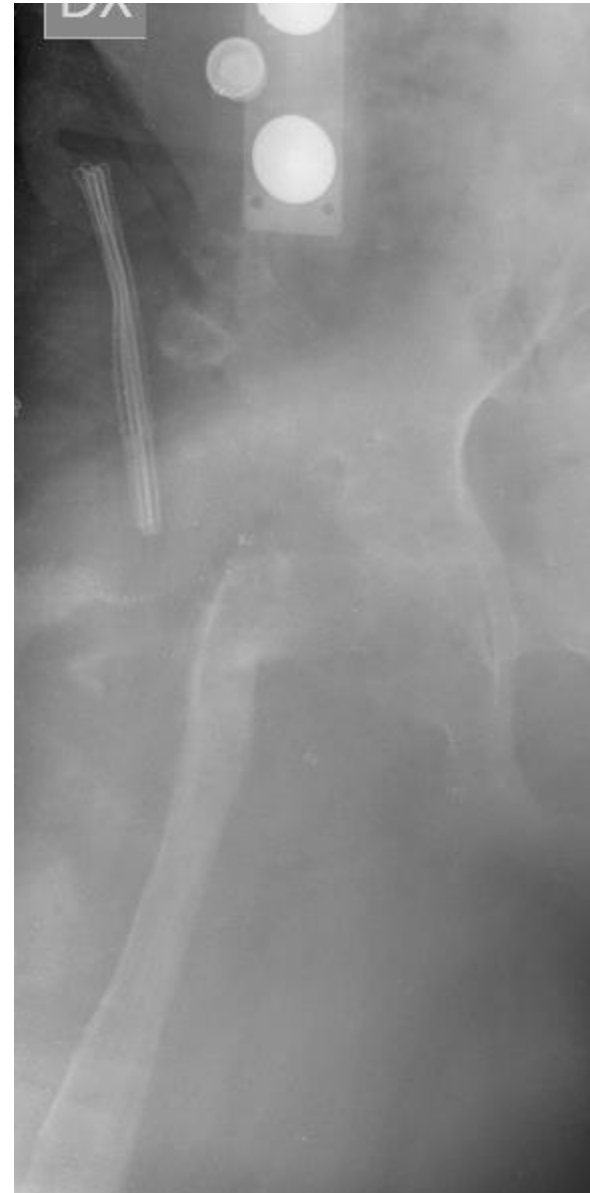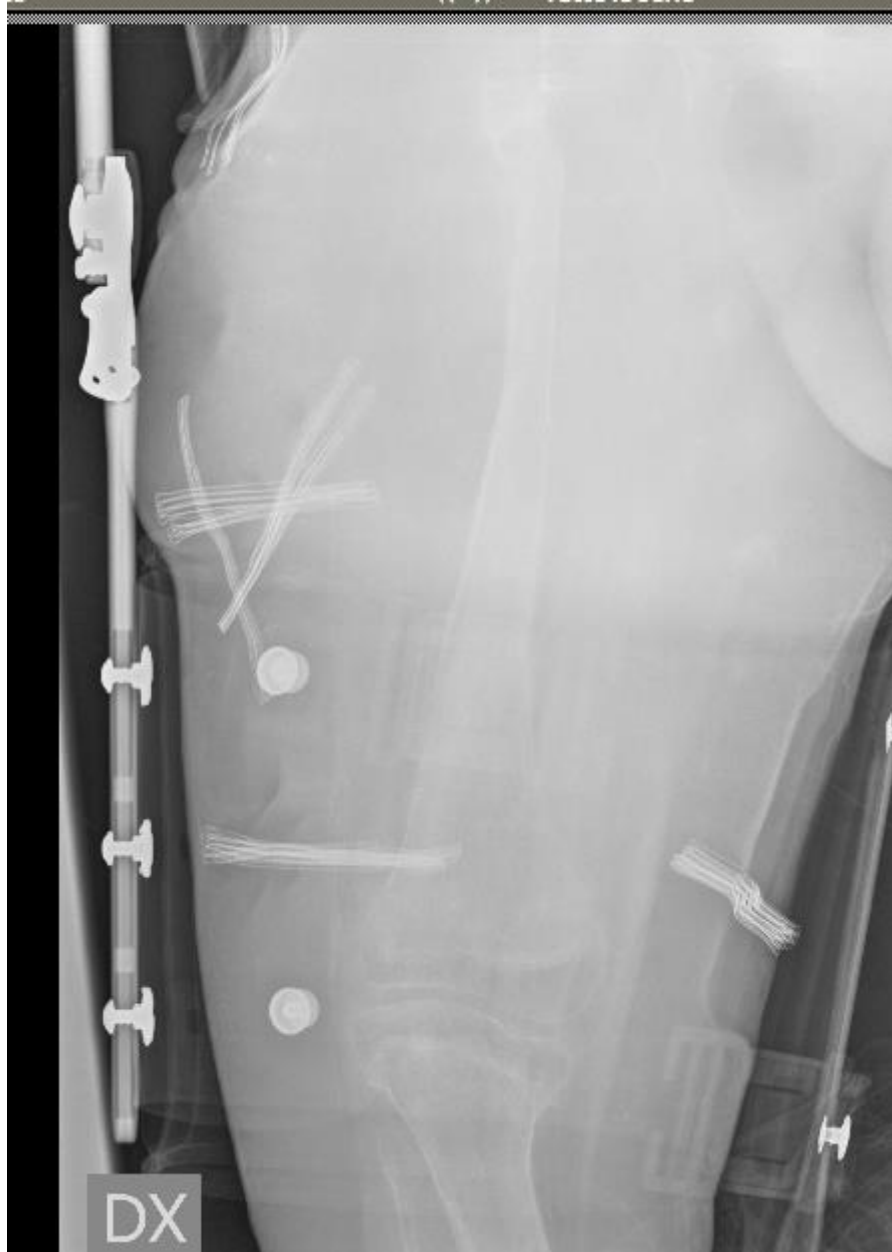Anche con il fissatore

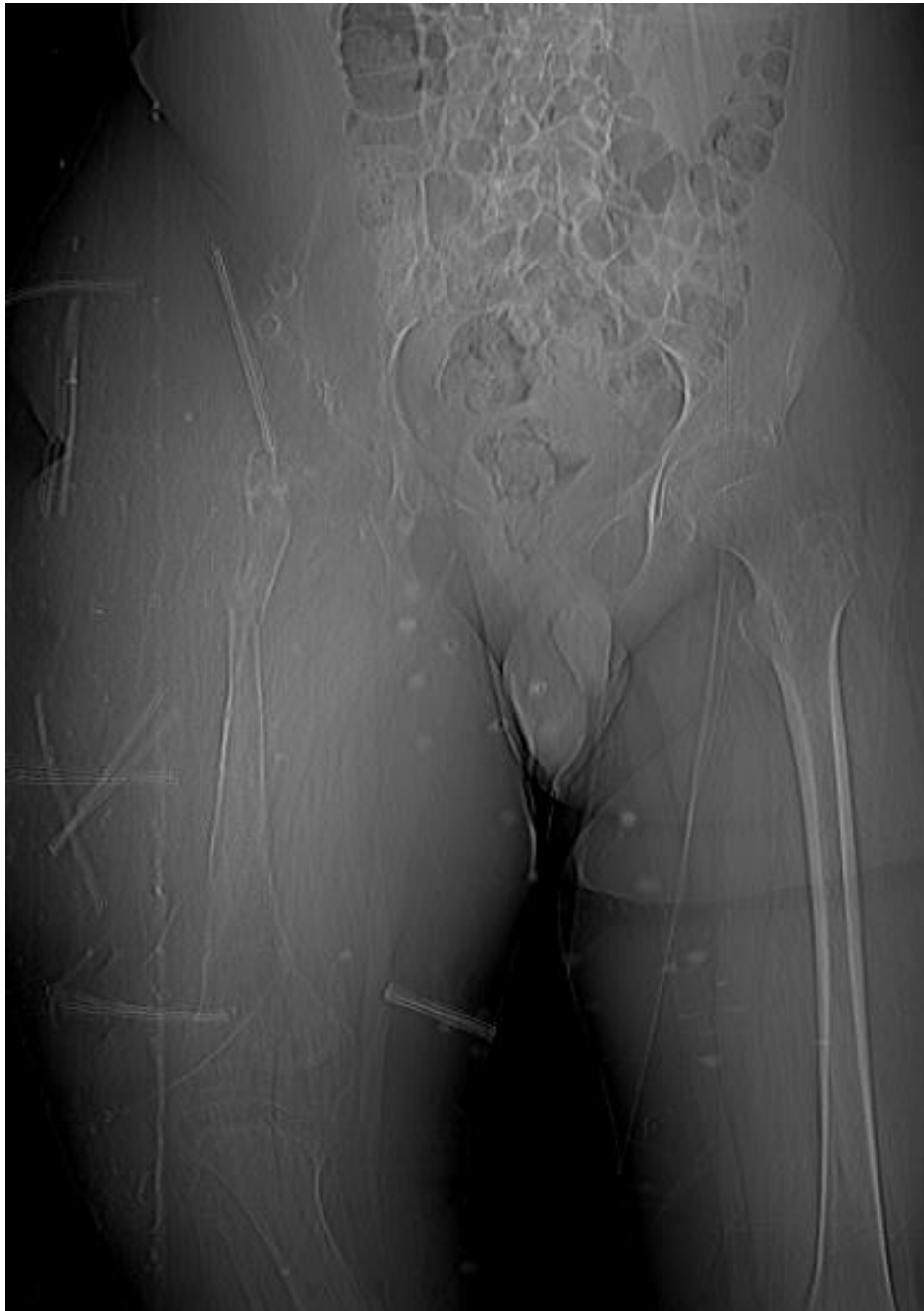Ingombro e rimozione exfix

Ragazzo 12 anni emimelia

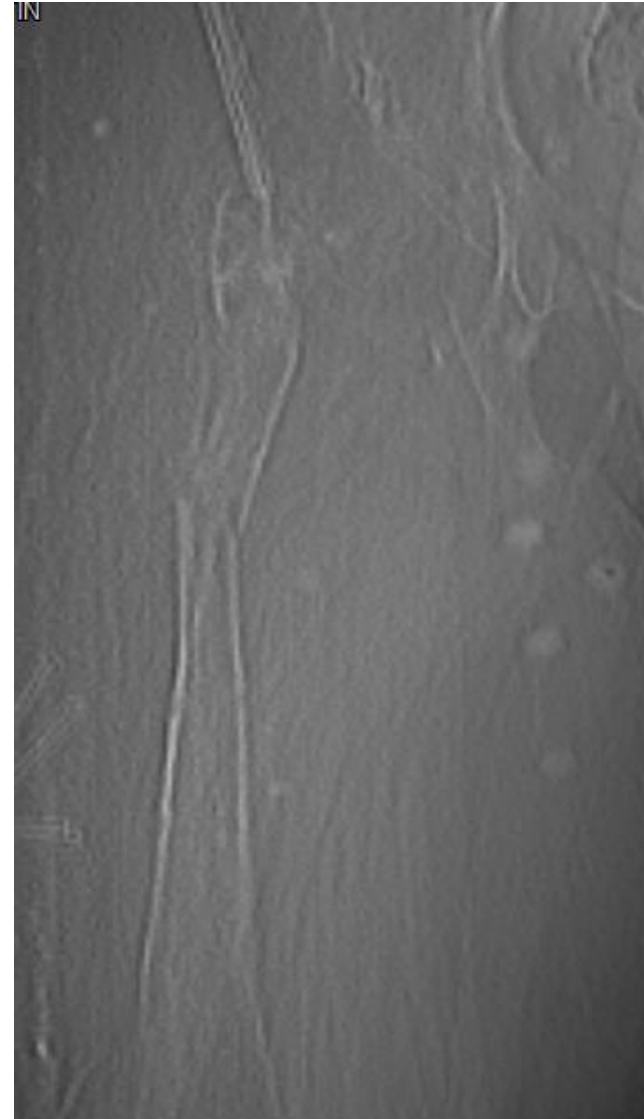


Maggio 2015 rimozione exfix e tutore

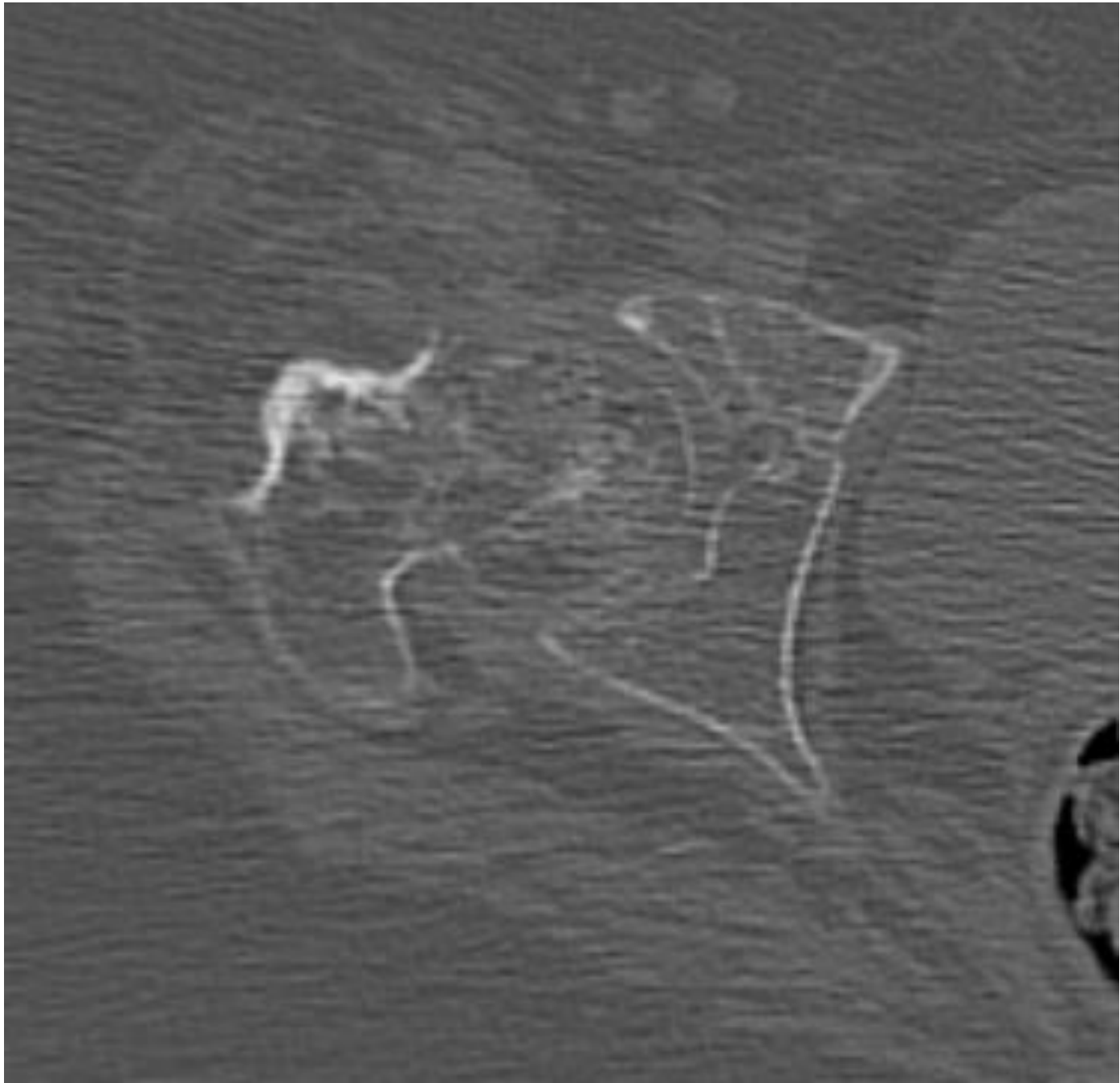




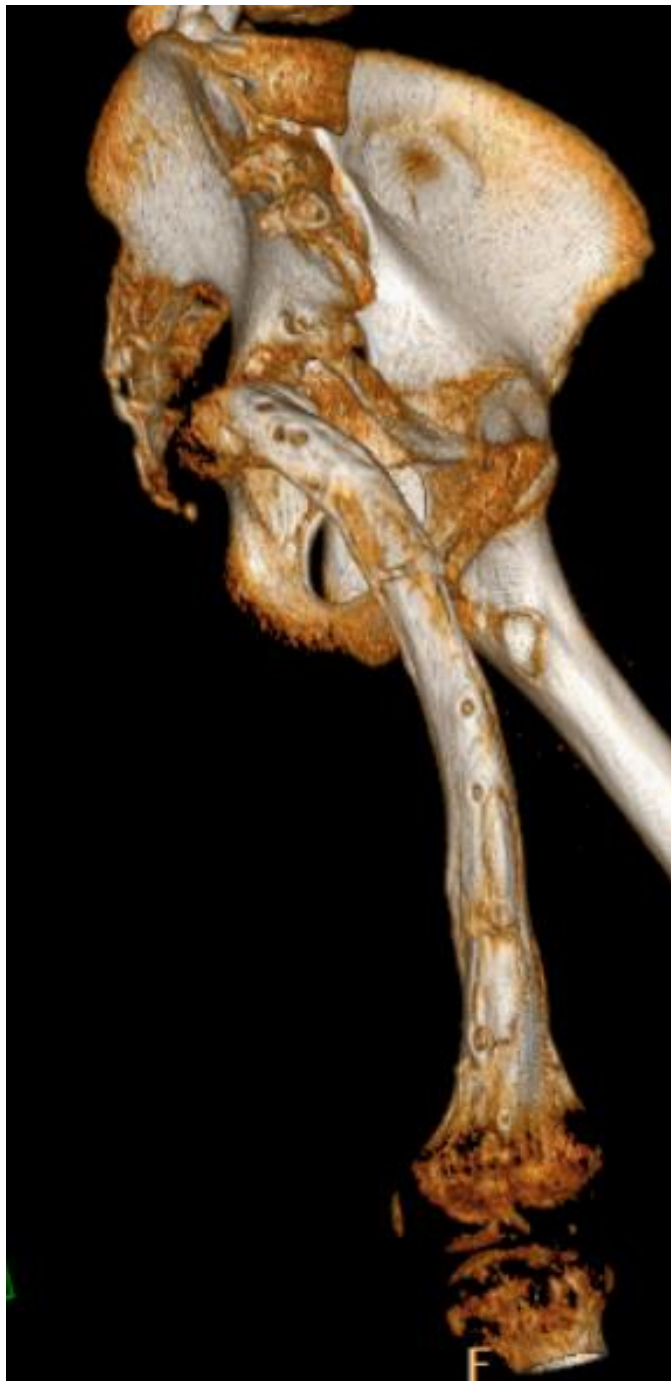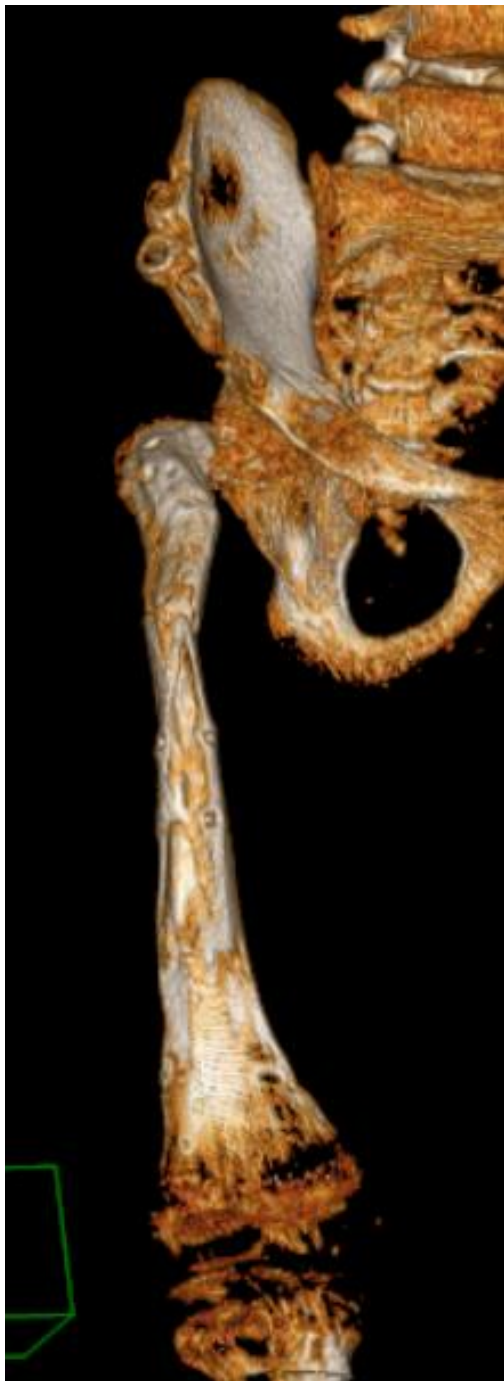Dopo 2gg

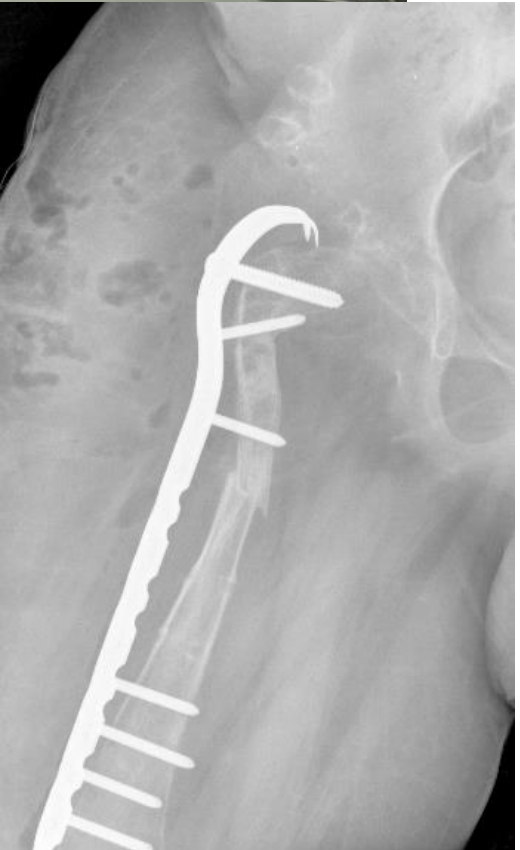
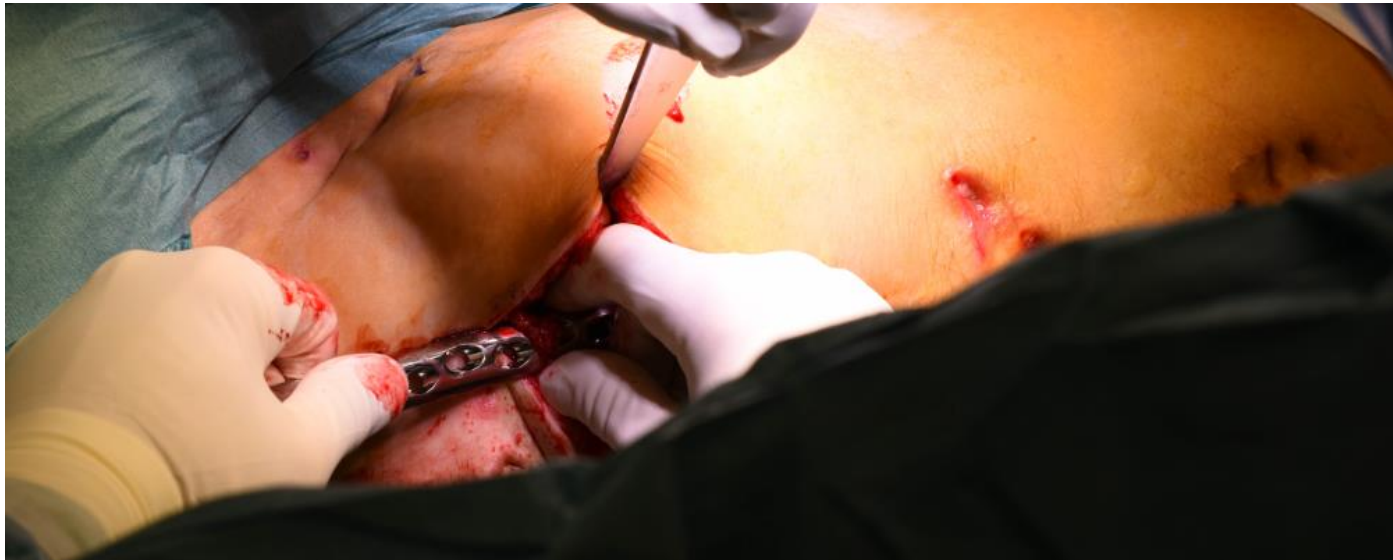
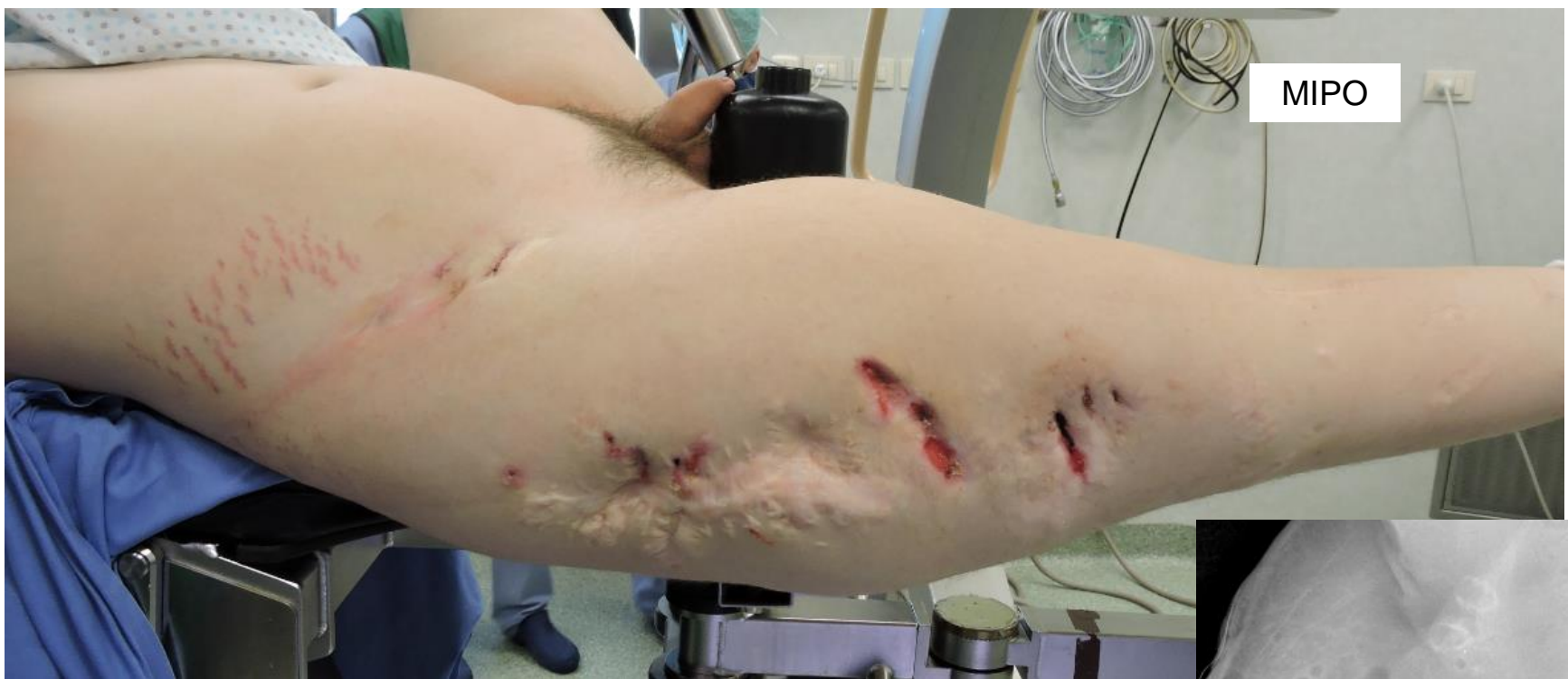AO

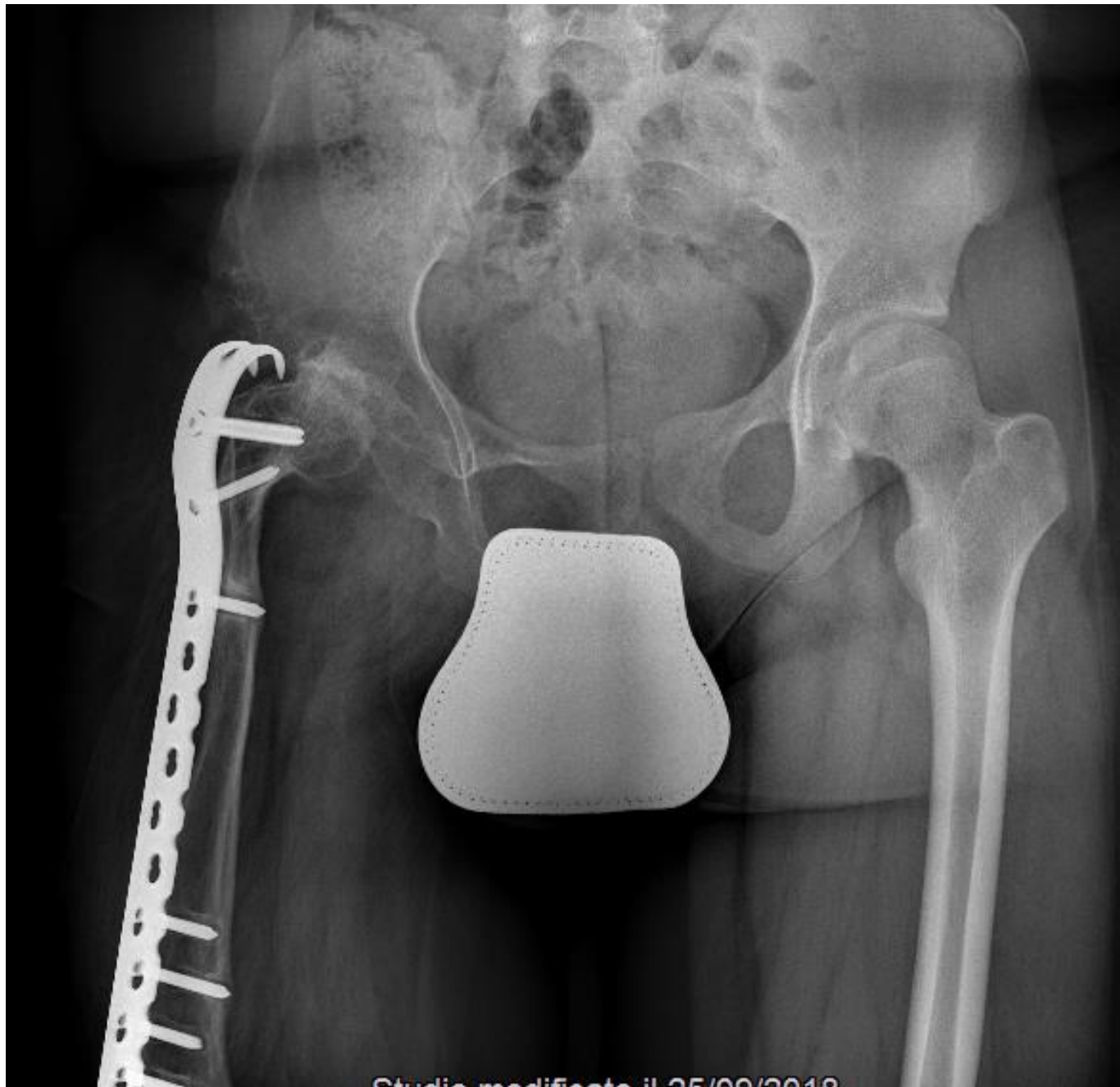

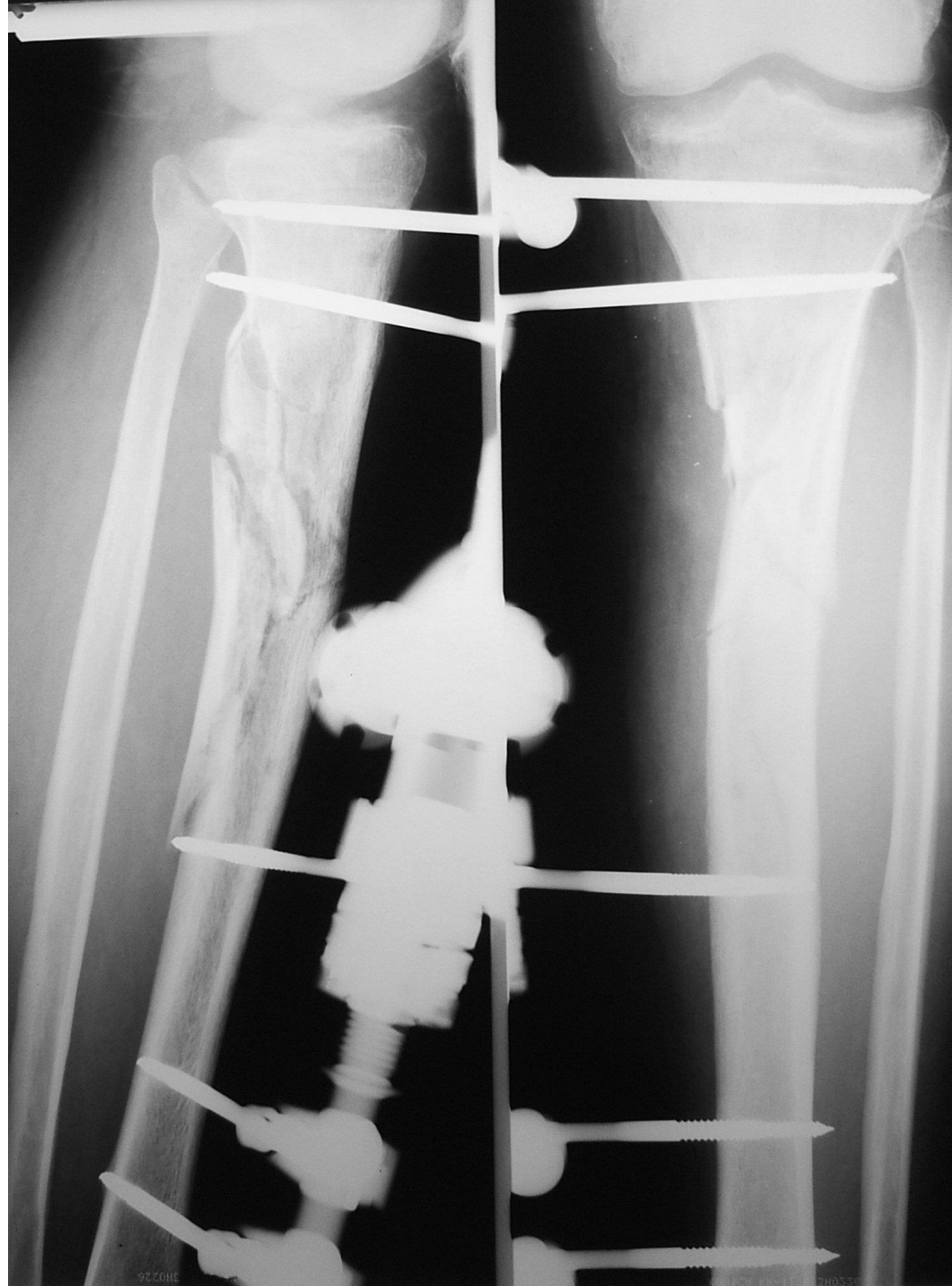AO



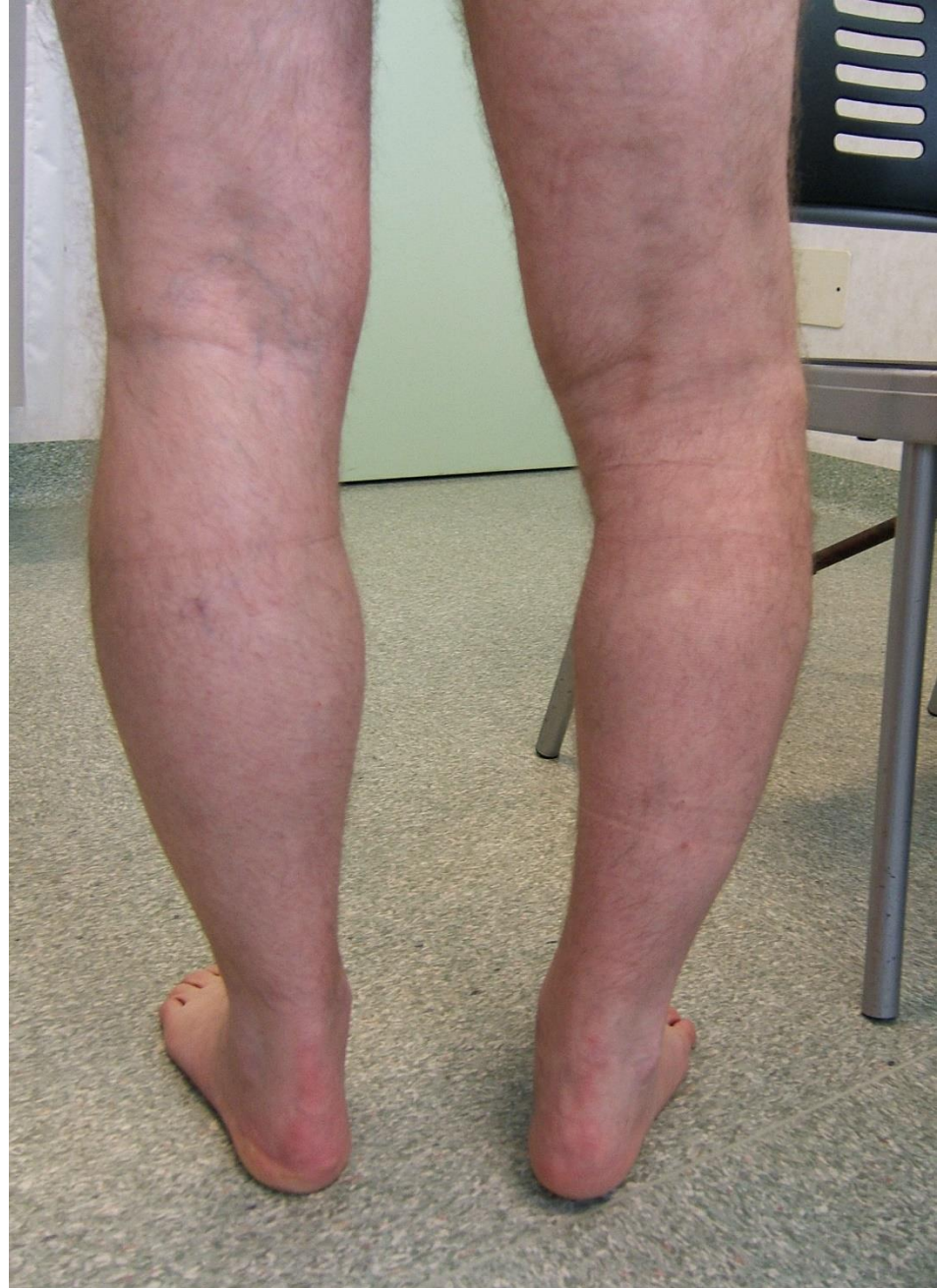
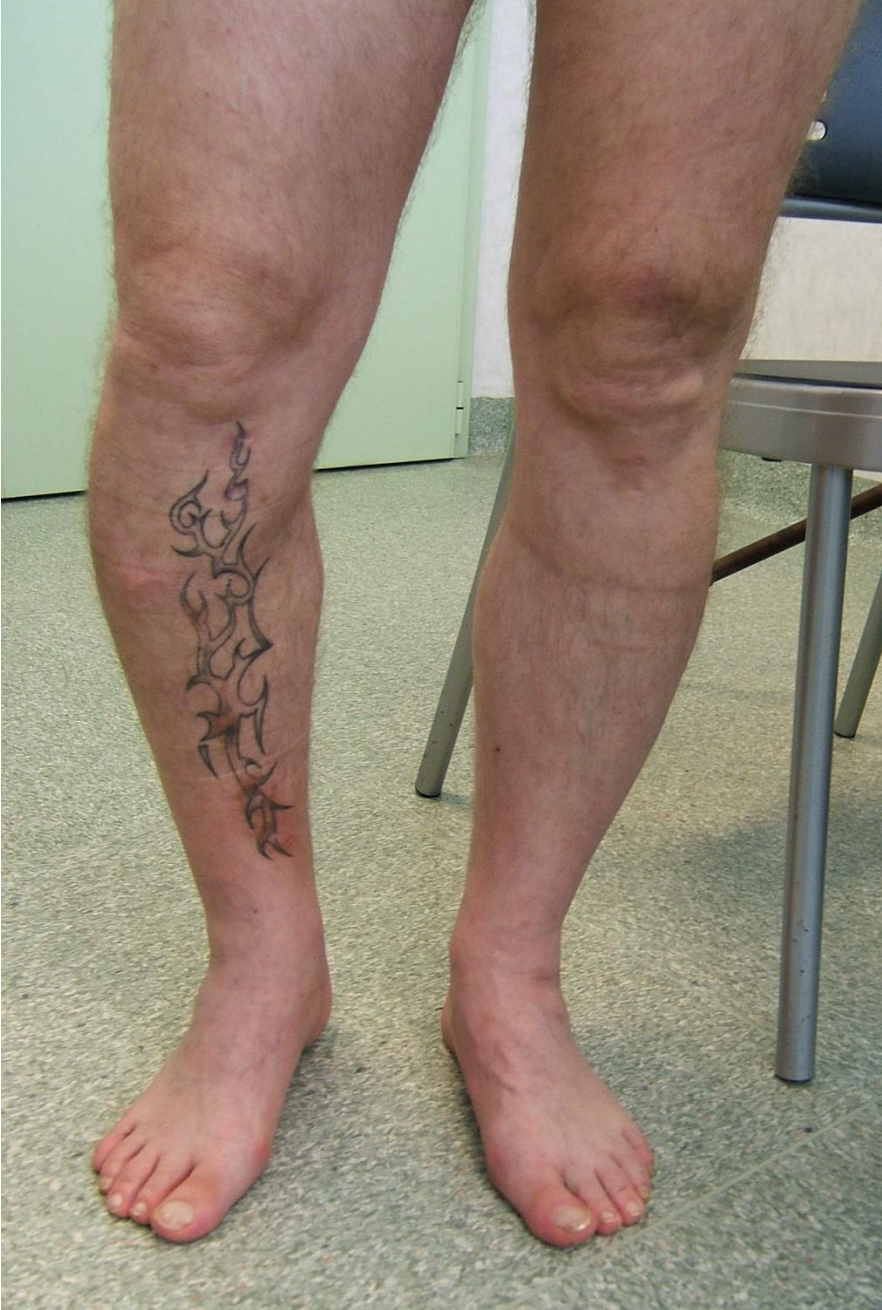
A 3 anni 2018

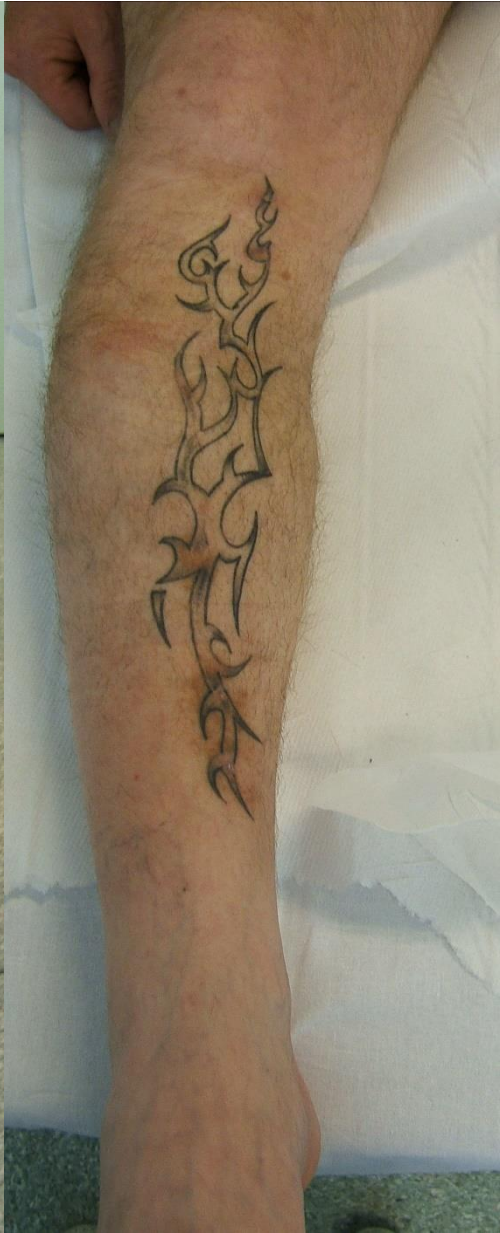
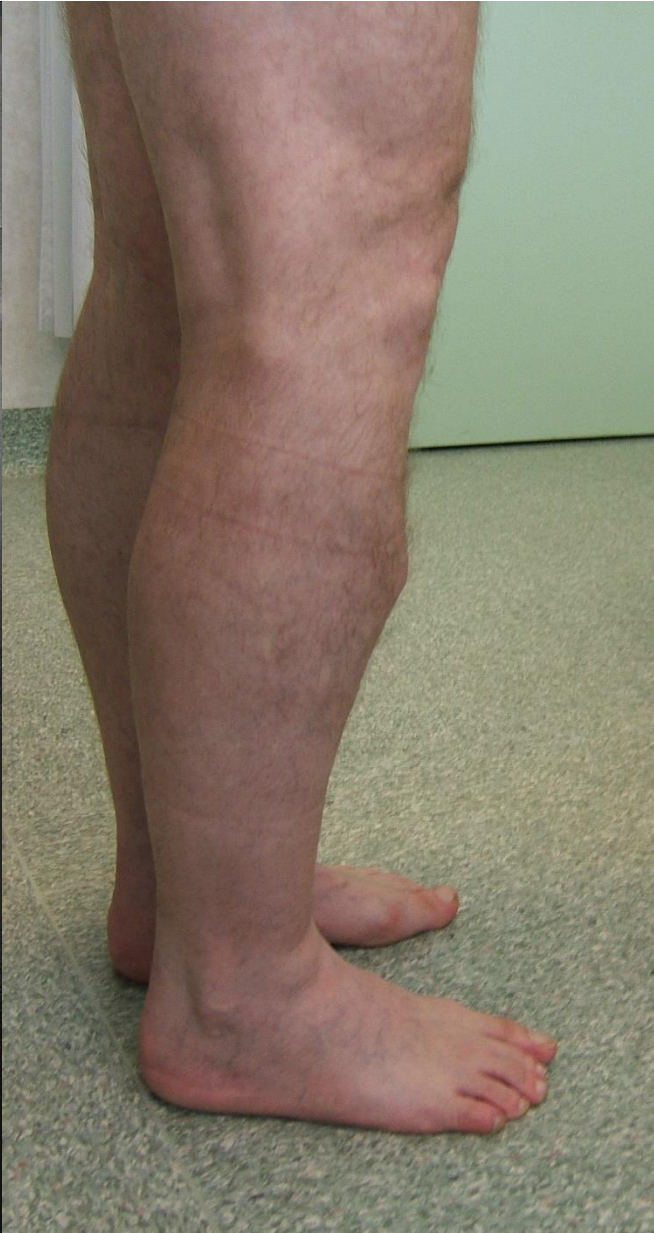
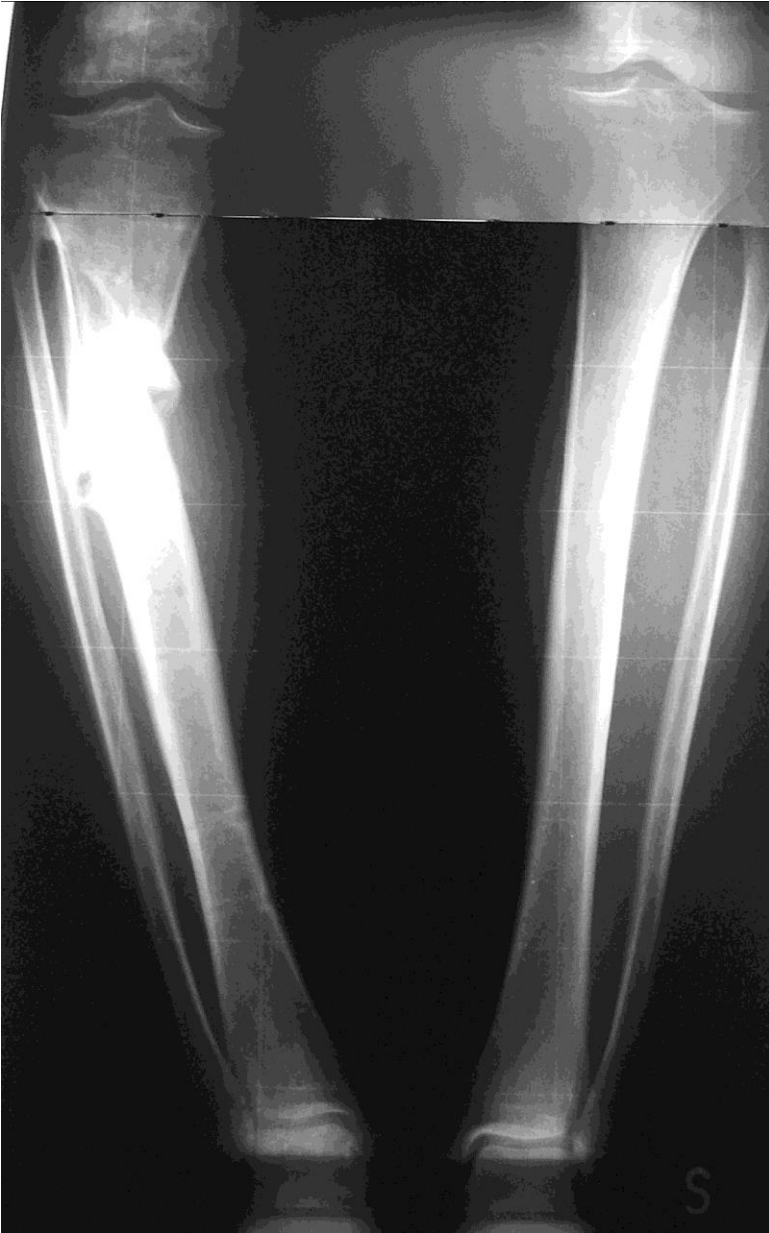

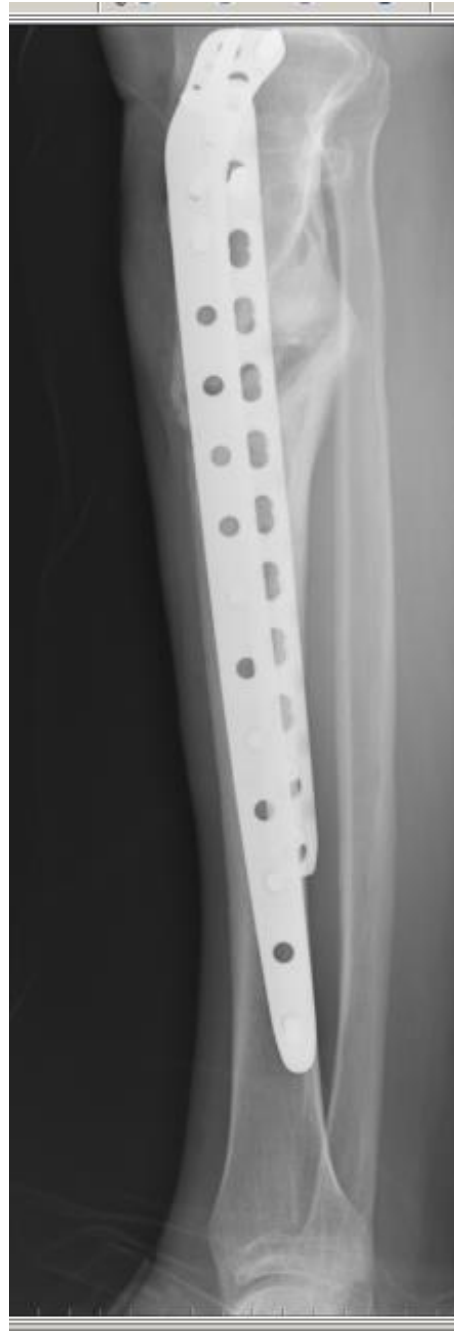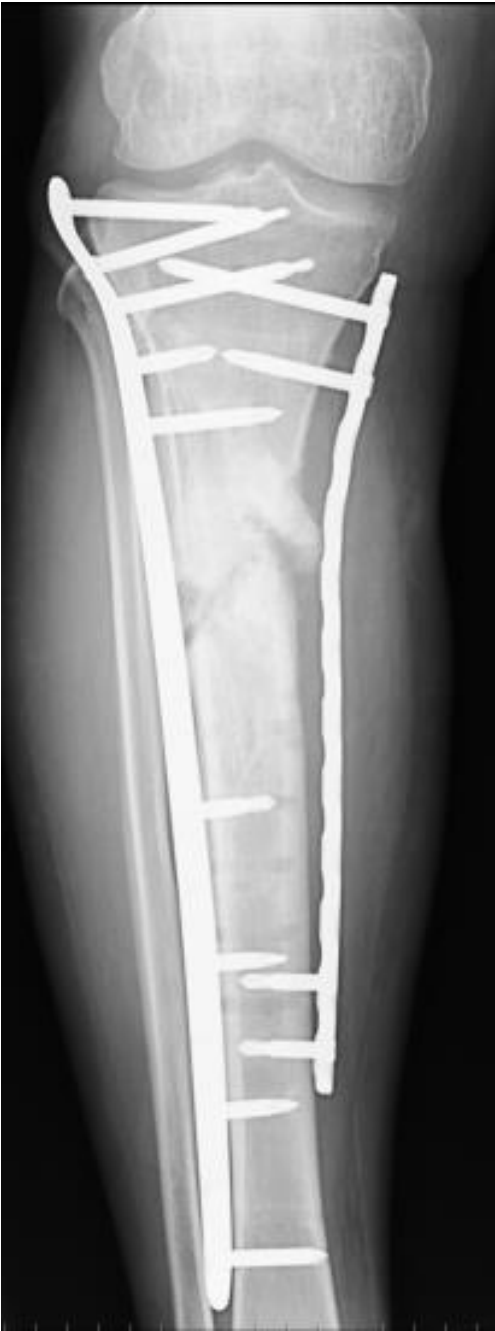**UOMO aa 35 mar
2006 exfix**

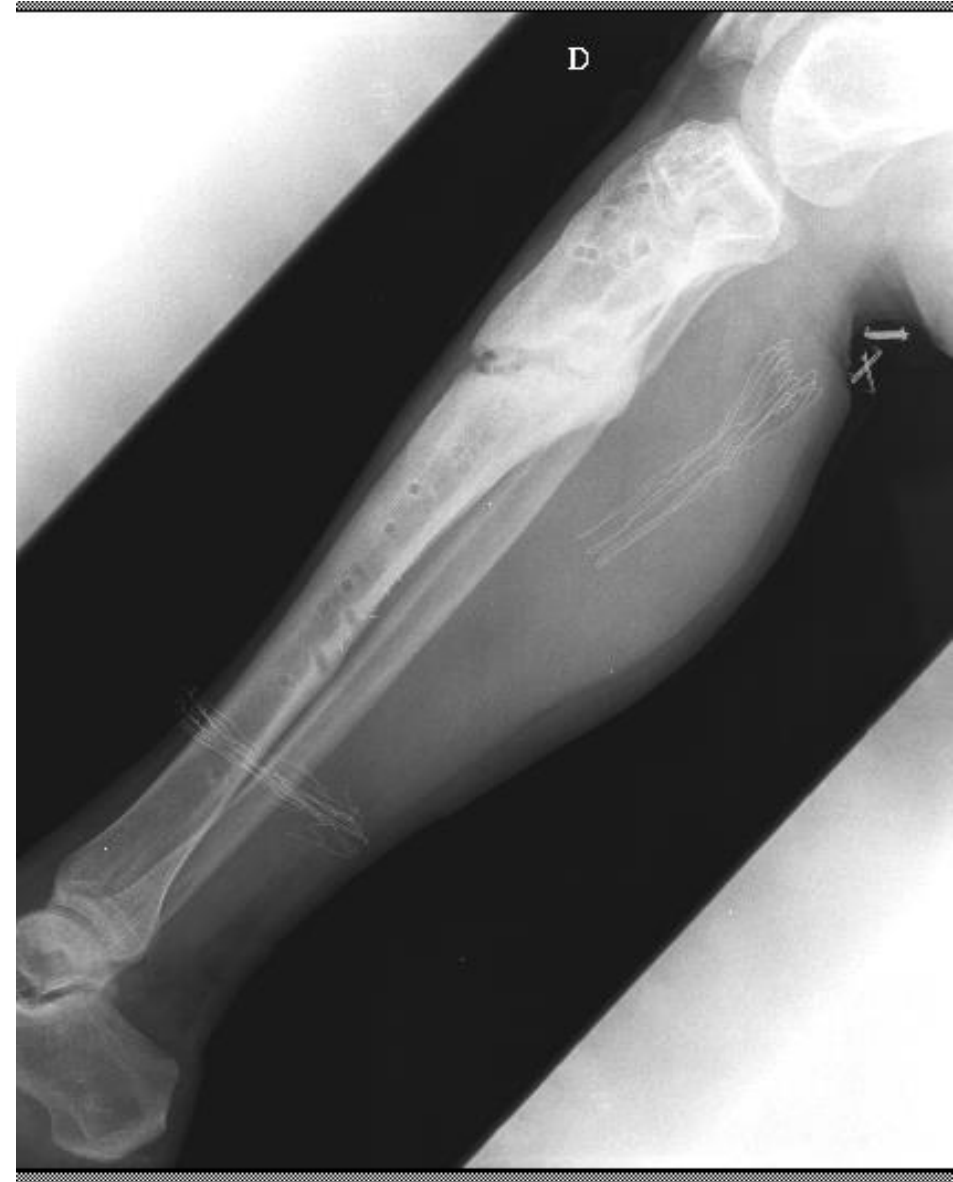
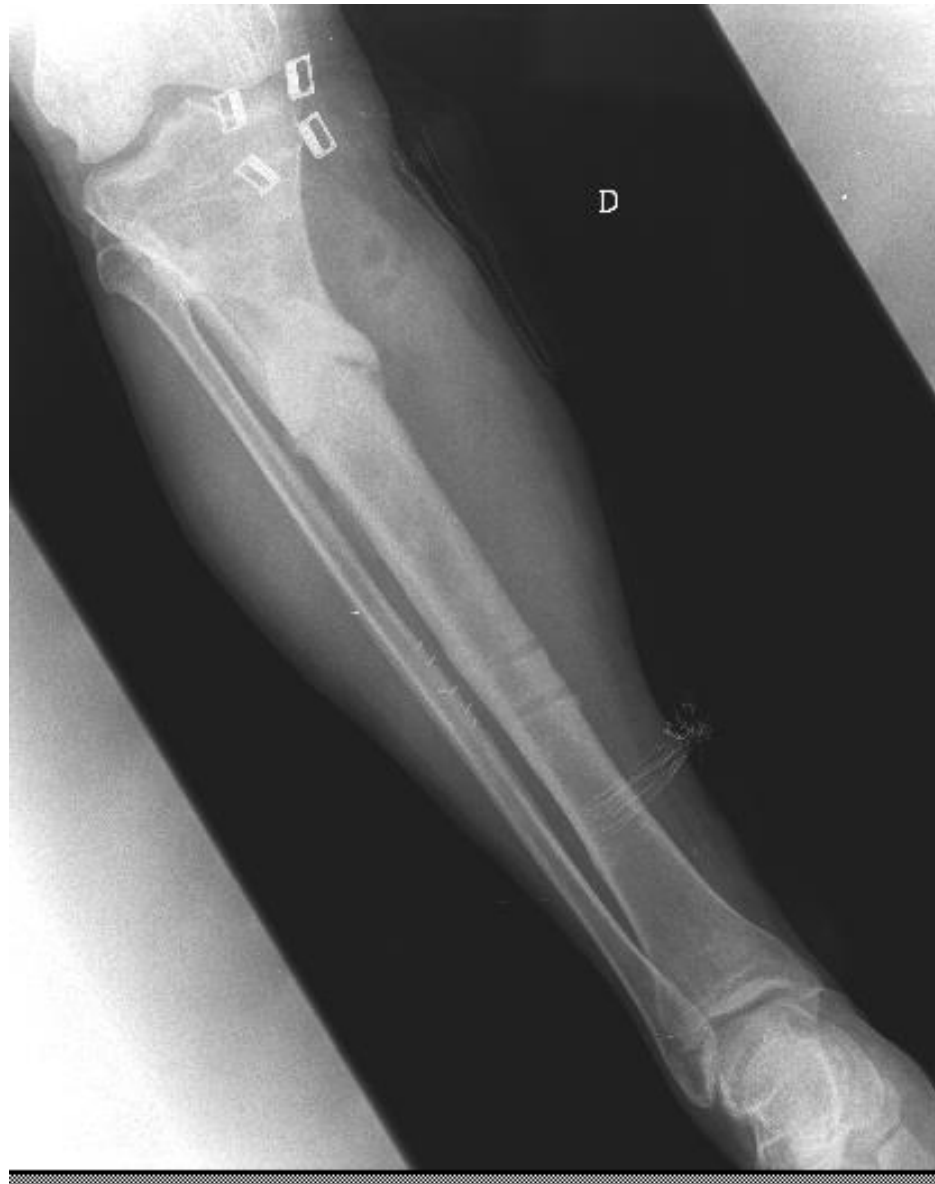
Rimosso exfix a 9 mesi pseudartrosi





Mar 2009 rimoz



**Attenzione ai tempi di consolidazione in
relazione alla patologia di base**

**Non vi sono fallimenti se i
principi e i dettagli di tecnica
vengono rispettati**

**La correzione di un fallimento
della fissazione esterna è spesso
complessa**