



ORTHOPEDIC & SPINE INSTITUTE
at St. Mary's Medical Center

Acute Deformity Correction with Lengthening using PRECICE nail

Dror Paley, MD, FRCSC

CEO, Founder & Director

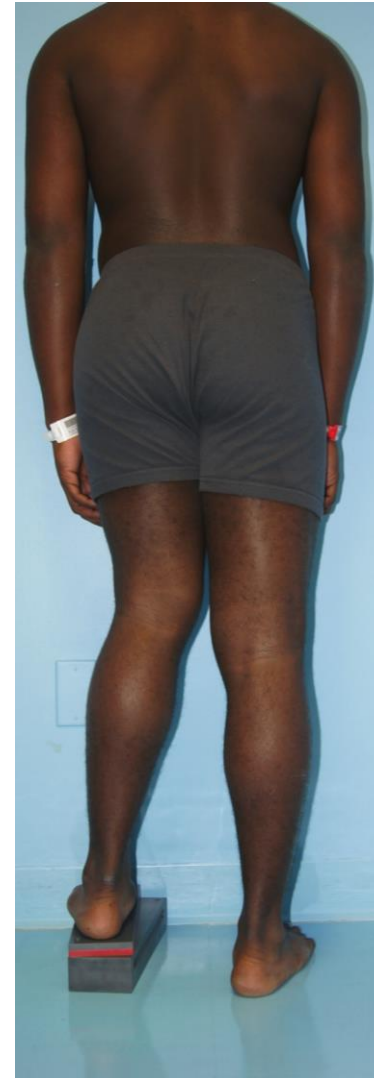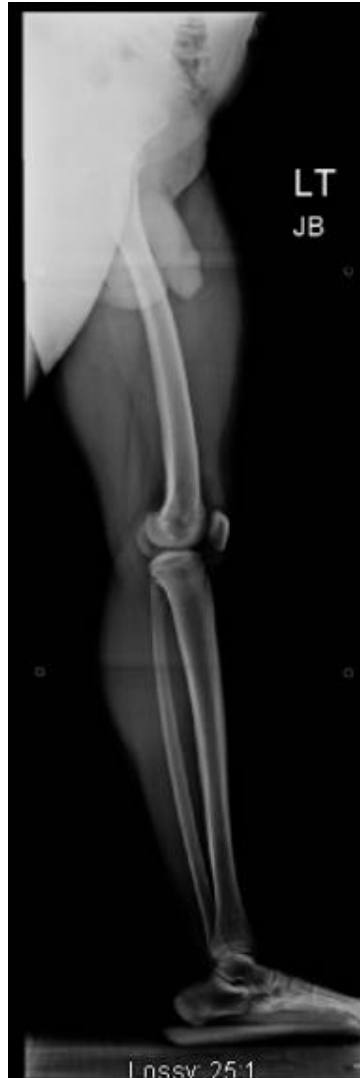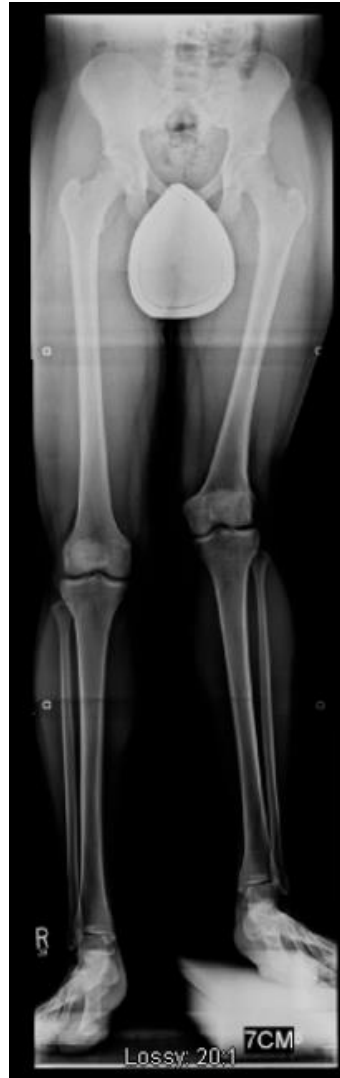Paley Orthopedic & Spine Institute

St. Mary's Medical Center, West Palm Beach, Florida, USA

Professor of Orthopedics, Florida Atlantic University

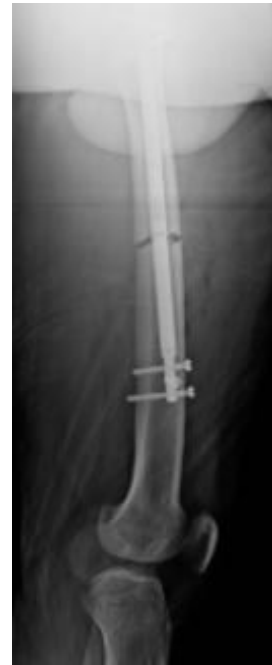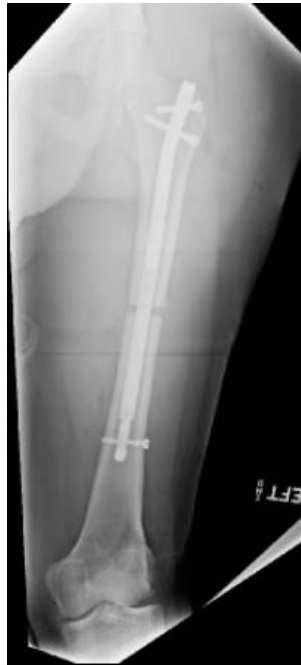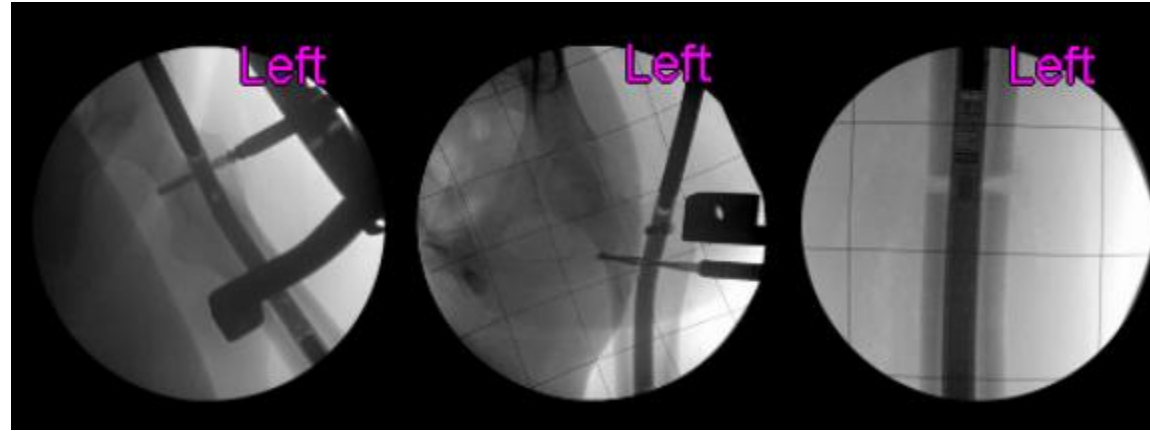


16 y.o. boy; Post-traumatic Growth Arrest



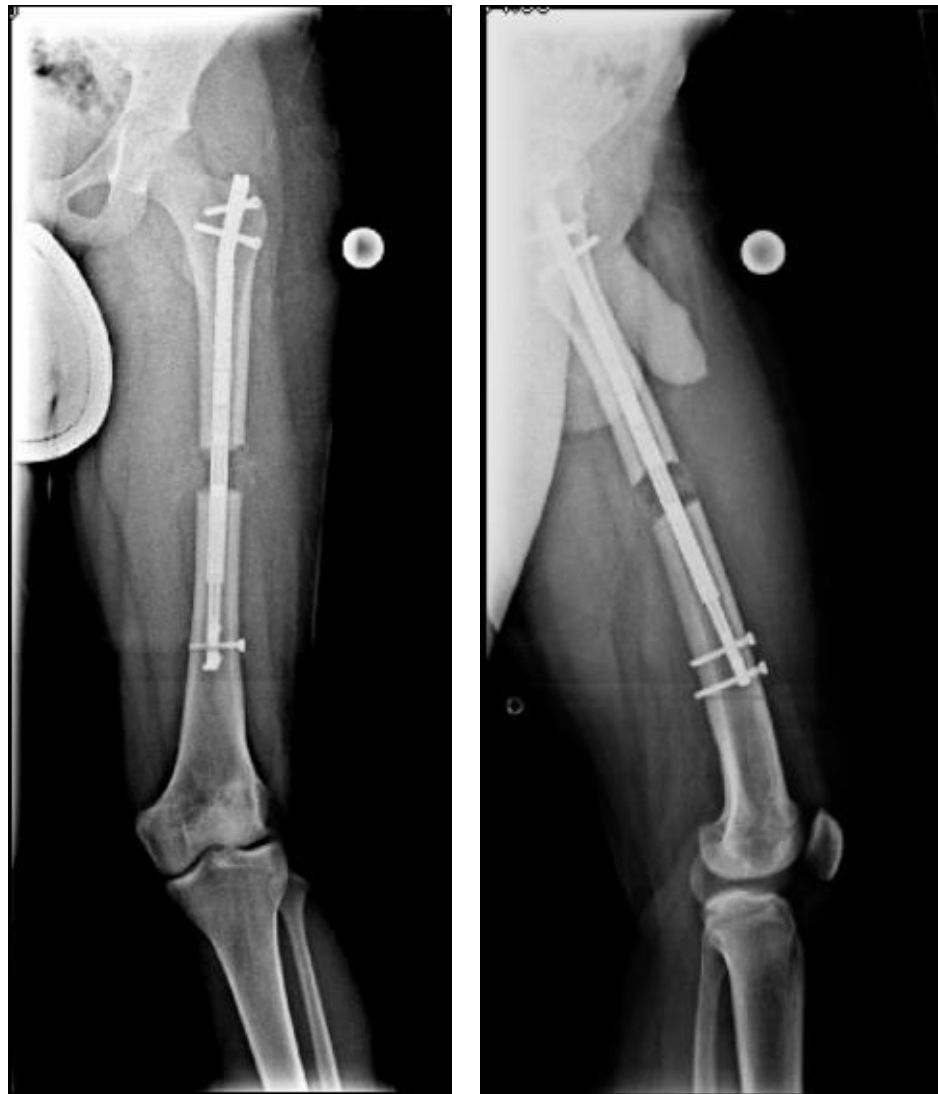June 14, 2010

Trochanteric entry, lengthening of fascia lata, biceps tendon lengthening



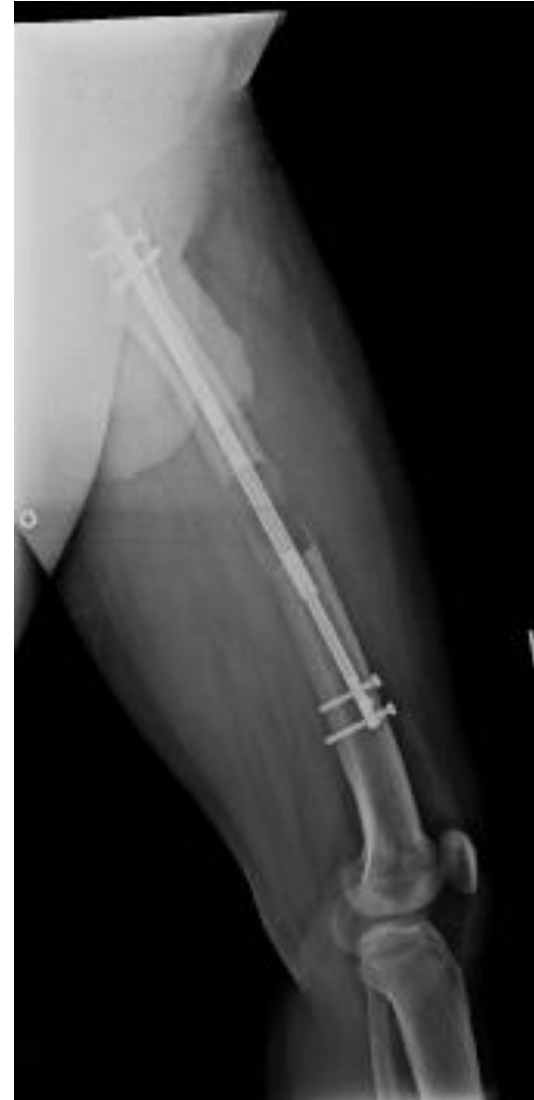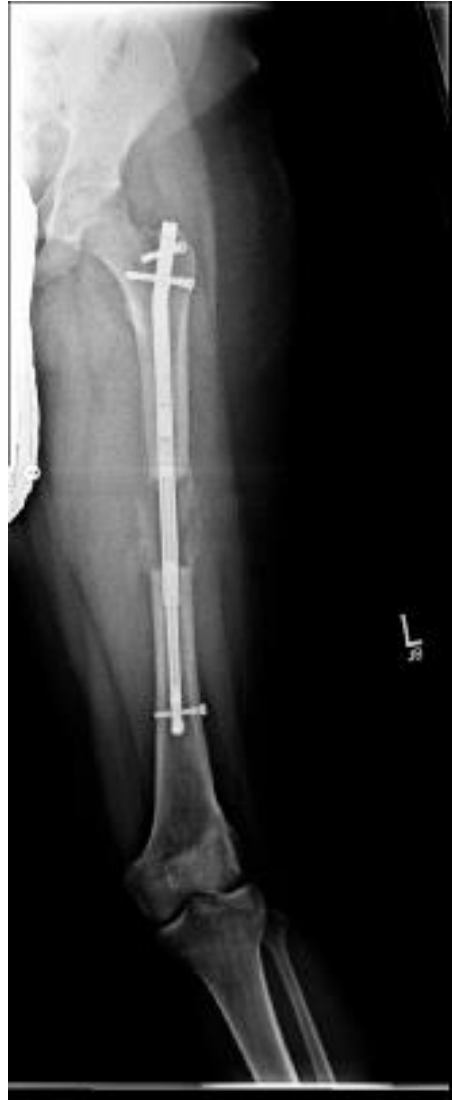Dec 1, 2011: First US Precice Case

4 week Follow up



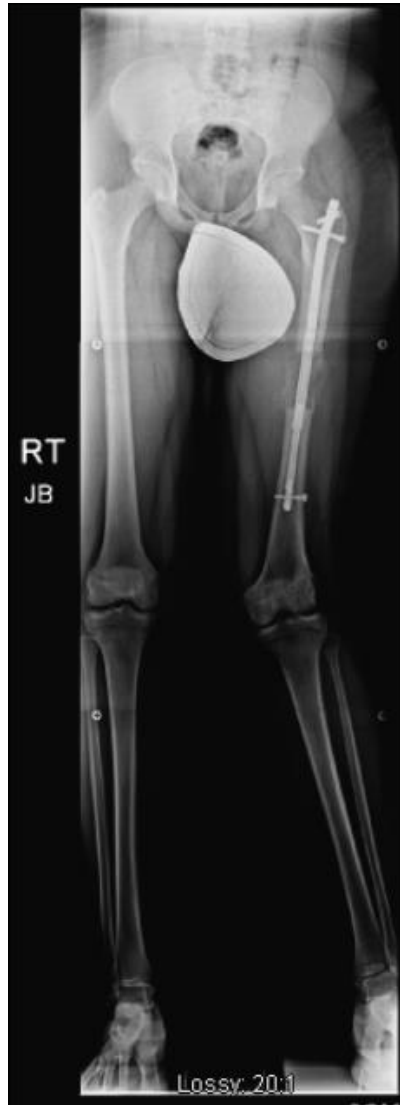Dec 27, 2011

8 week Follow up x-rays: 6.5cms

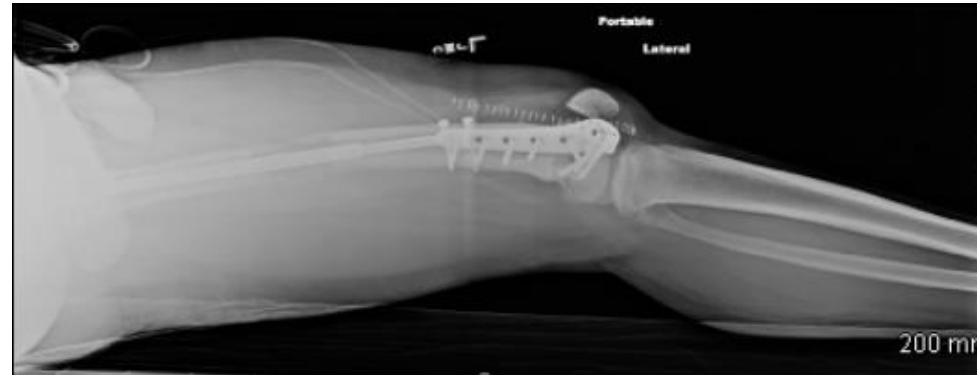
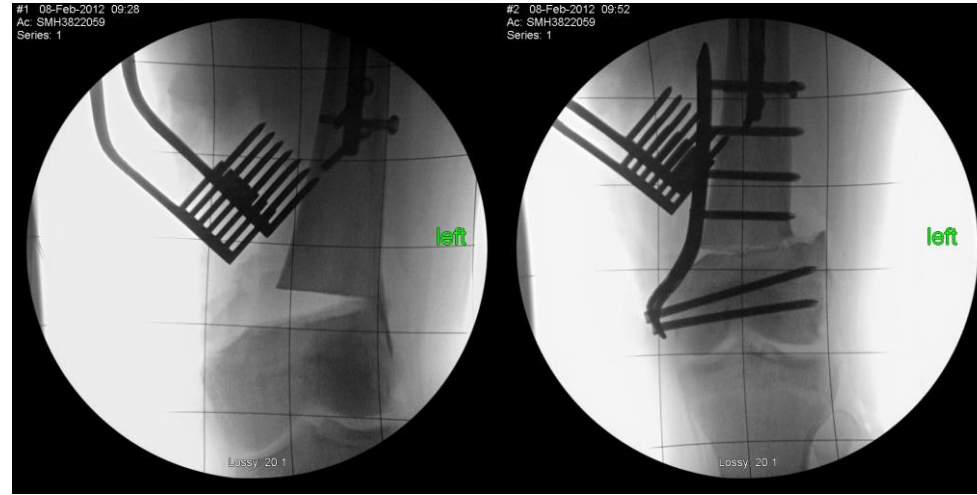
Jan 31, 2012

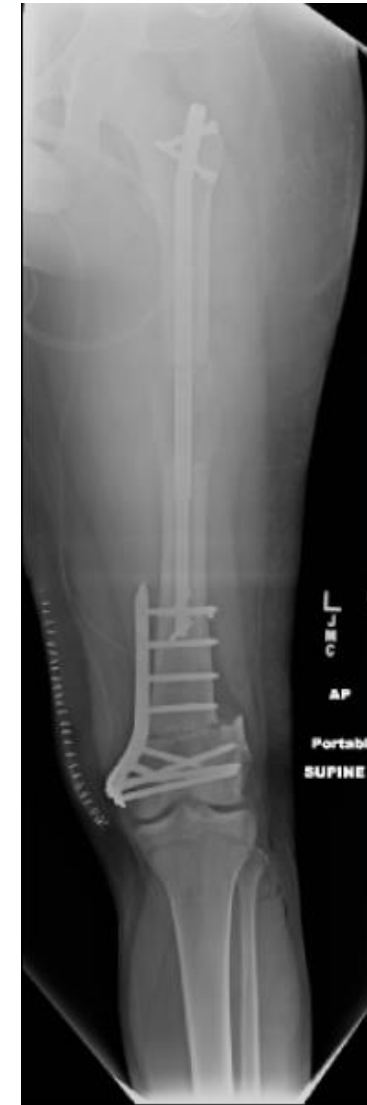Varus closing wedge osteotomy distal femur; decompression peroneal nerve



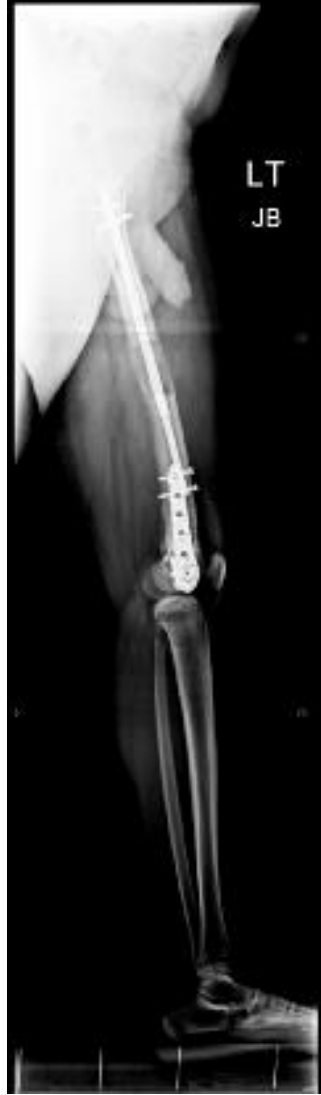
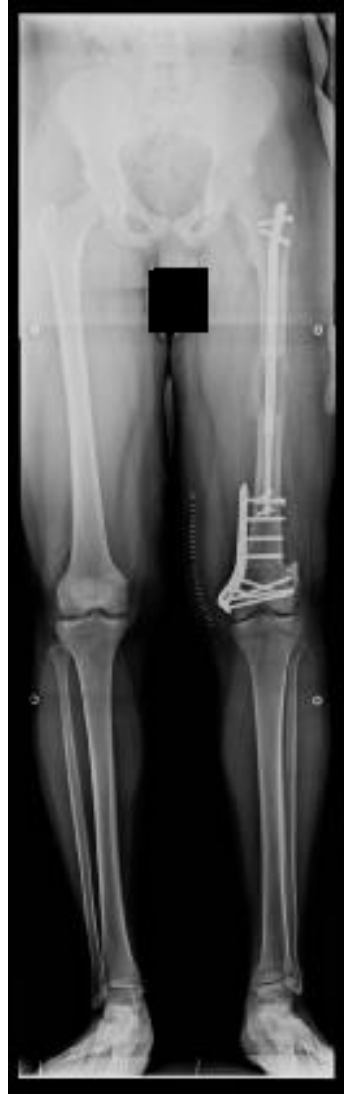Feb 7, 2012



Feb 8, 2012

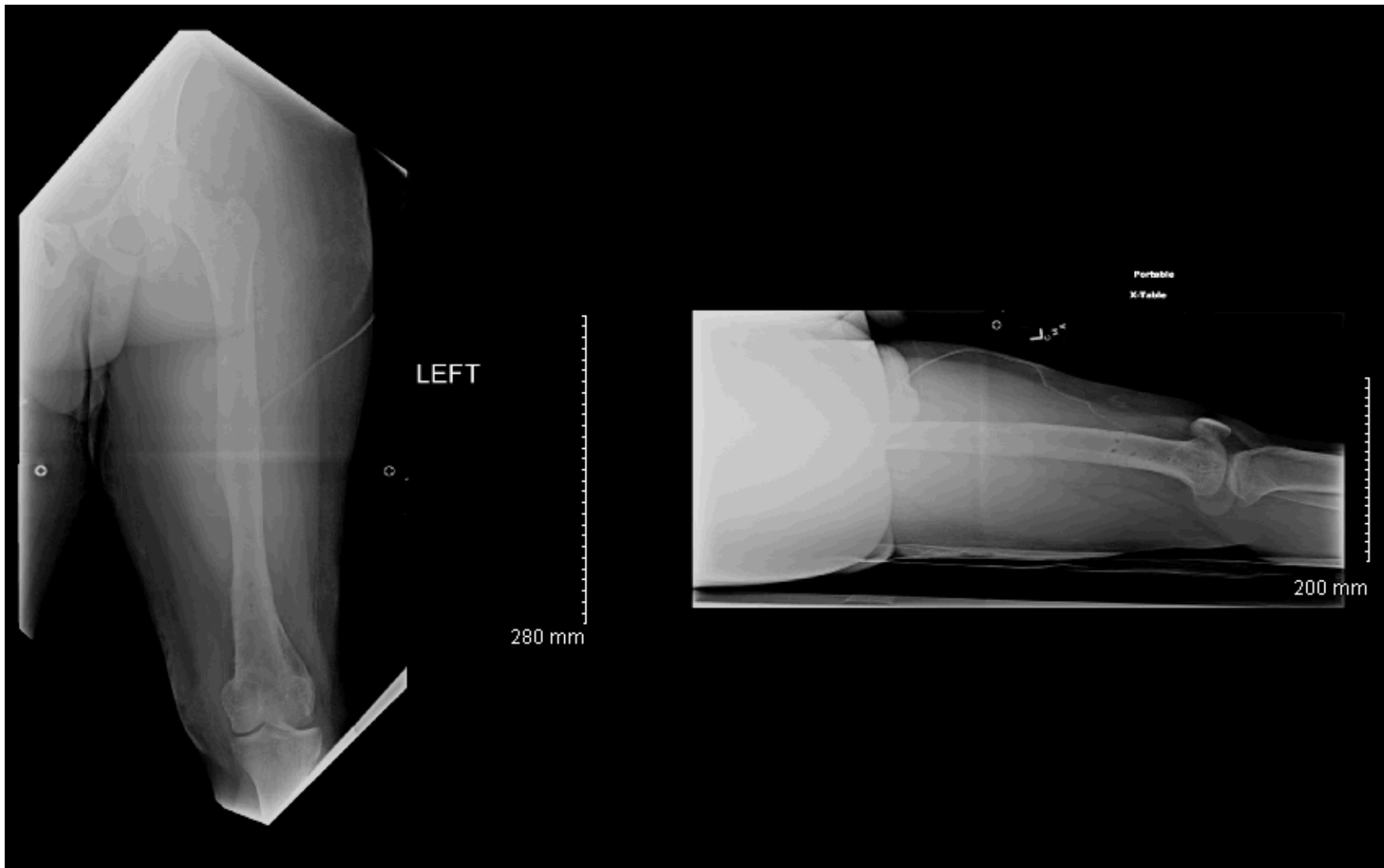


Final Alignment: 3 months post op



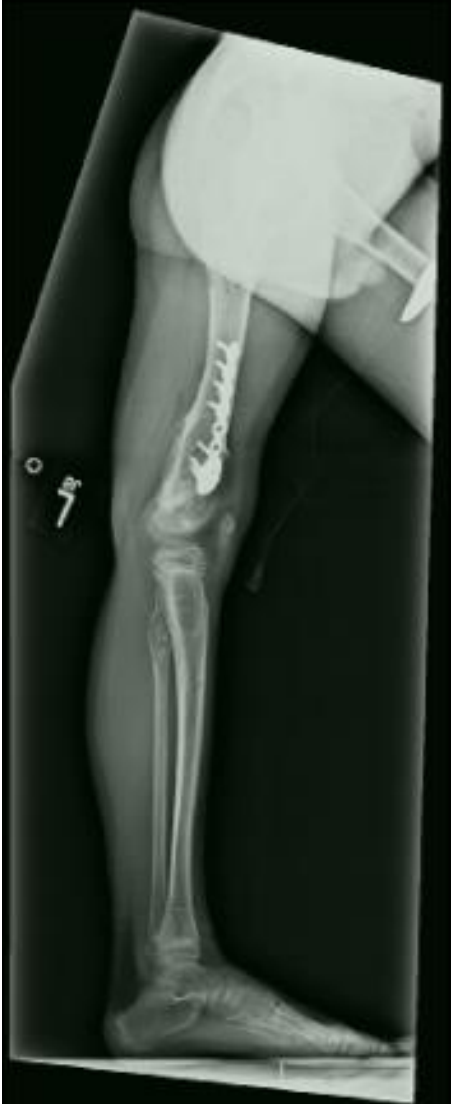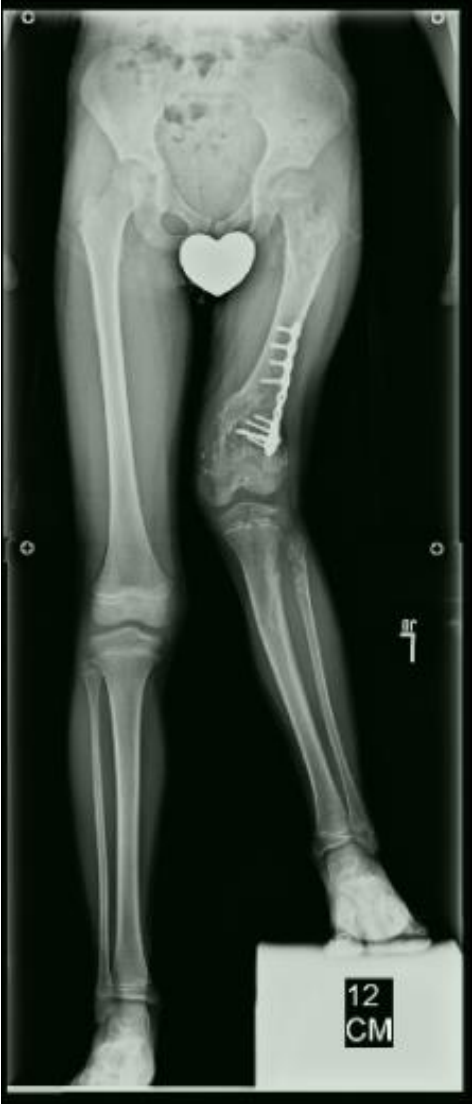March 1, 2012

Implant Removal: 19 months later



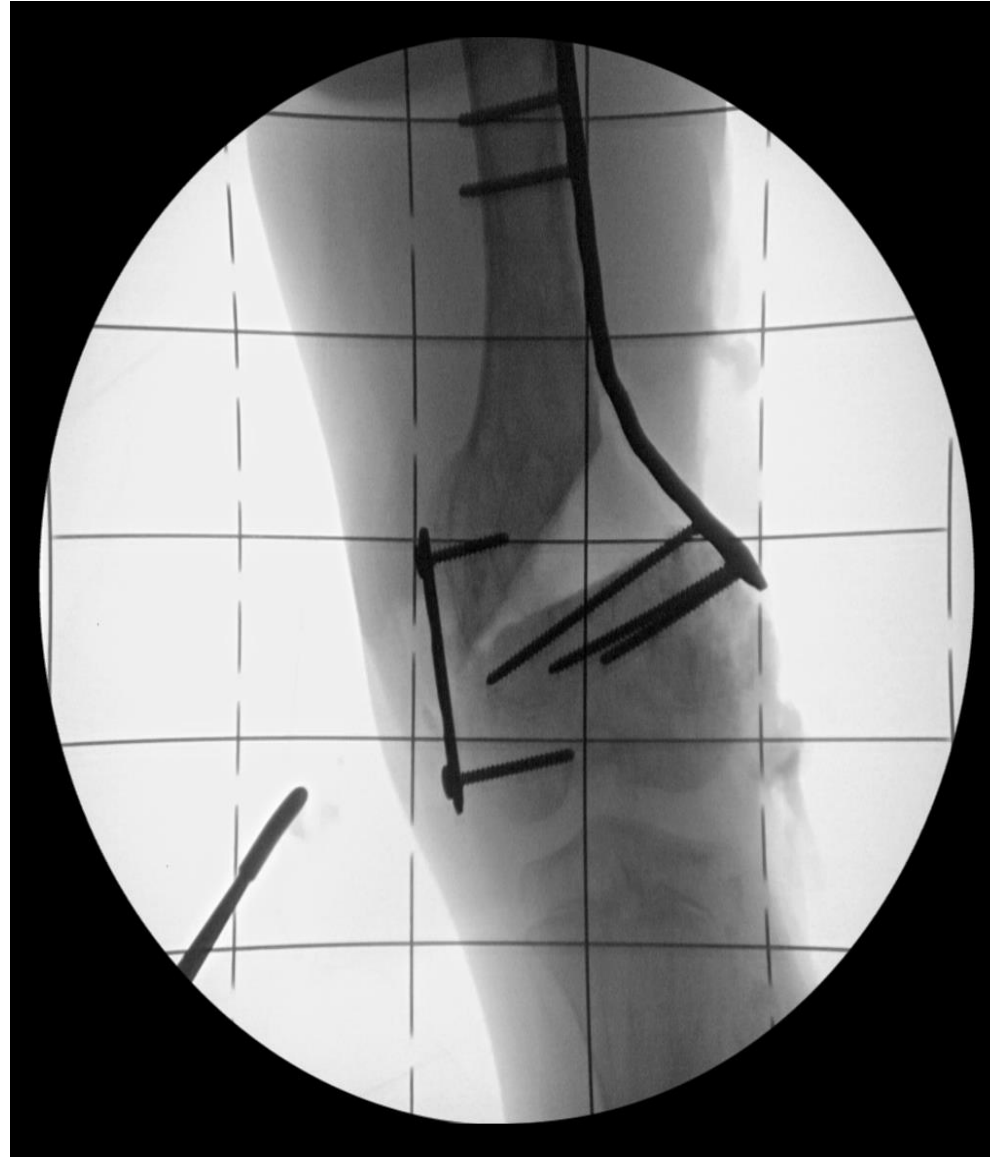July 22, 2013

Ollier's Disease: Severe Genu Valgum and LLD

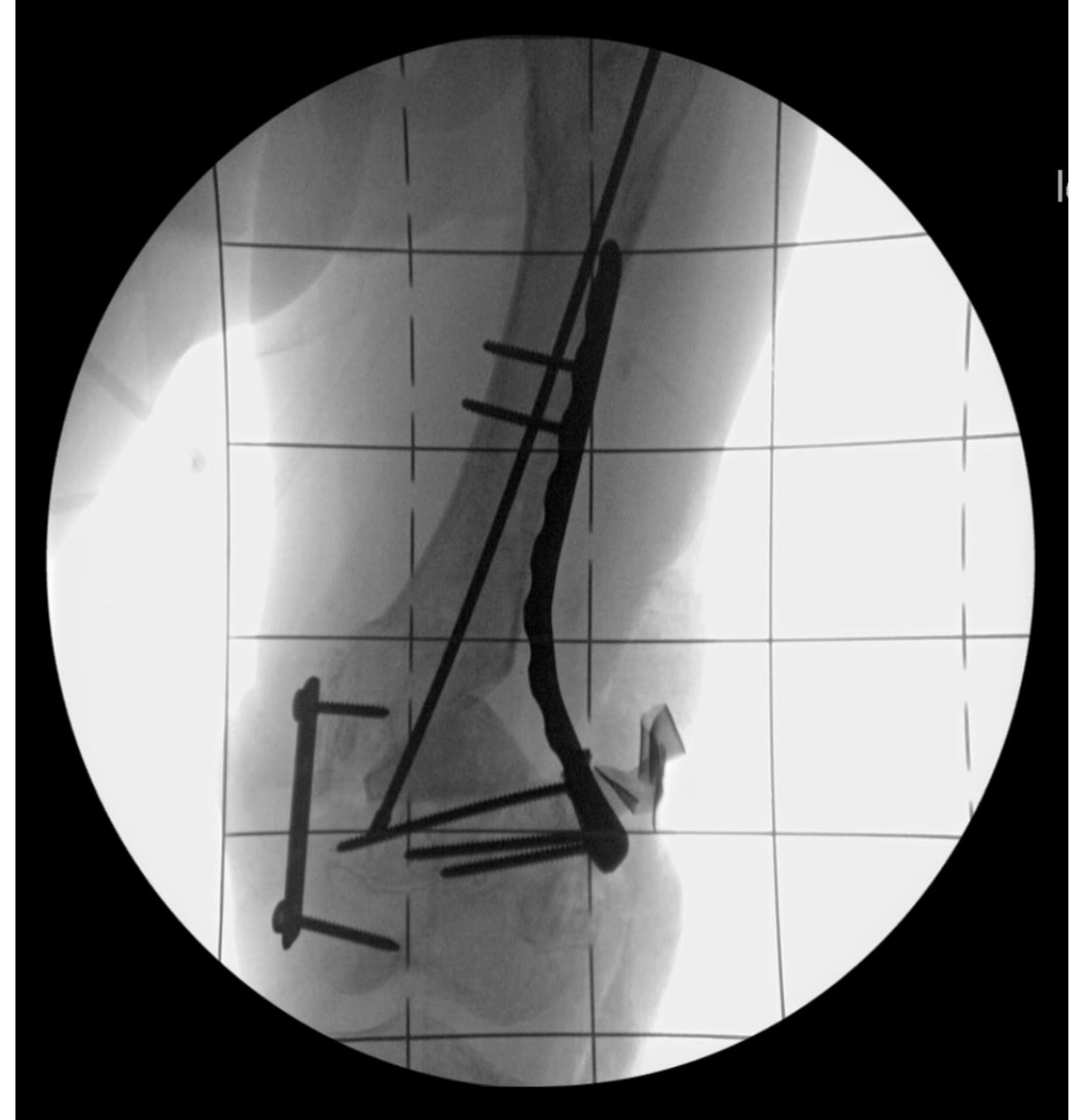
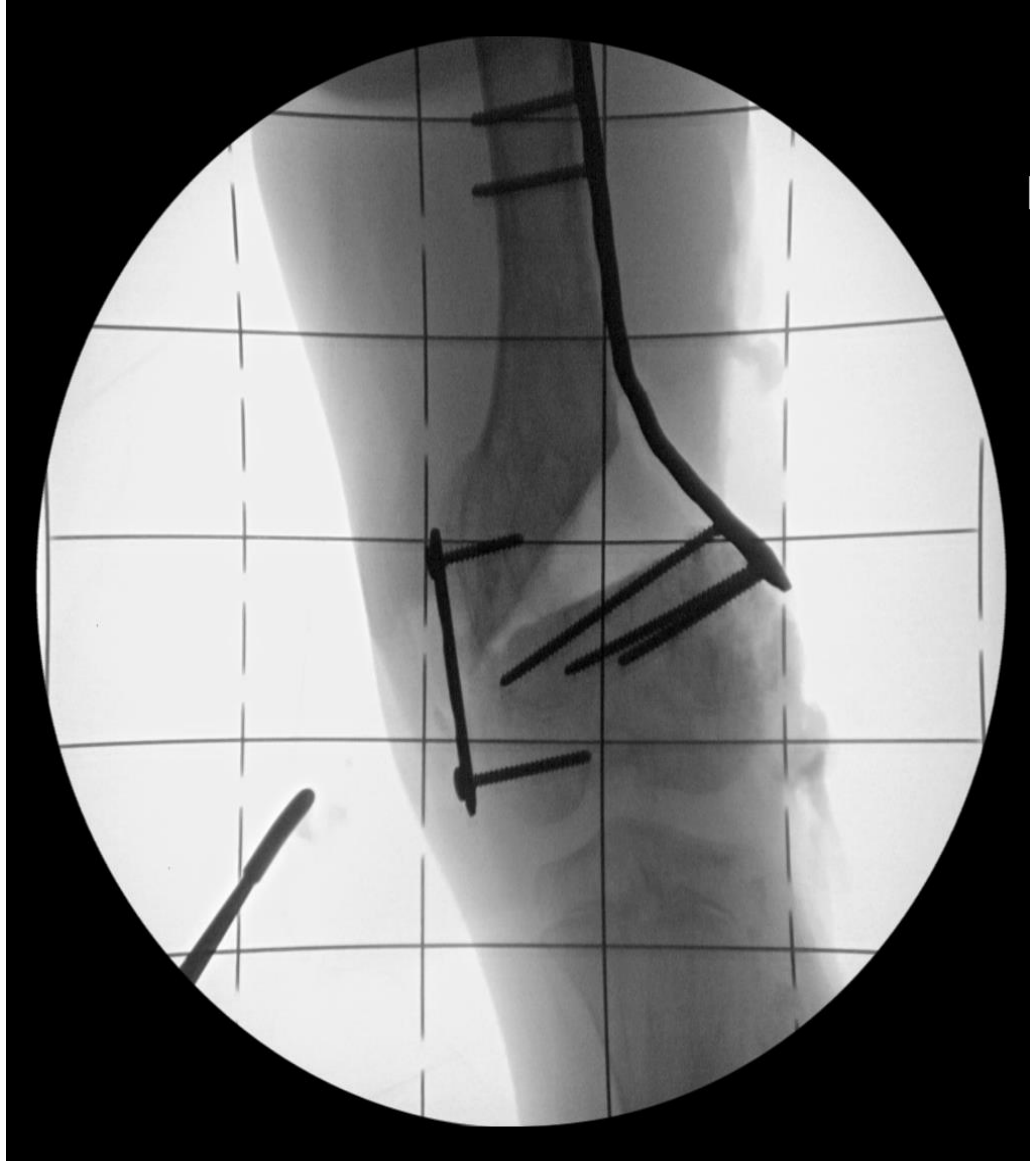
Dec 19, 2014

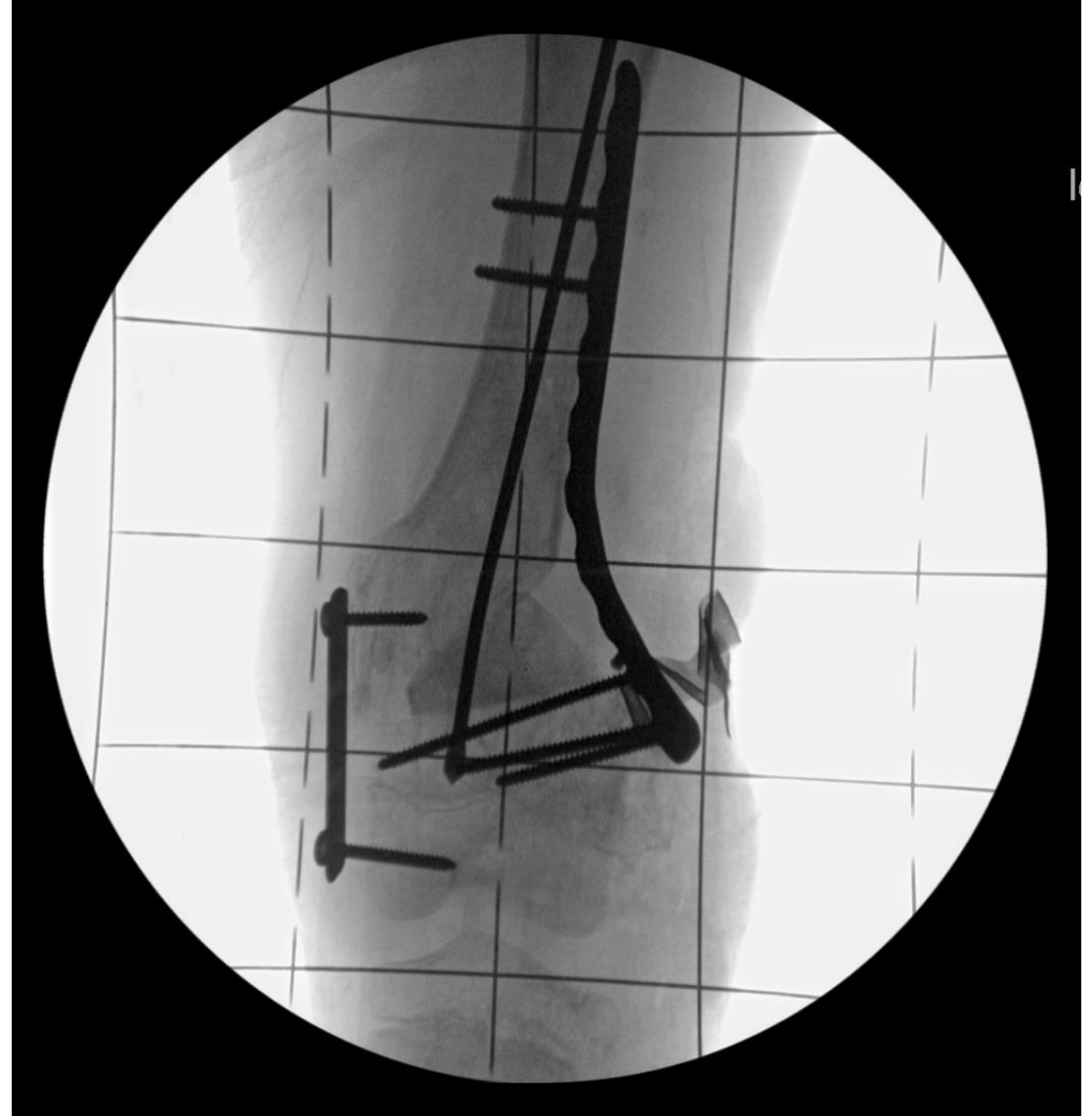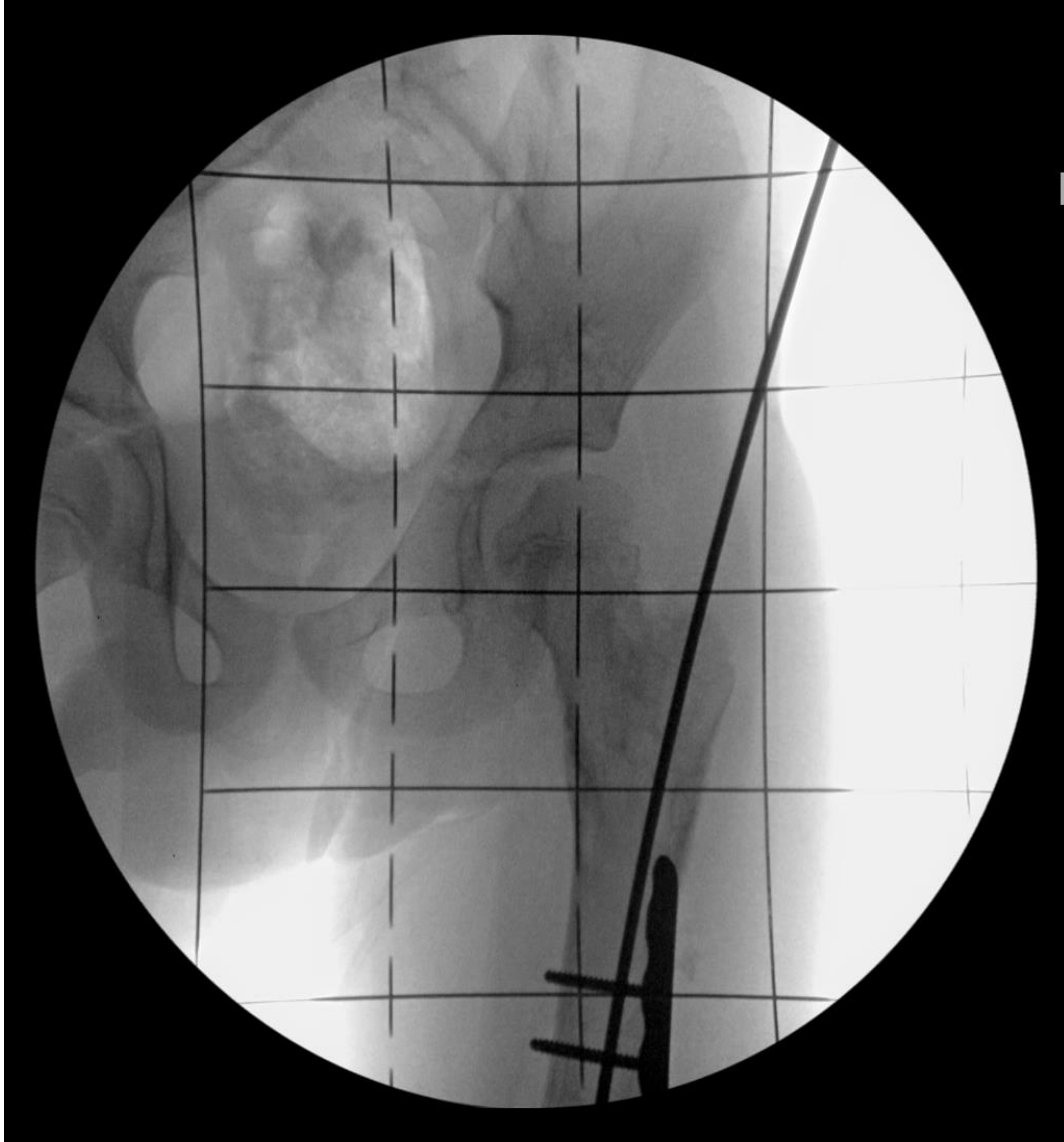Acute Lateral Opening Wedge & Medial Hemi-epiphysiodesis



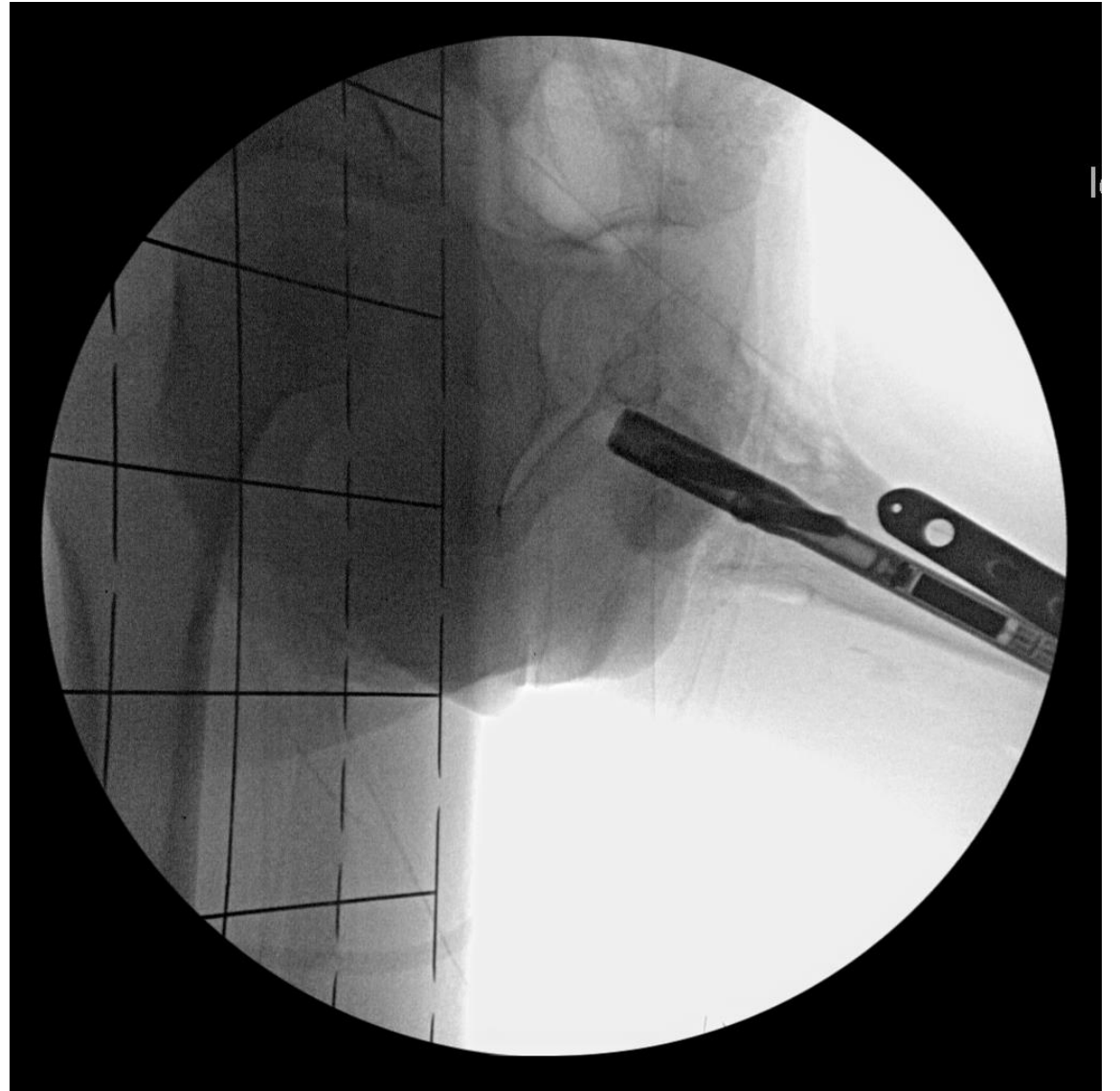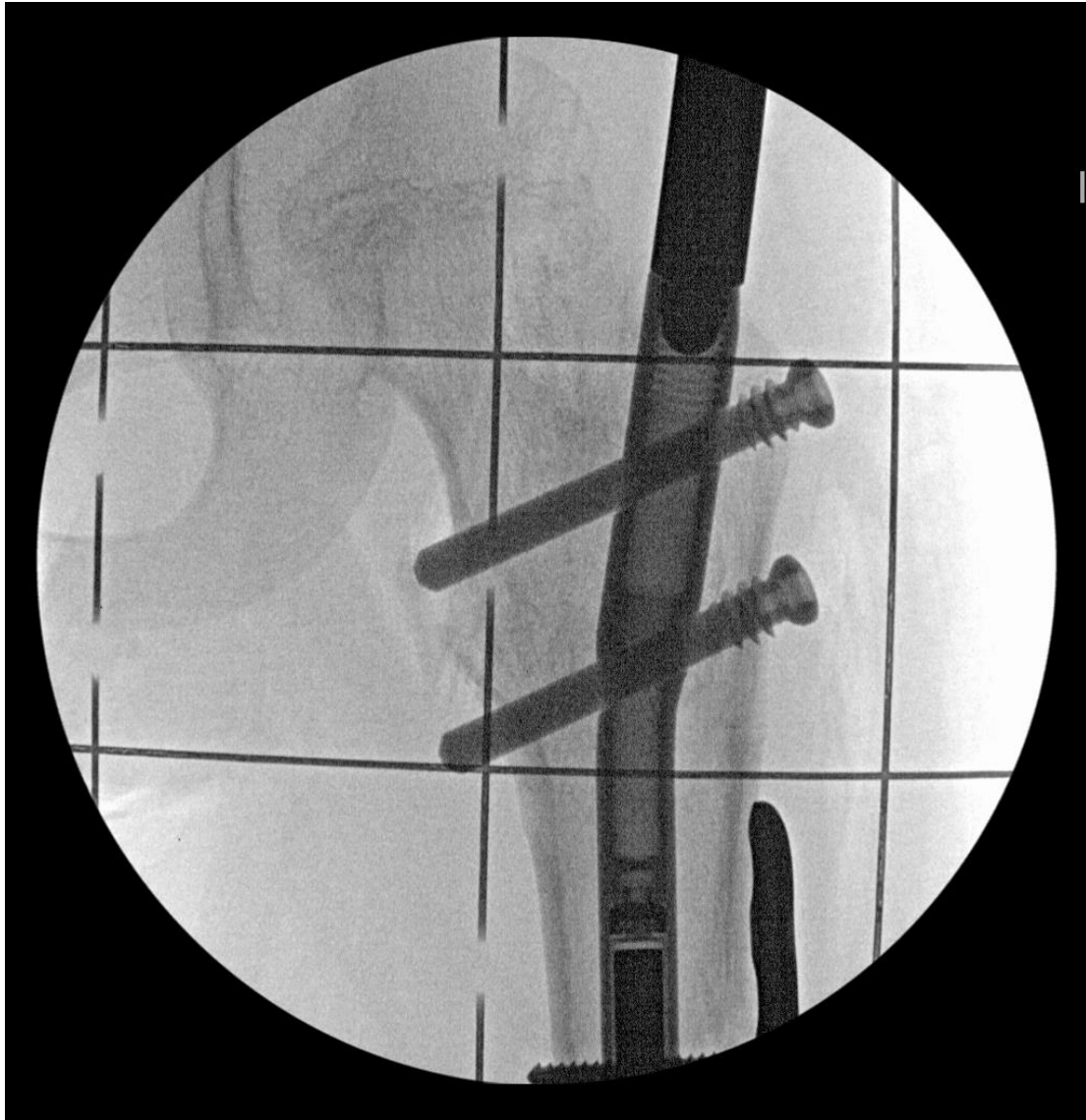Acute Lateral Opening Wedge & Allograft



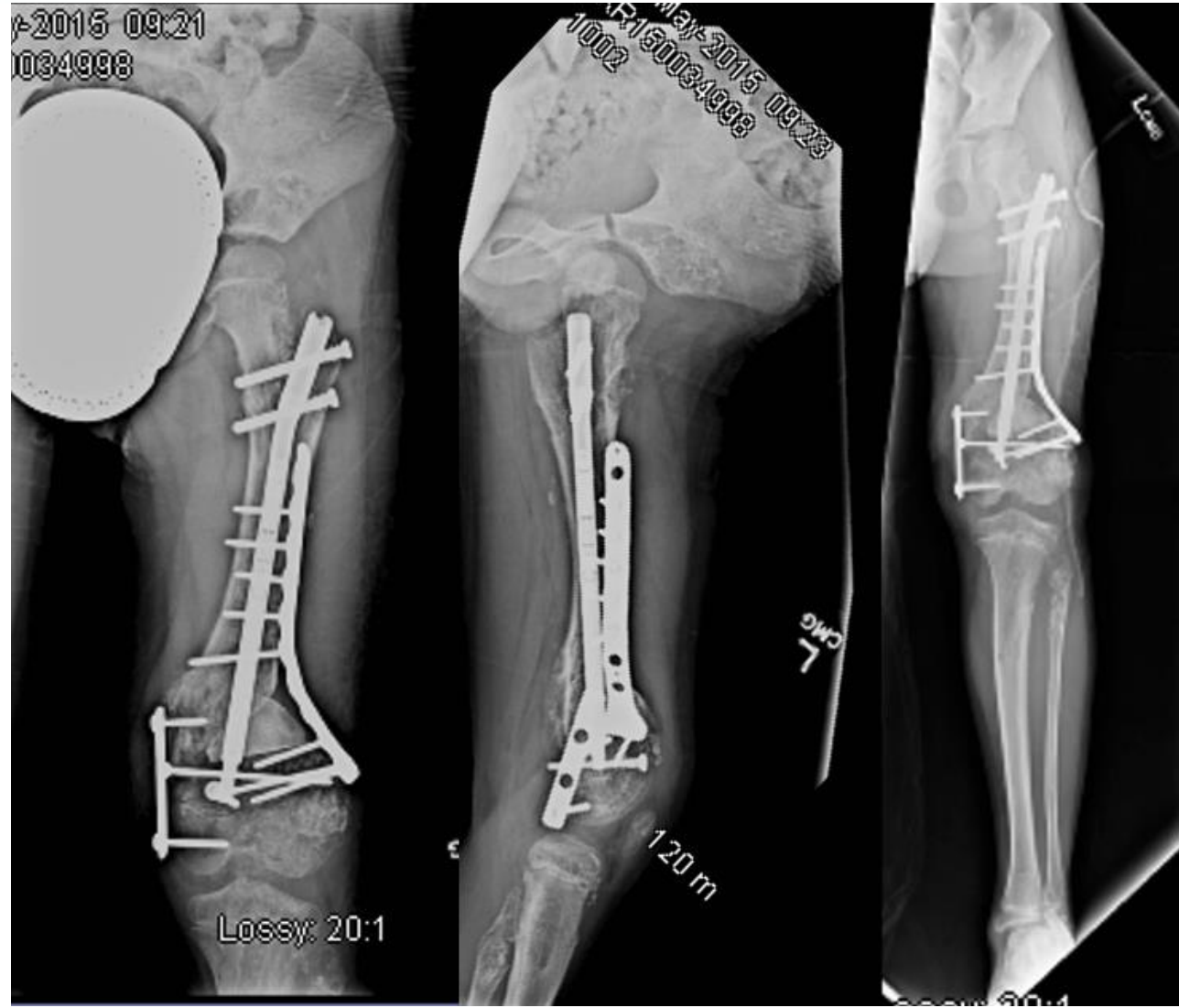
Guide Rod for Nailing



Trochanteric Entry

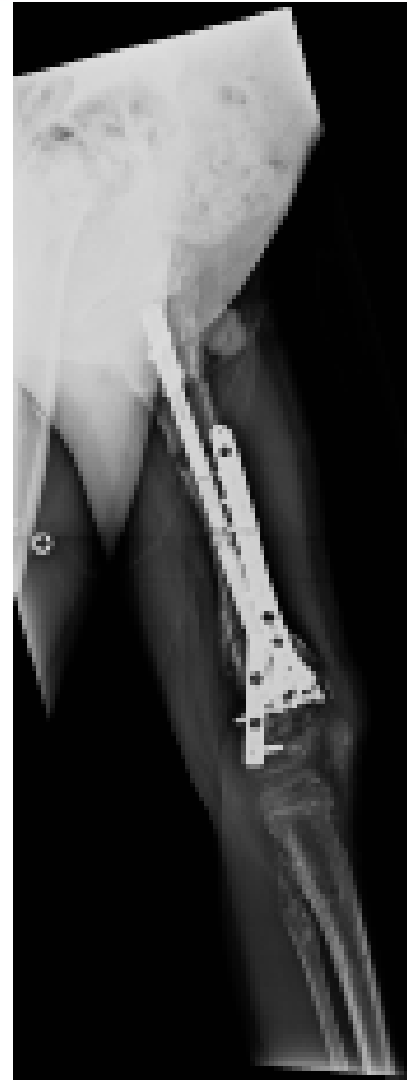
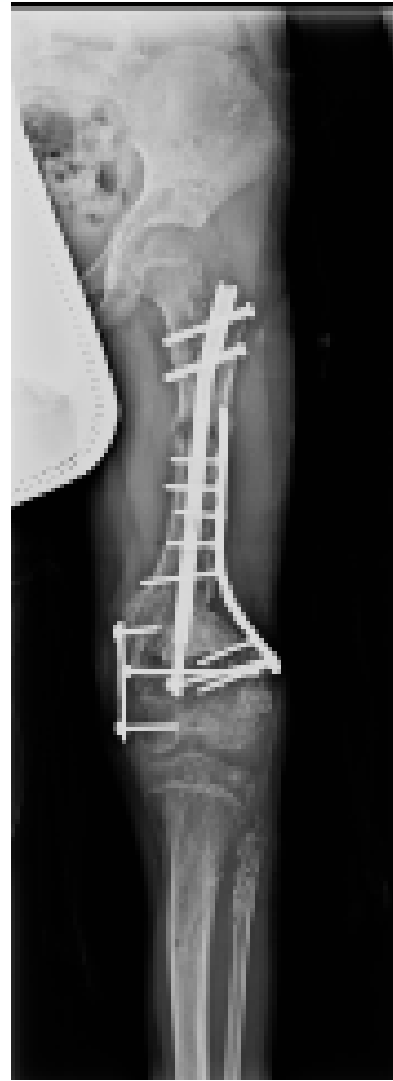
Post-Op x-rays



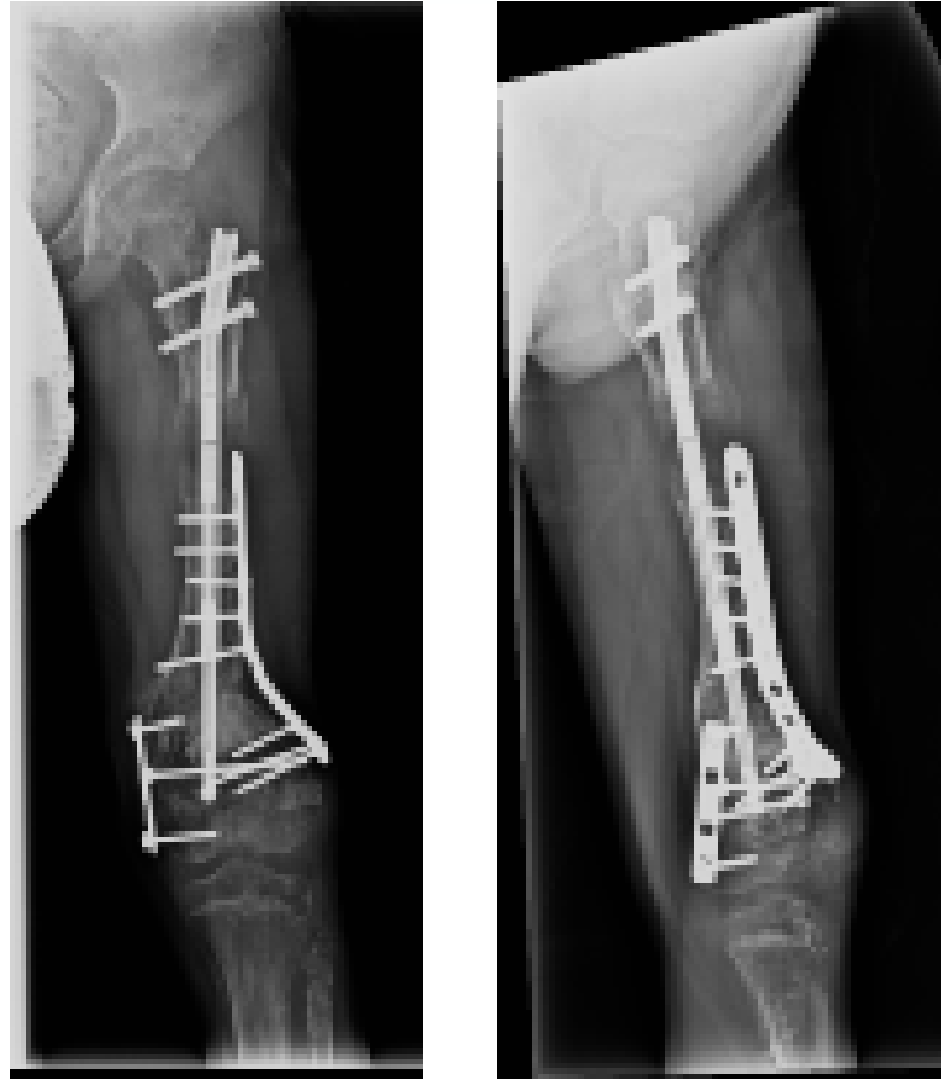May 6, 2015

Lengthening



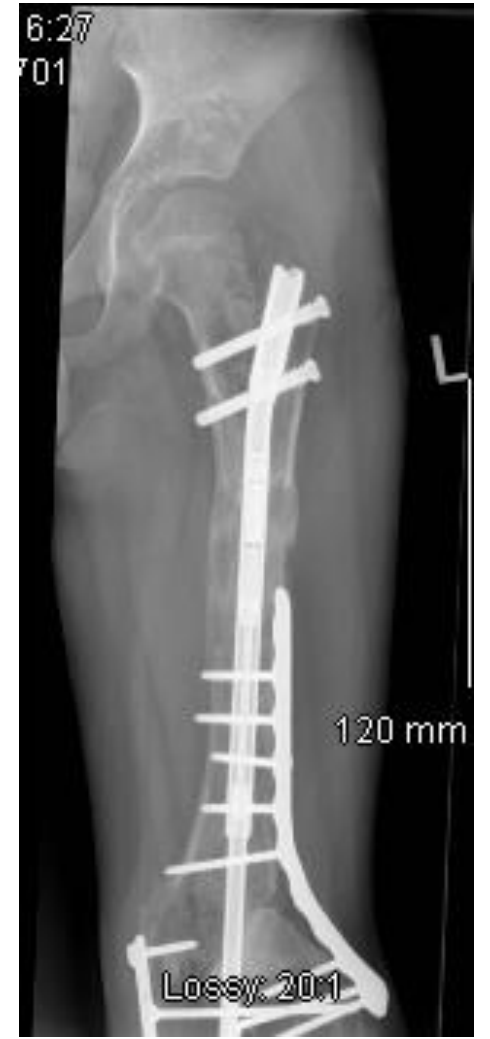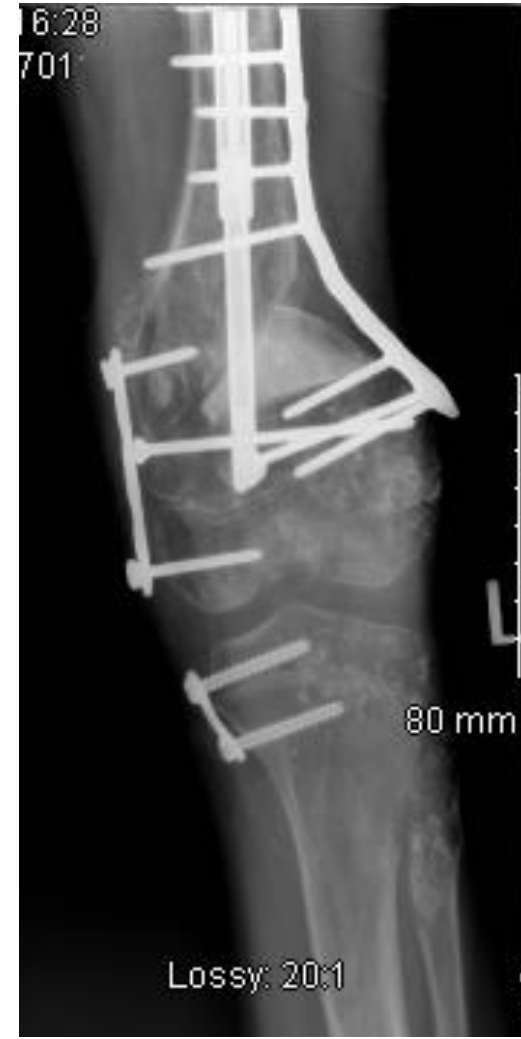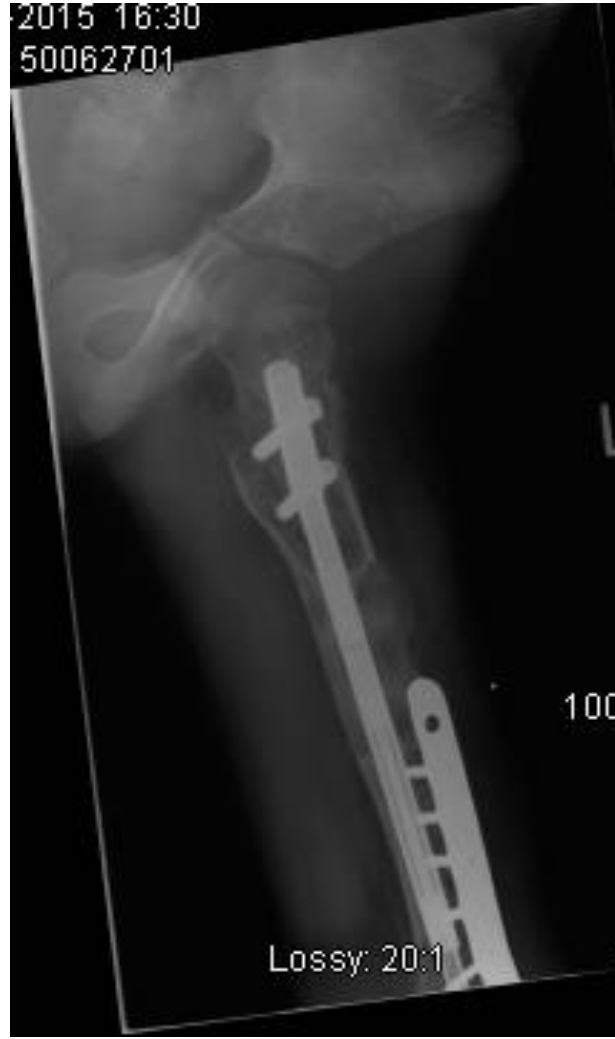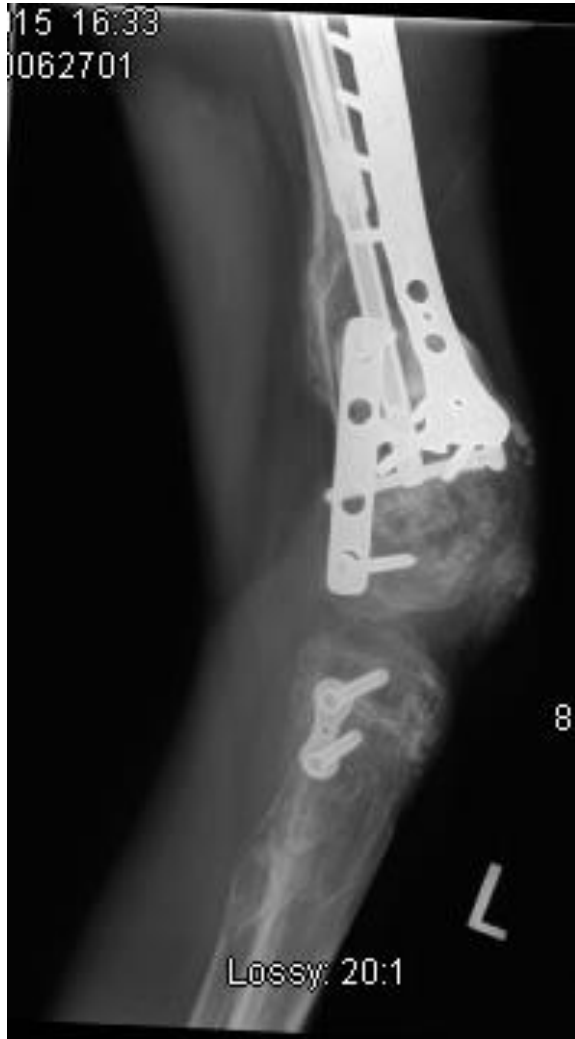June 22, 2015

5cm Lengthening



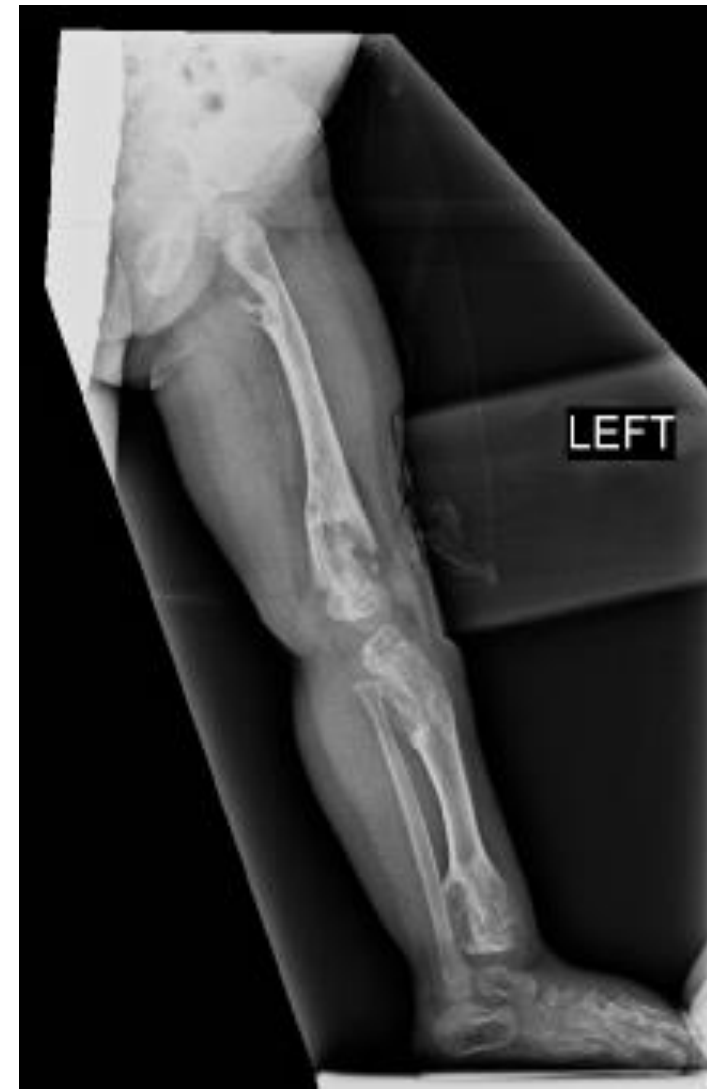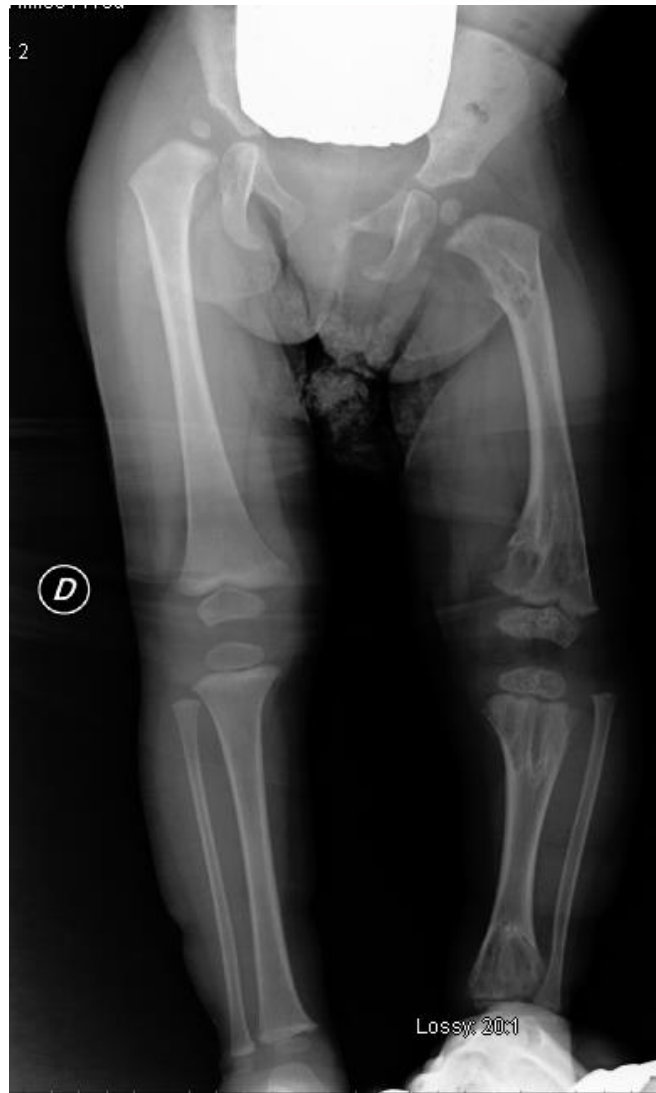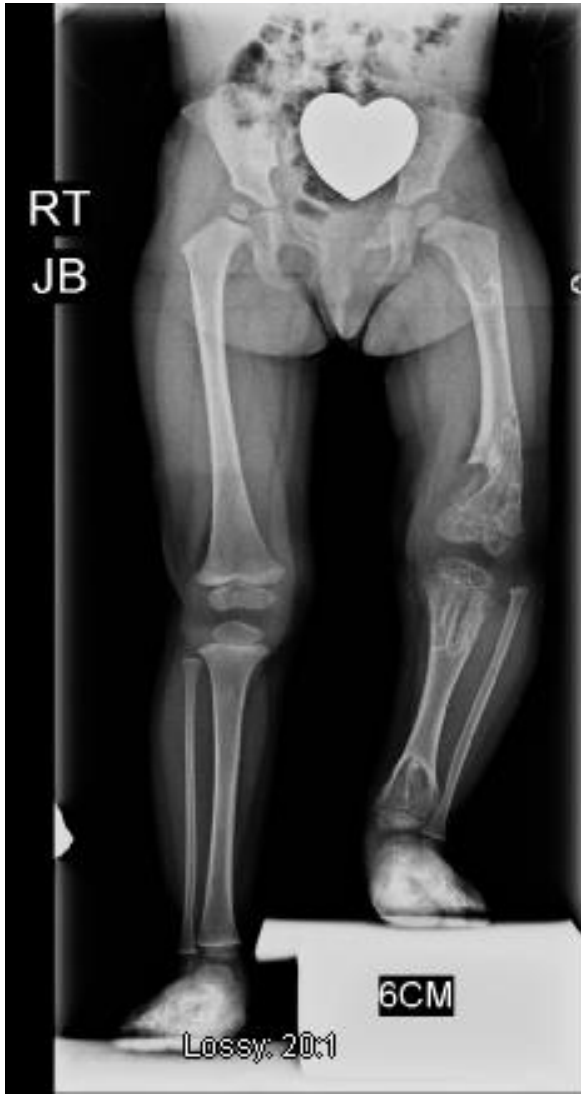August 3, 2015

Consolidation



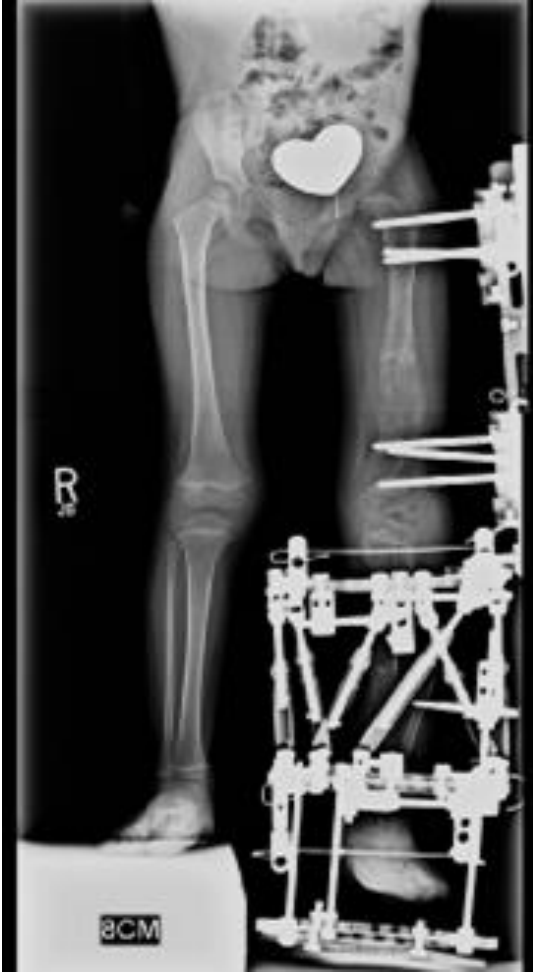September 22, 2015

Pre-op x-rays

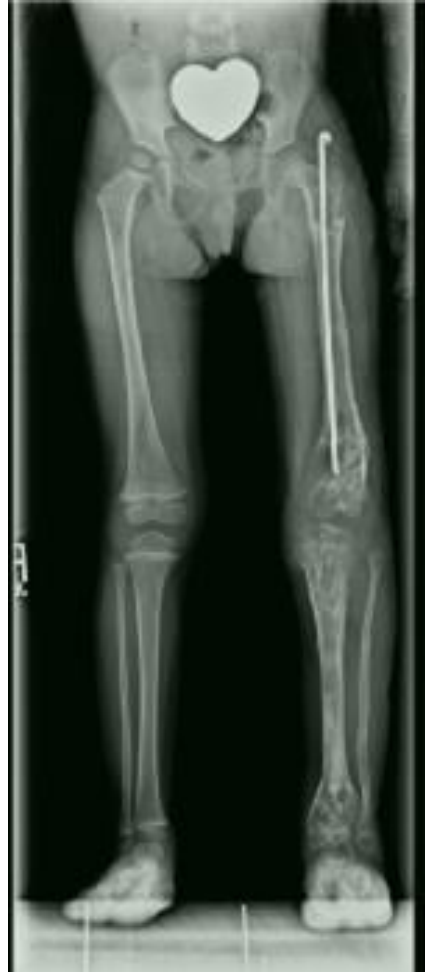

November 14, 2011

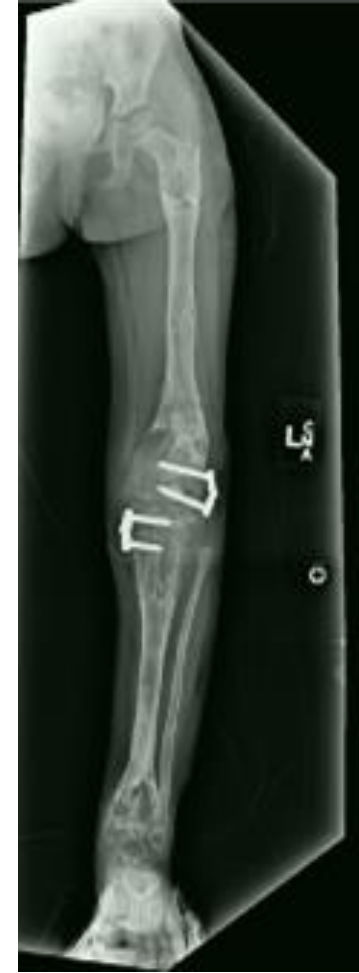Lengthening and Deformity Correction Femur and Tibia with Ex Fix Removal after 10cm Lengthening Hemi-epiphysiodesis to Rx Malalignment



June 20, 2012

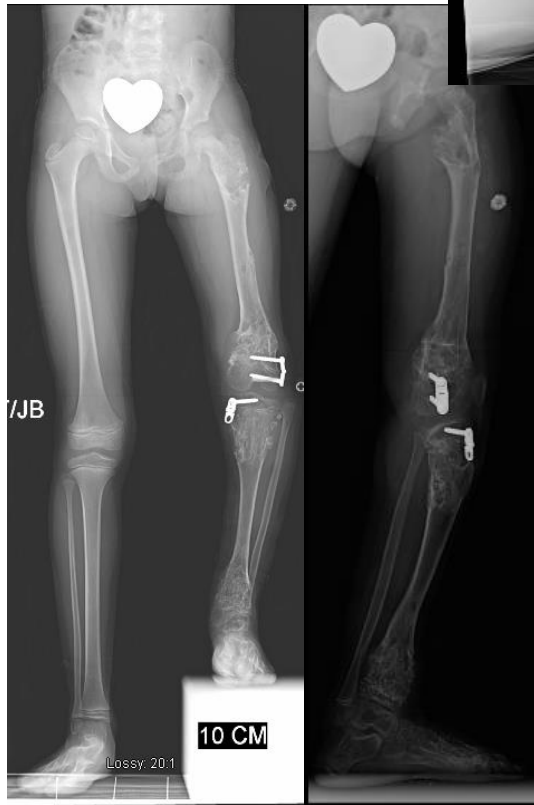


Sept 10, 2012

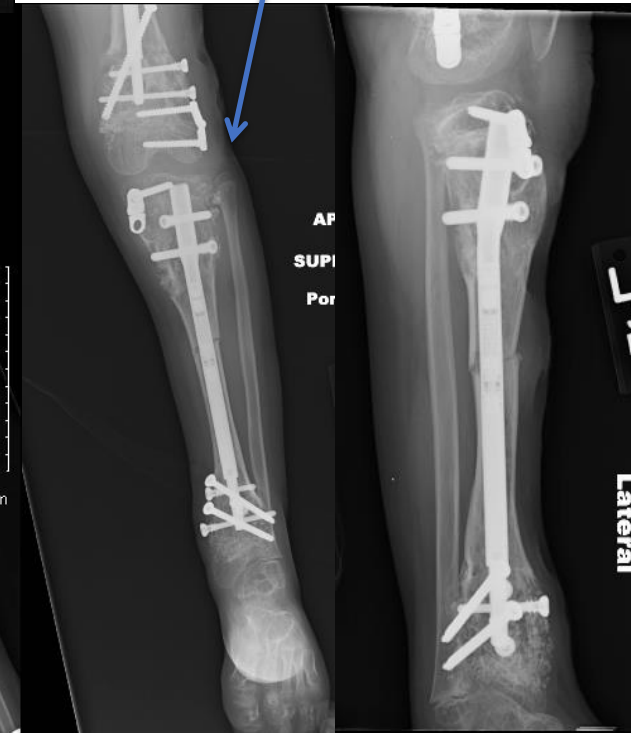
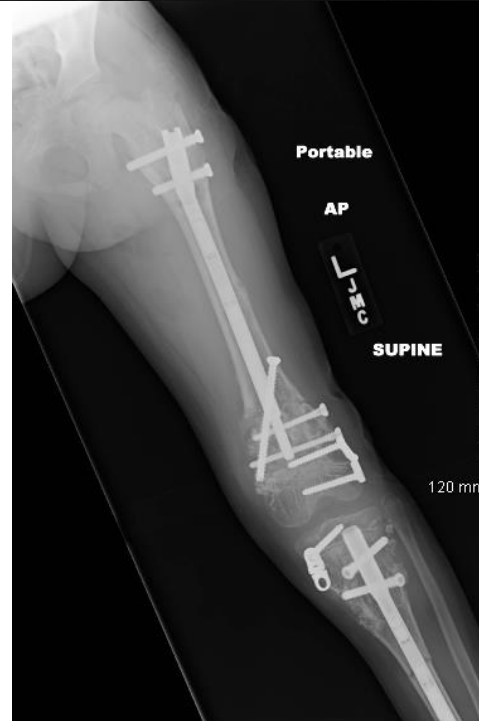
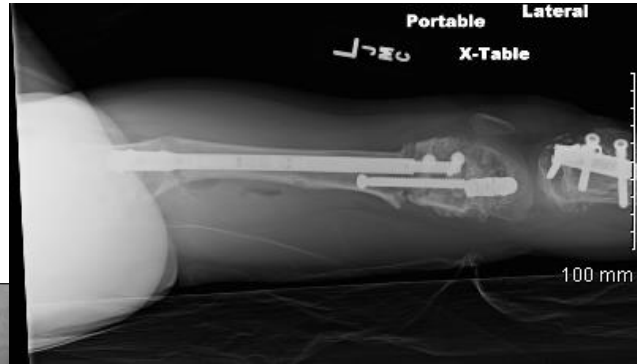


Dec 11, 2012

Osteotomy Distal Femur for correction varus fixed with Precice
Osteotomy of Tibia for Lengthening and Pulling down fibula.

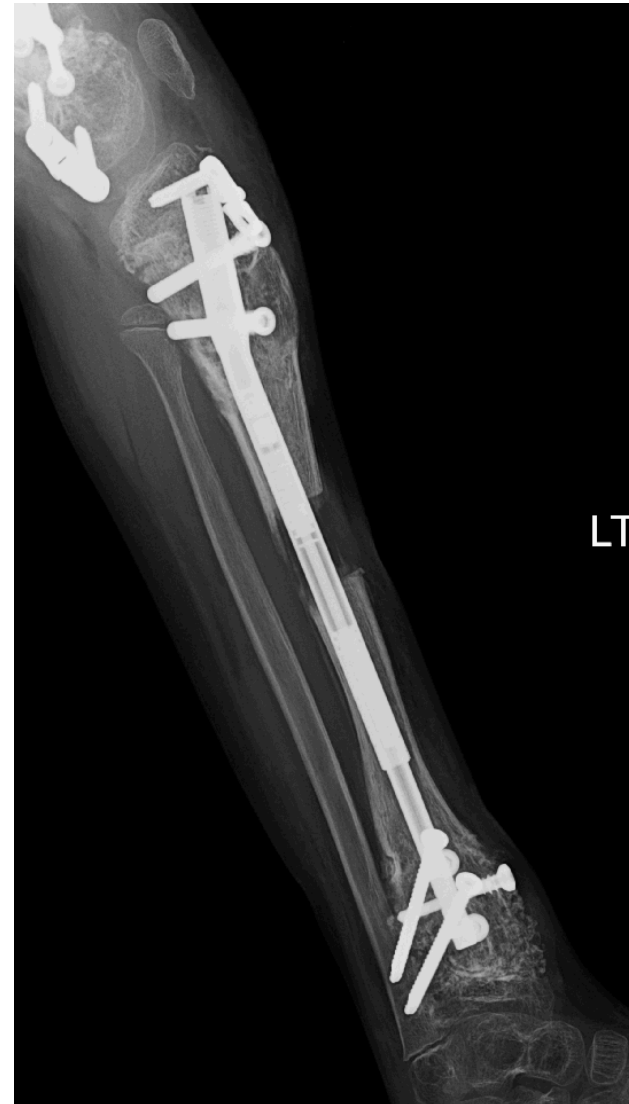
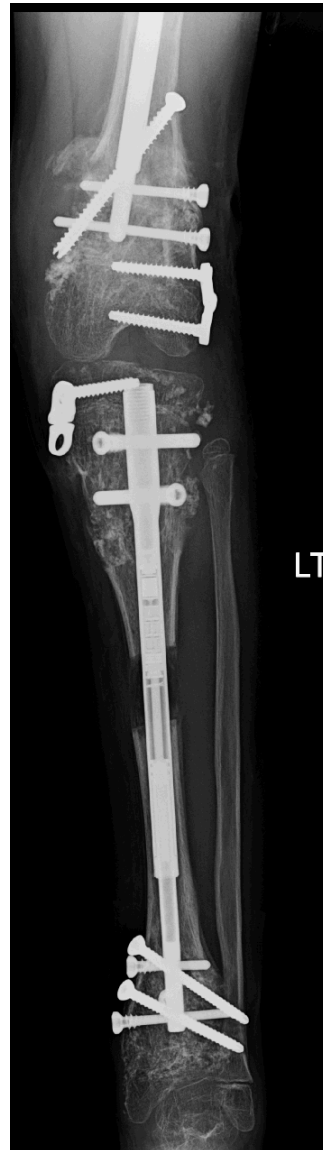
February 15, 2016

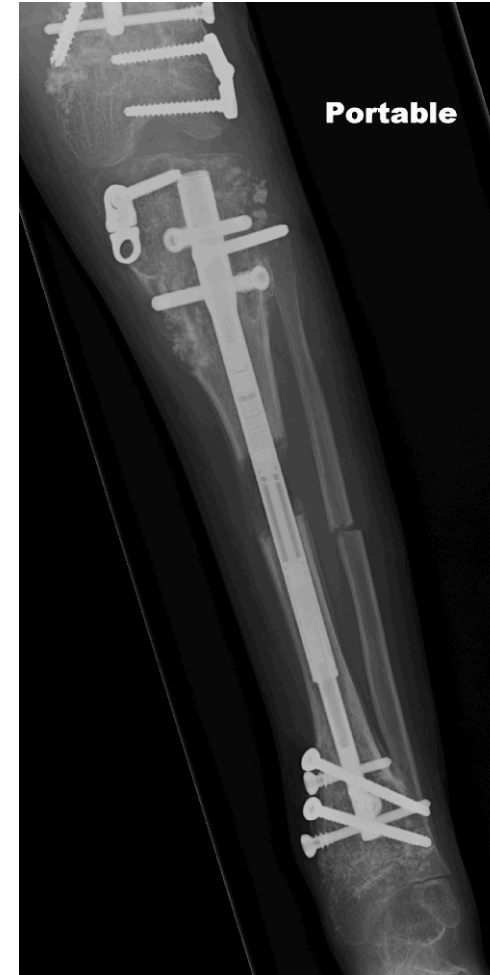
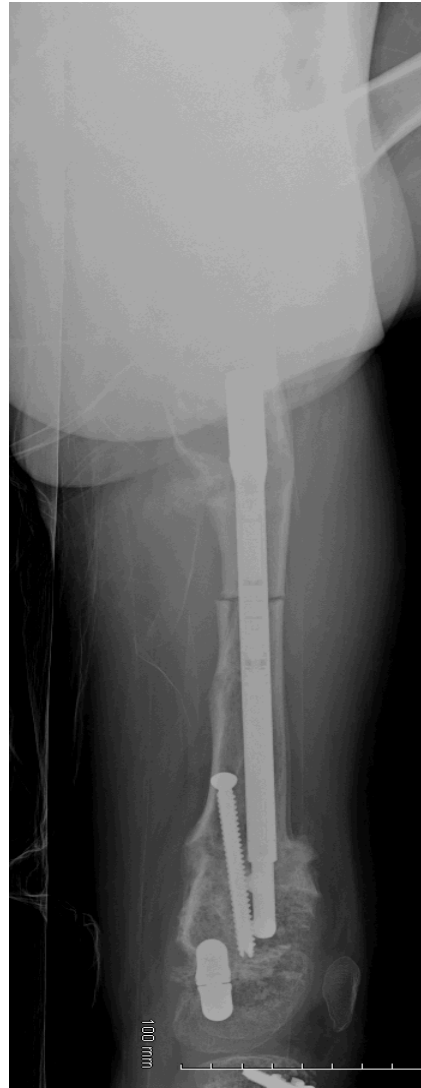
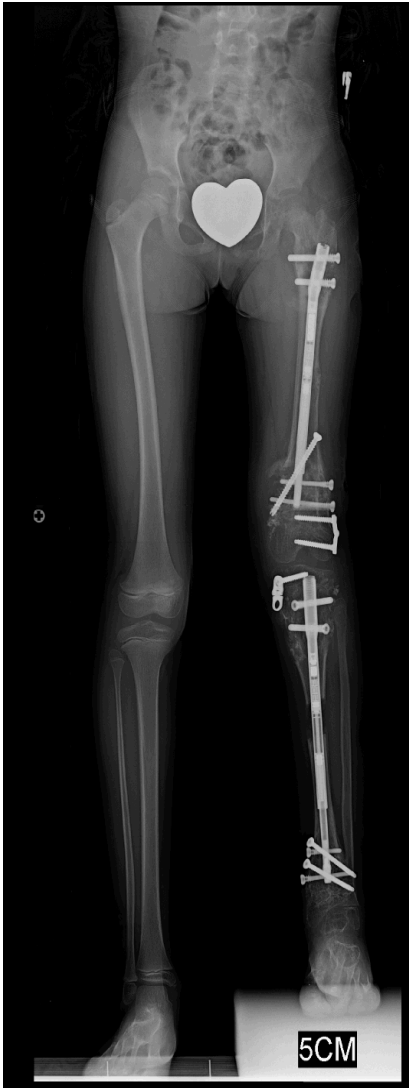February 16, 2016

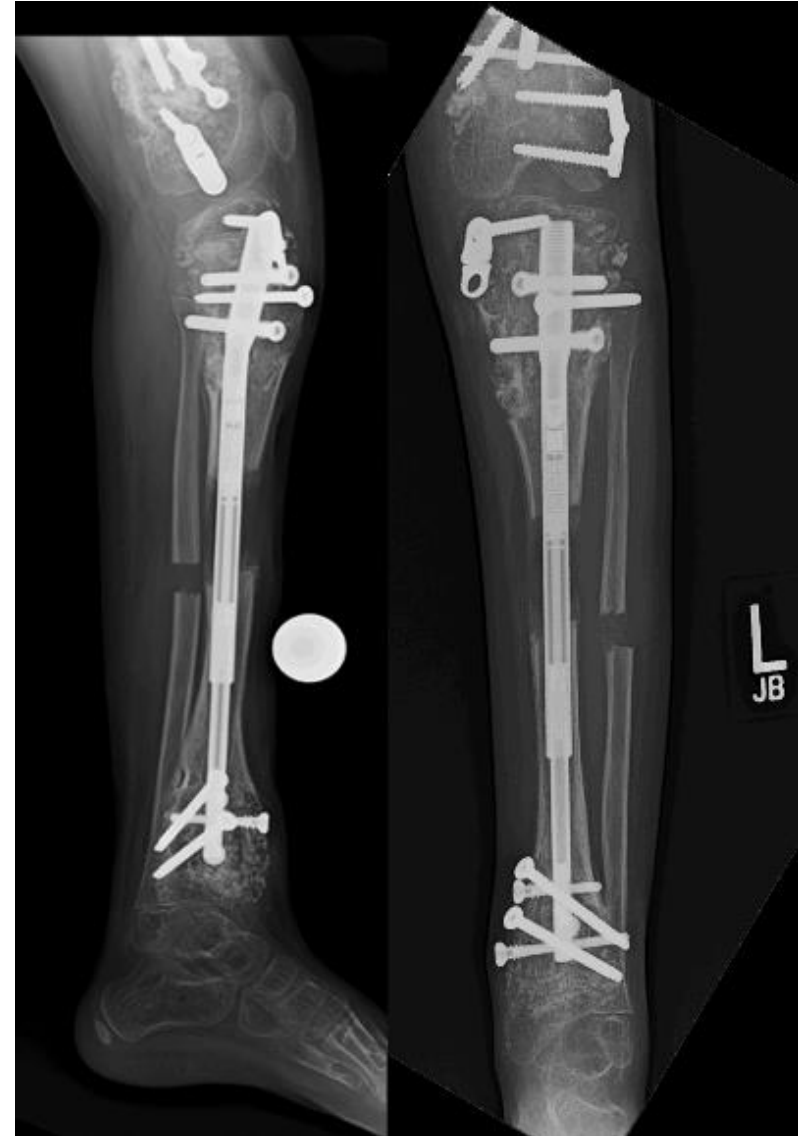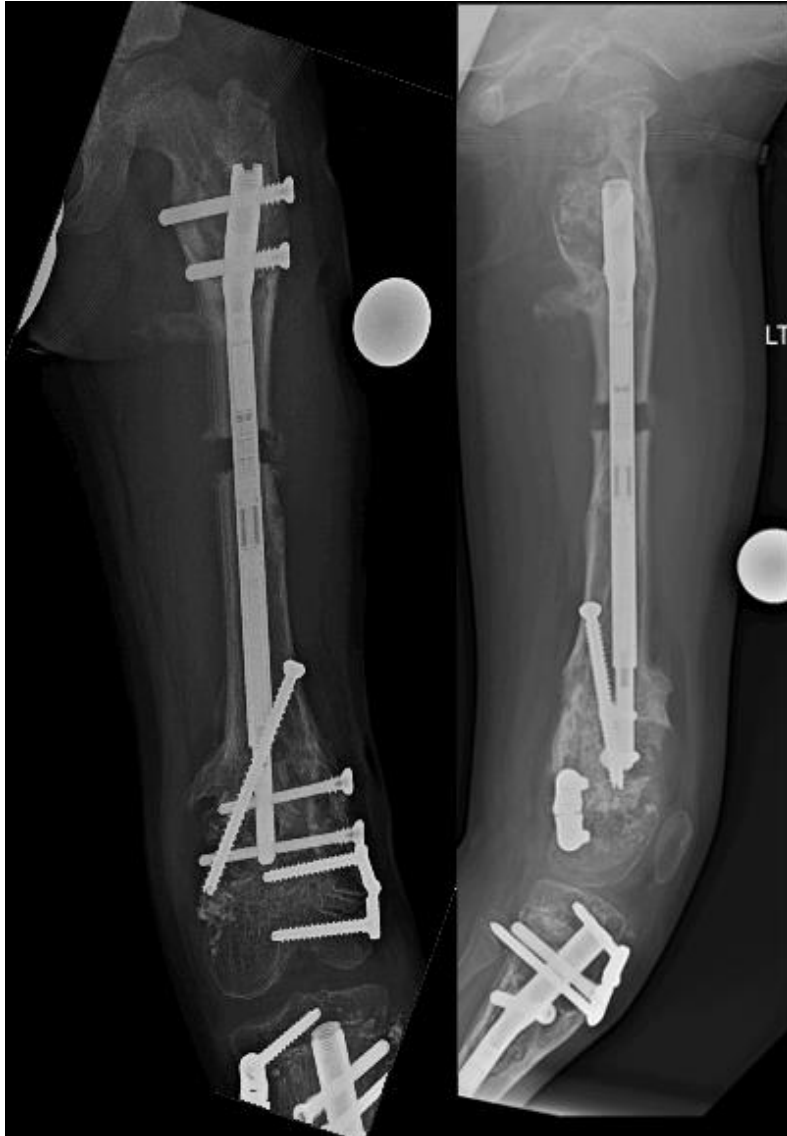Fibula Pulled Down by Tibial Lengthening and Distal Tib-Fib fixation No Fibular Osteotomy.



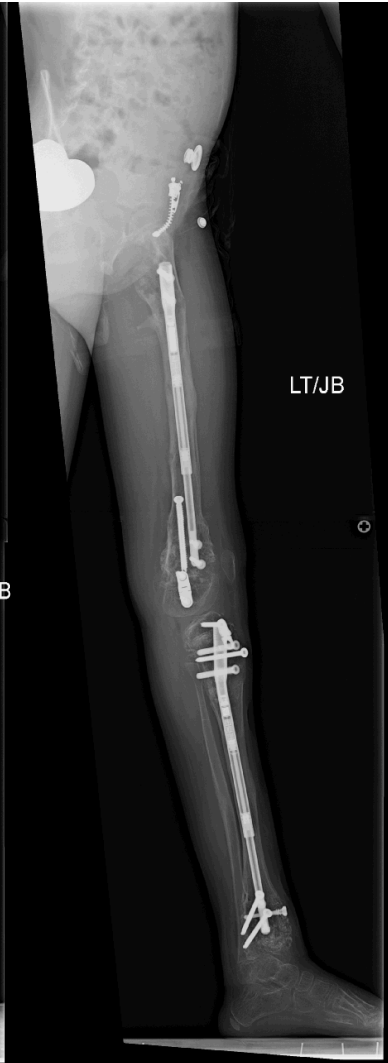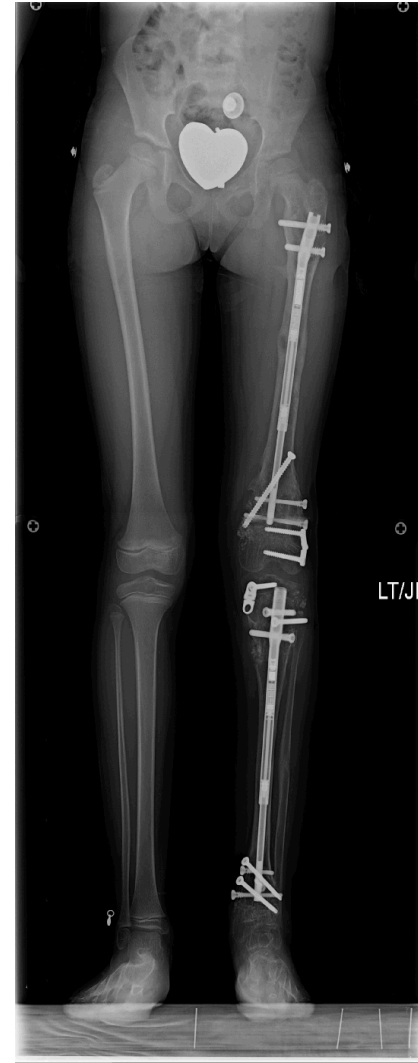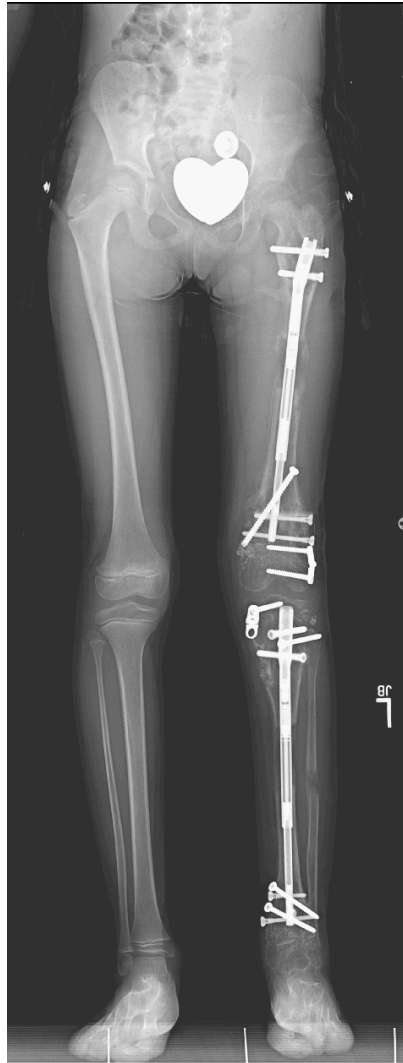Second Stage surgery:
Osteotomy Femur for Lengthening
Osteotomy fibula with proximal tib-fib fixation.



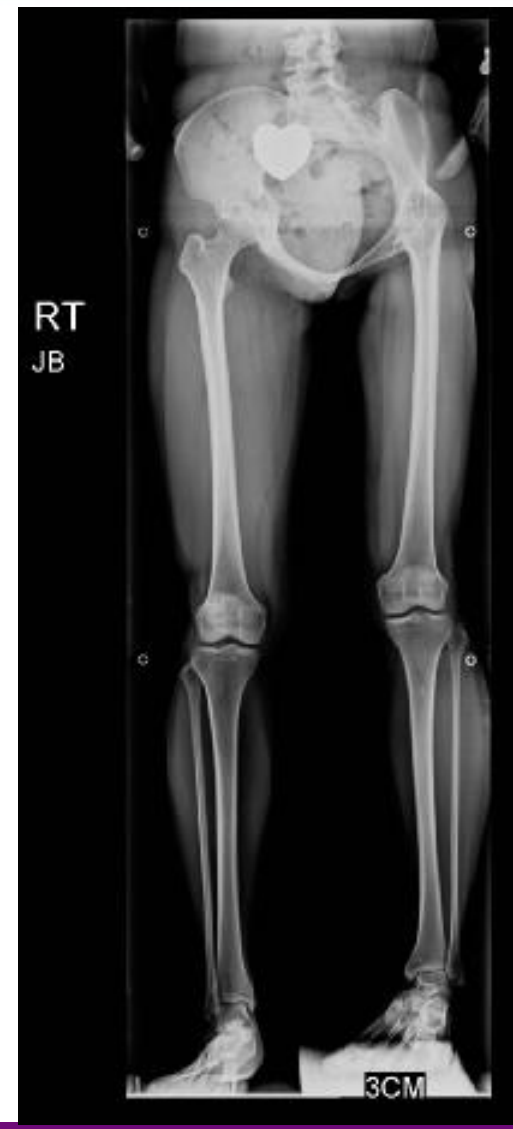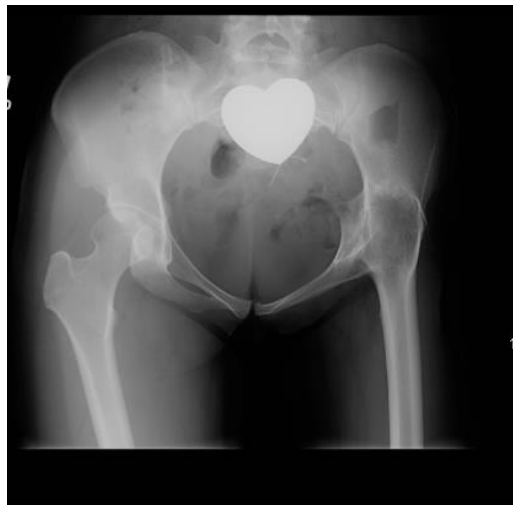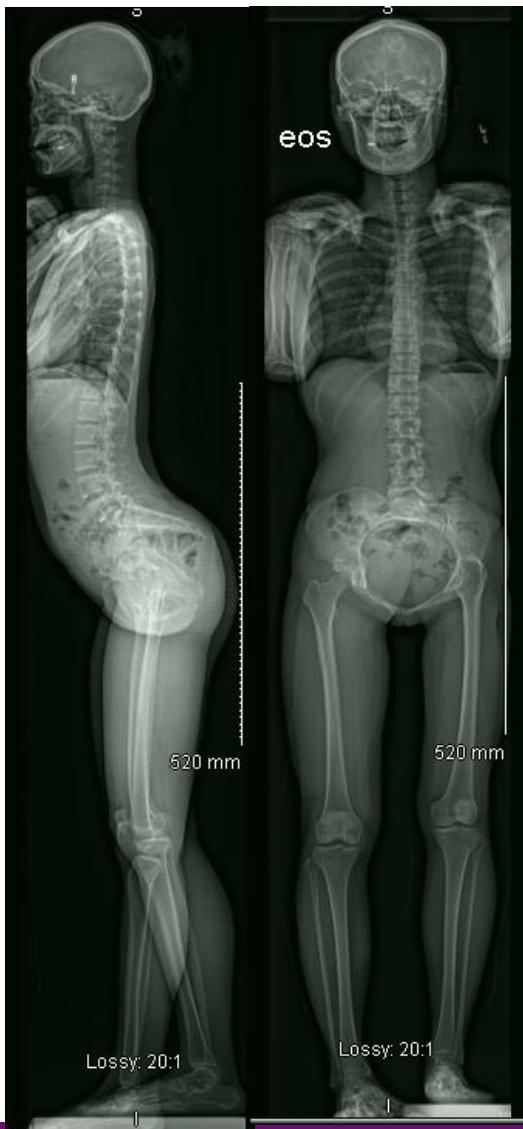Lengthening Femur Continue Lengthening Tibia and Fibula



5cm Lengthening Femur
5cm Lengthening Tibia
Total Gain 10 cm
Full Bone Consolidation Achieved

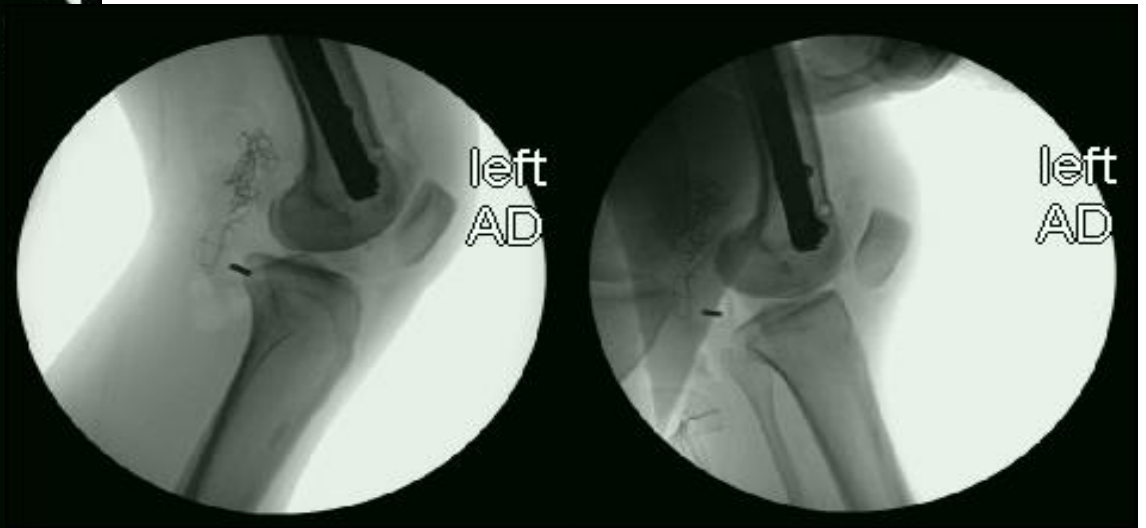
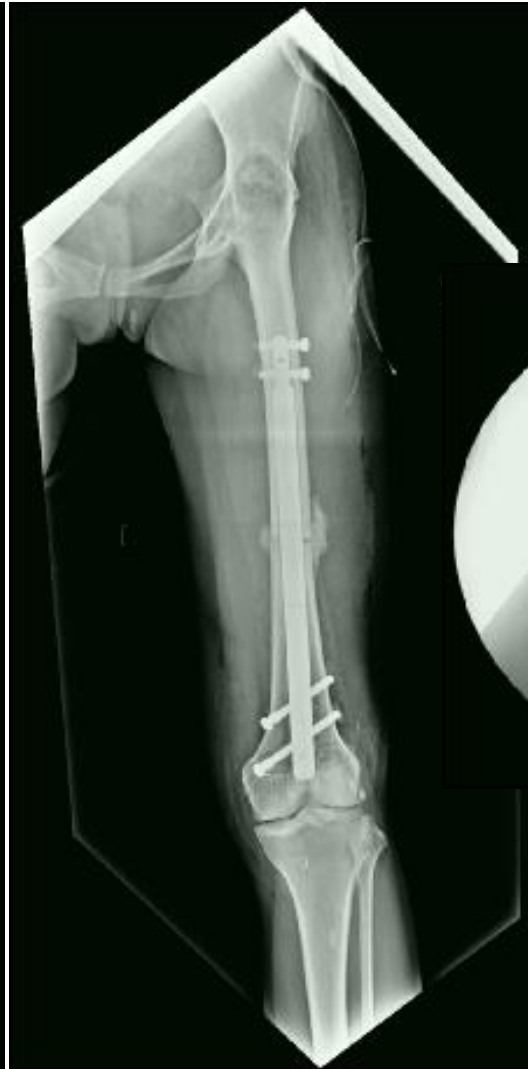
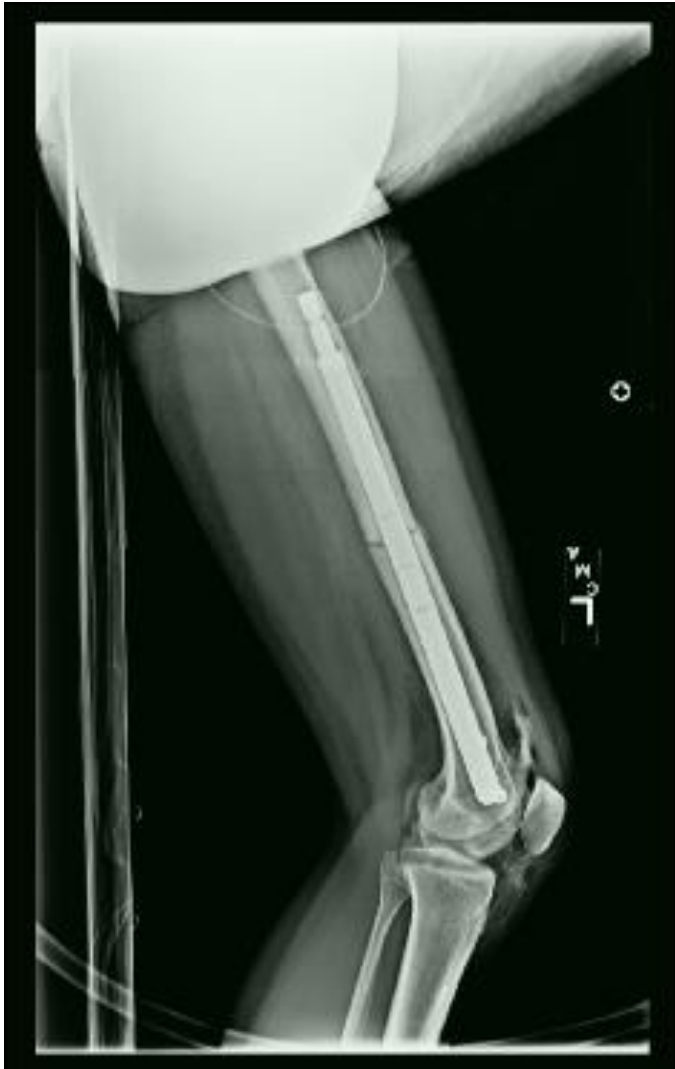
38 y.o. Woman: Vietnamese ?? History of TB hip; Hip Fusion; LLD



April 26, 2013

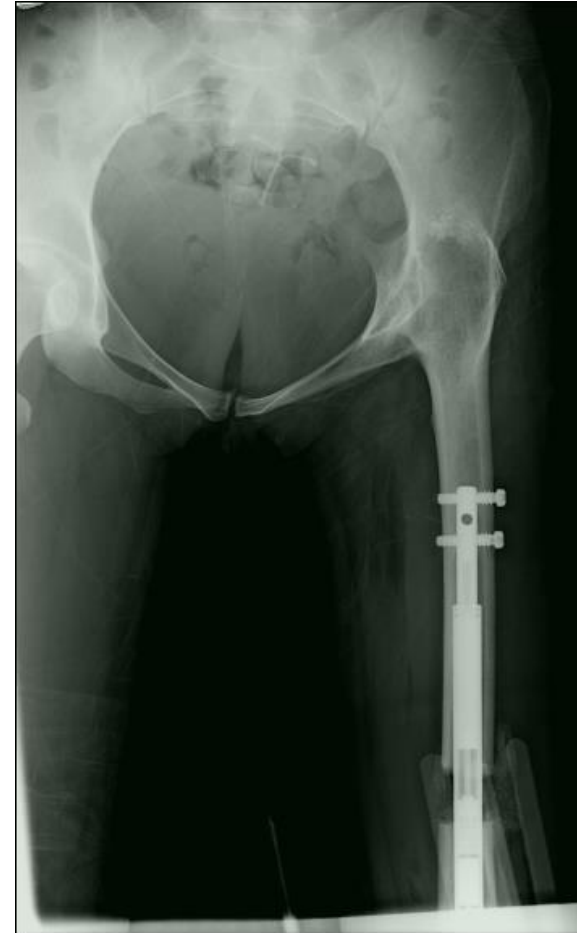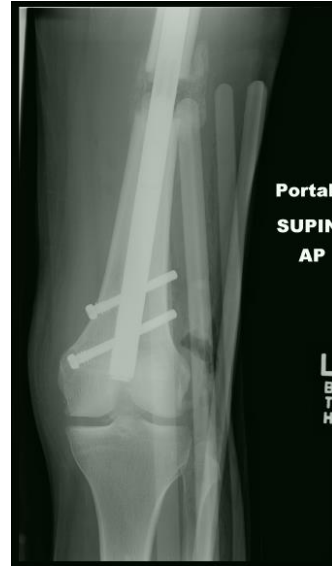
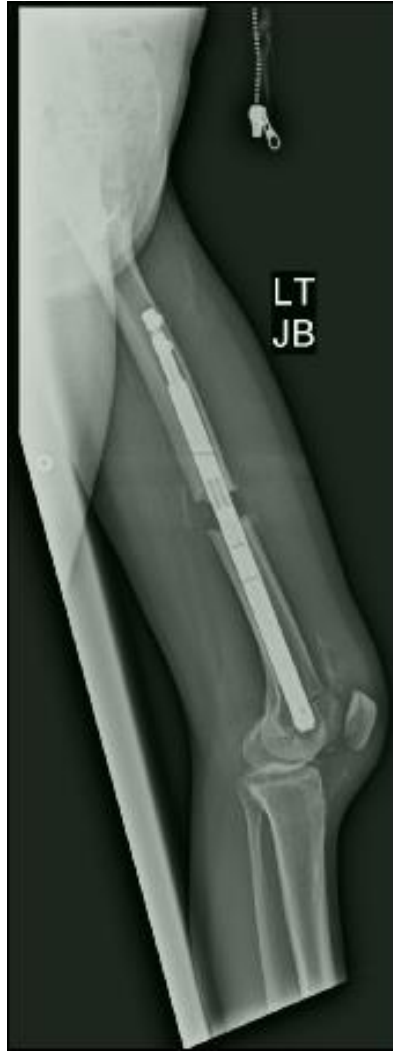Rotation Osteotomy with Fixator Pins: Retrograde Precice



July 8, 2013

July 9, 2013

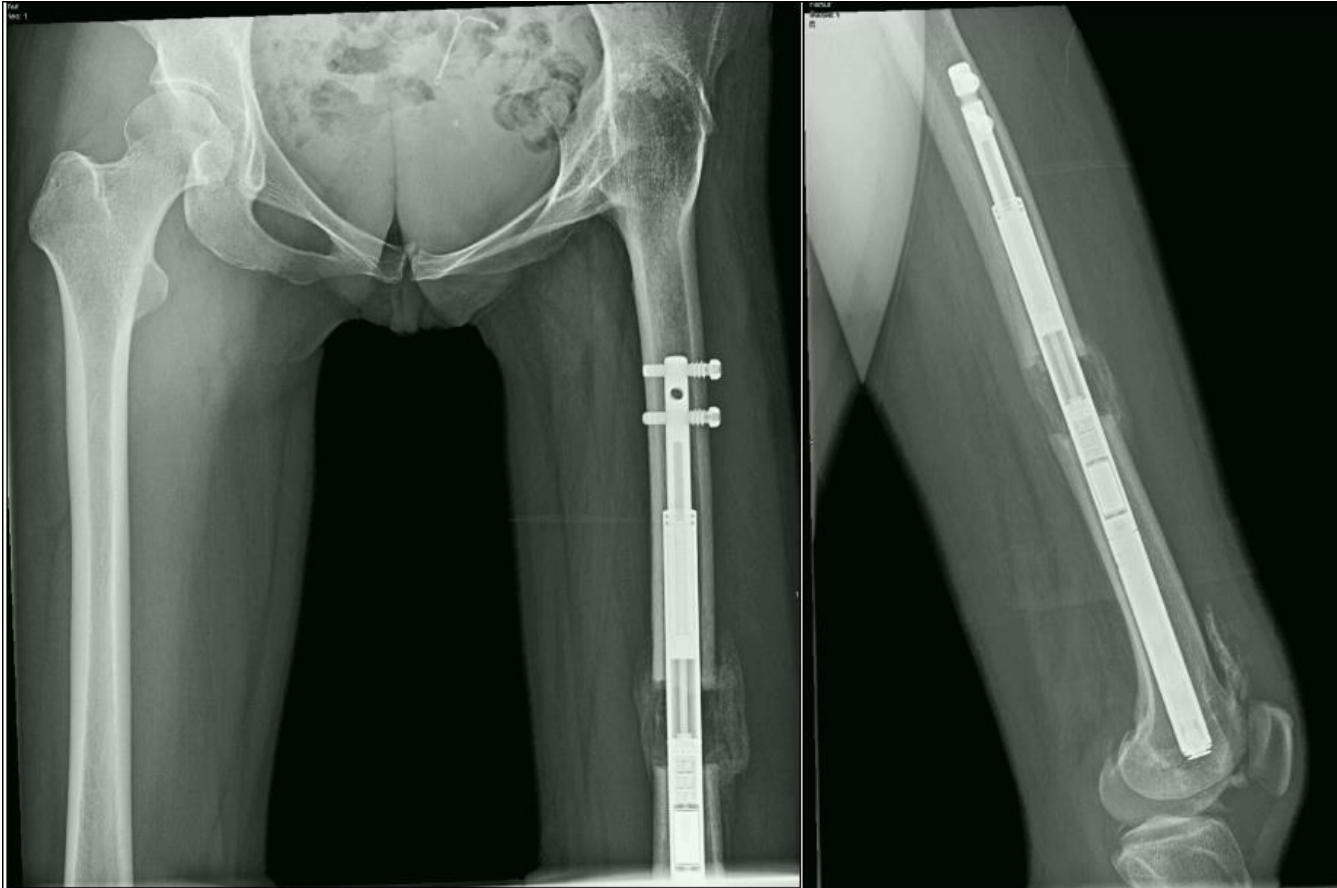Peroneal N and Fascia Lata Symptoms: decompression and release ITB and biceps



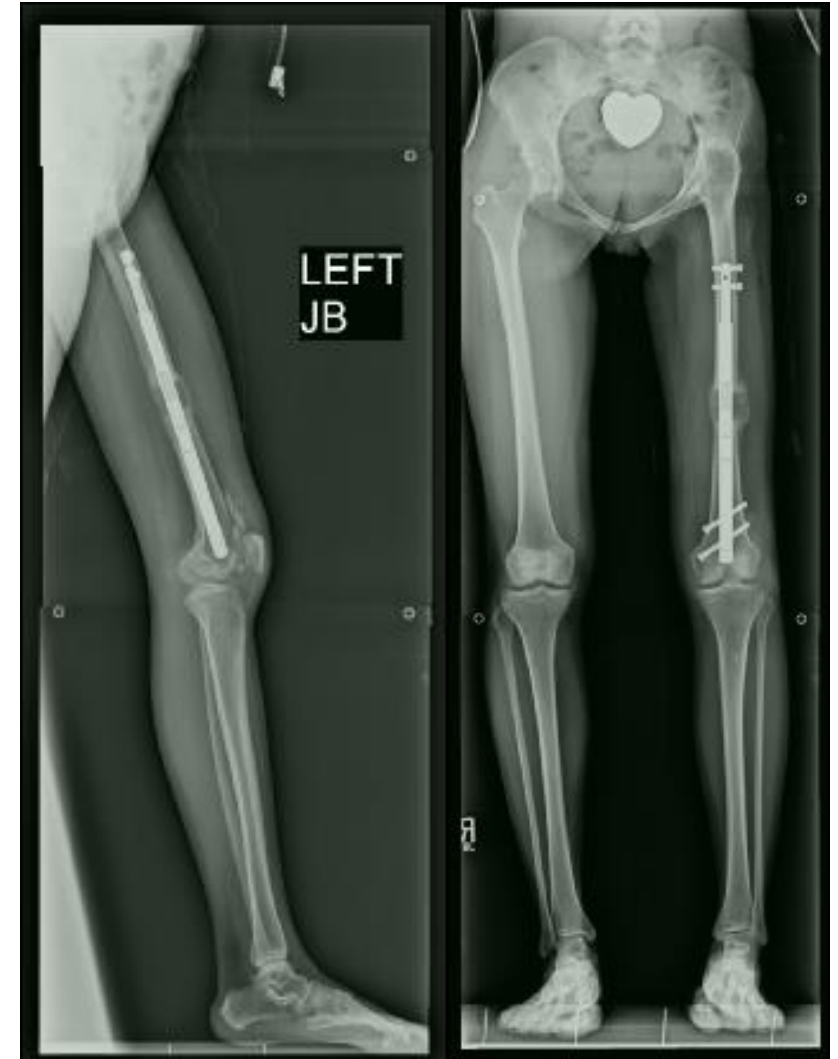Aug 2, 2013

Aug 5, 2013

Left 1cm short intentionally

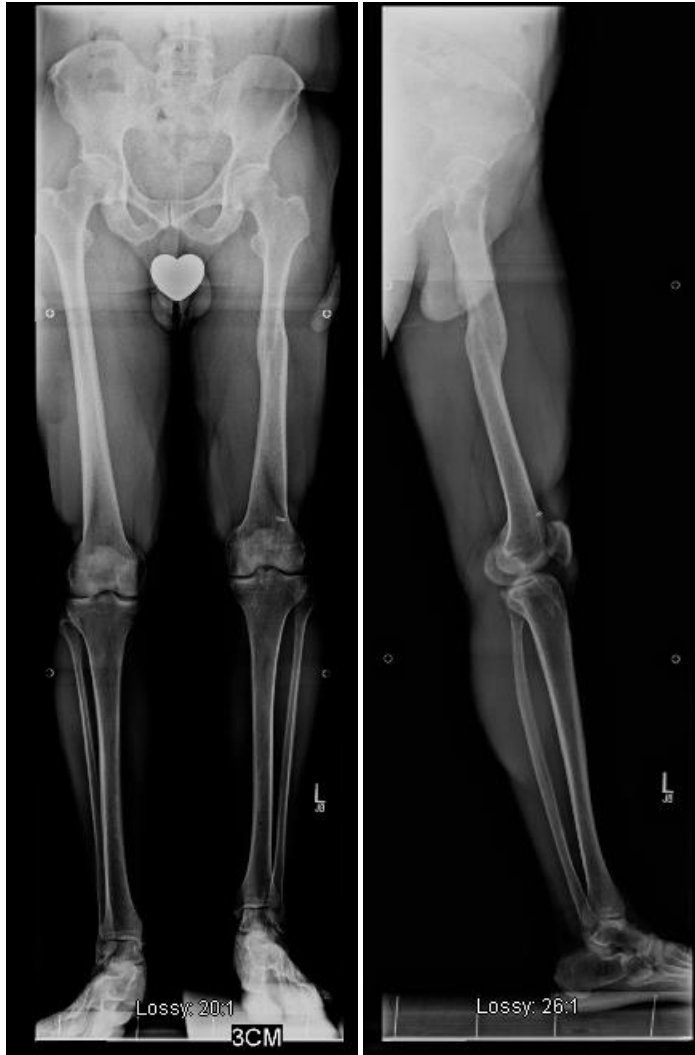

Sept 10, 2013

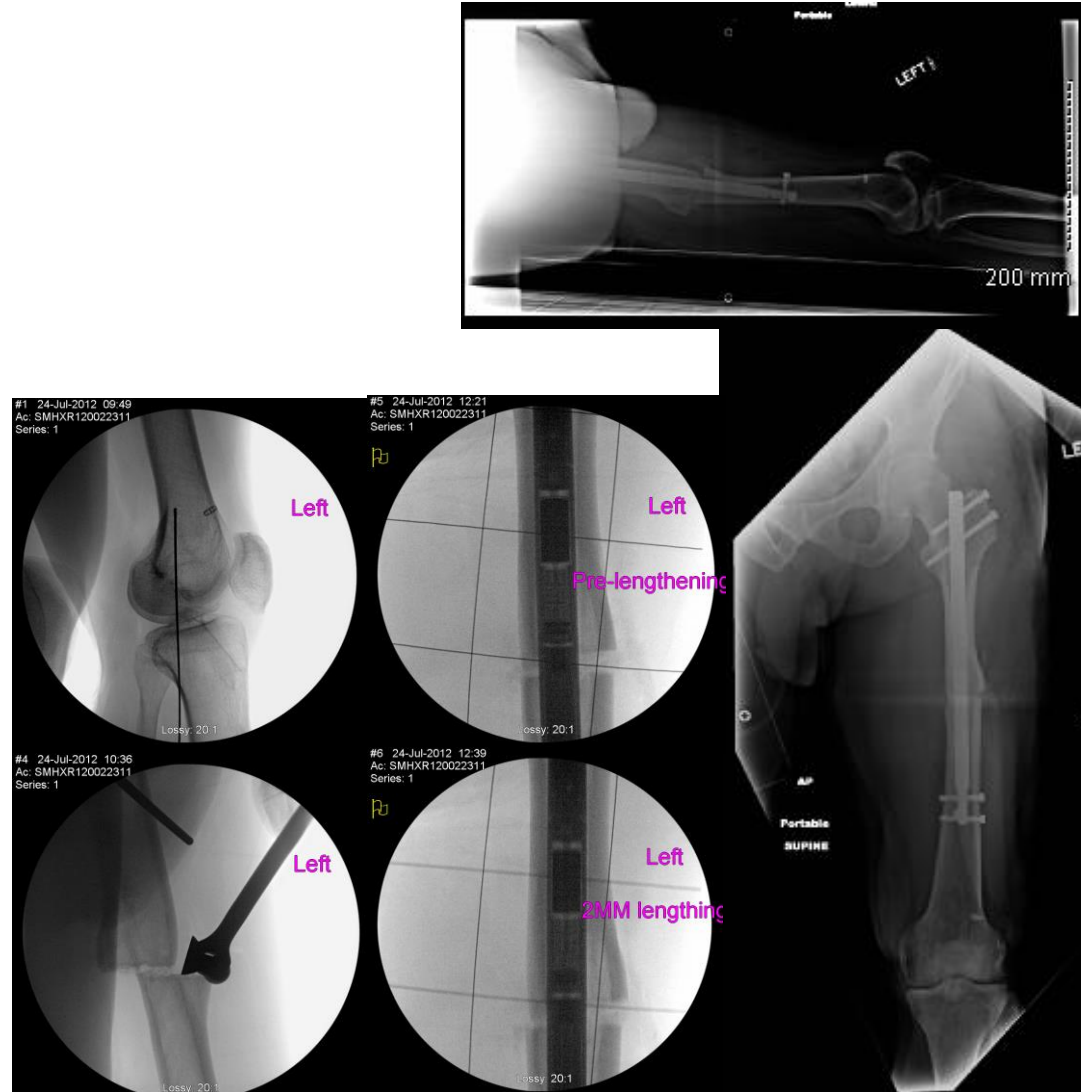


Oct 4, 2013

Post-traumatic LLD; bayonet malunion

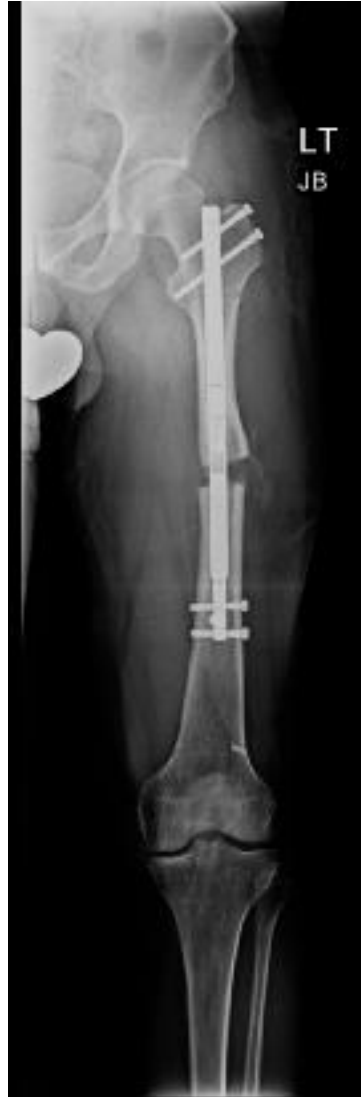

April 3, 2012



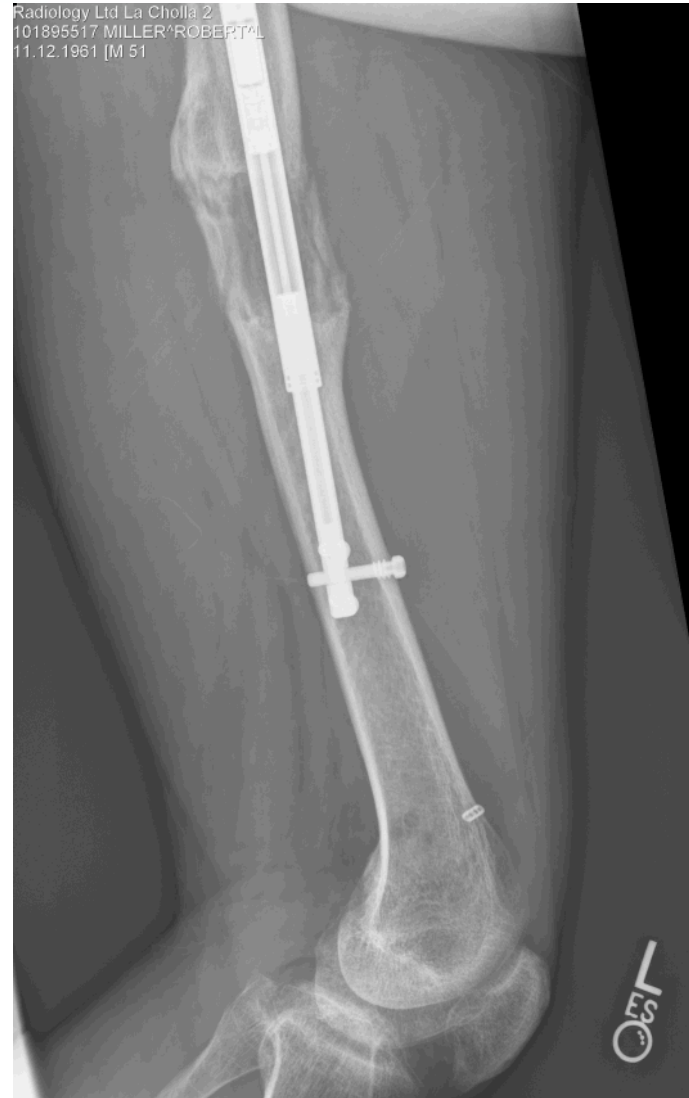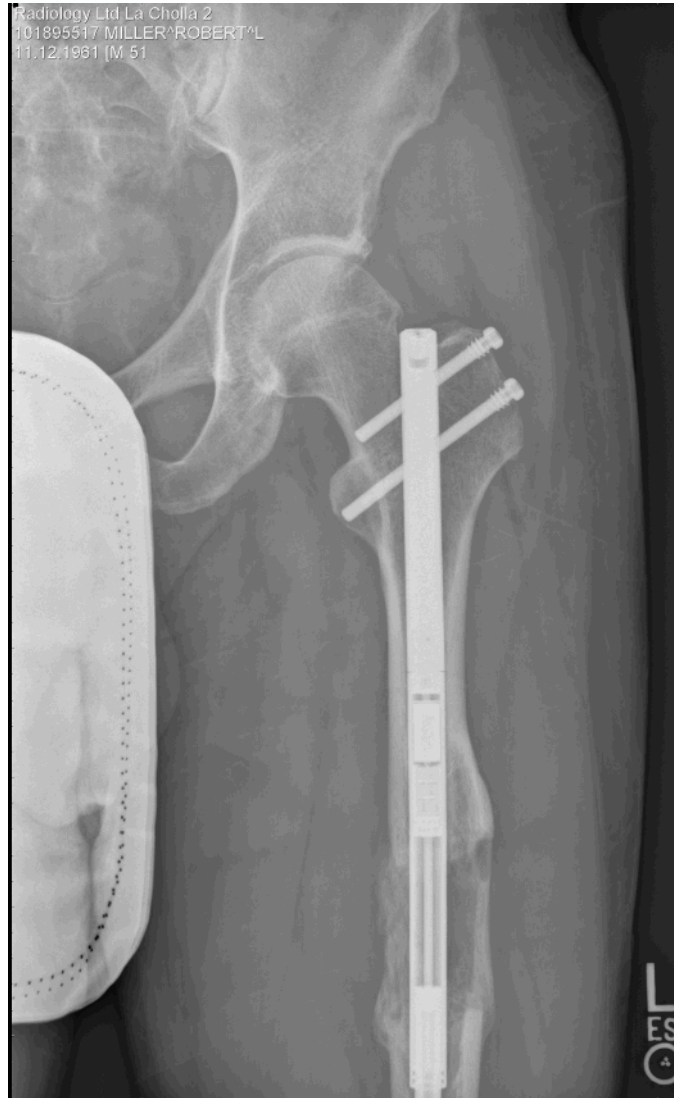July 24, 2012.

Acute correction of malunion



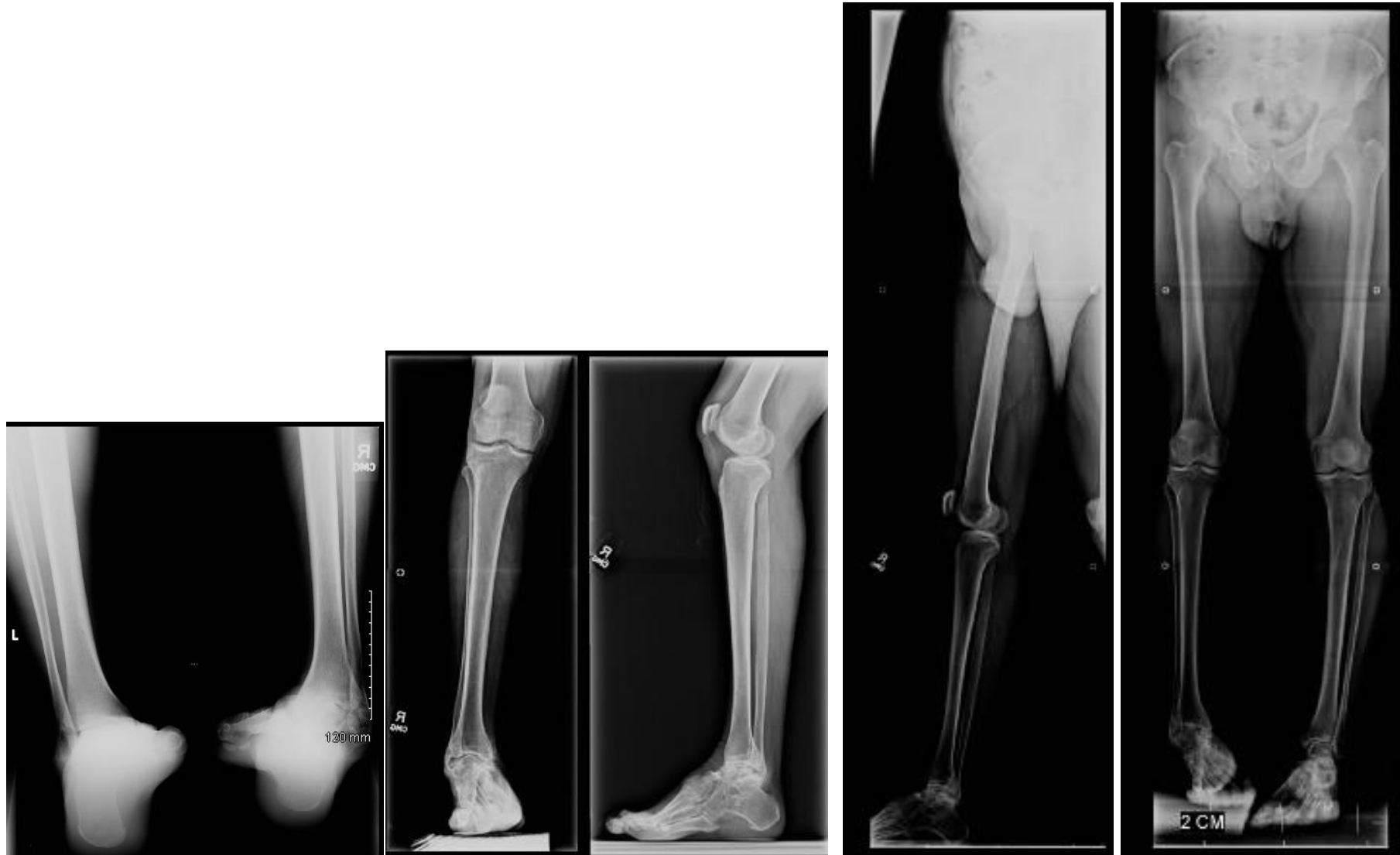Aug 14, 2012

Final Xrays



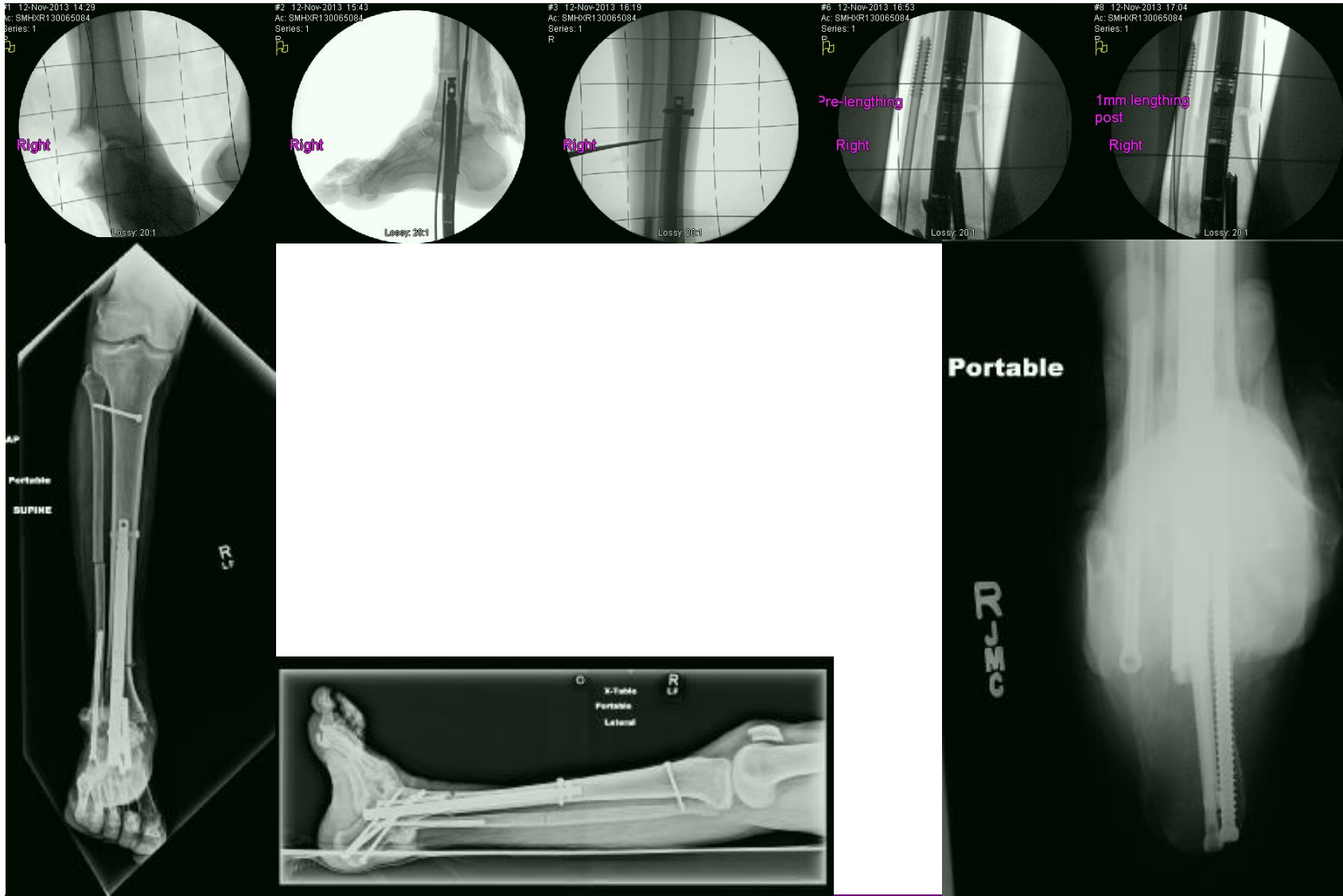
Dec 27, 2012

61 y.o. man: Failed ankle fusion: Malnonunion; LLD



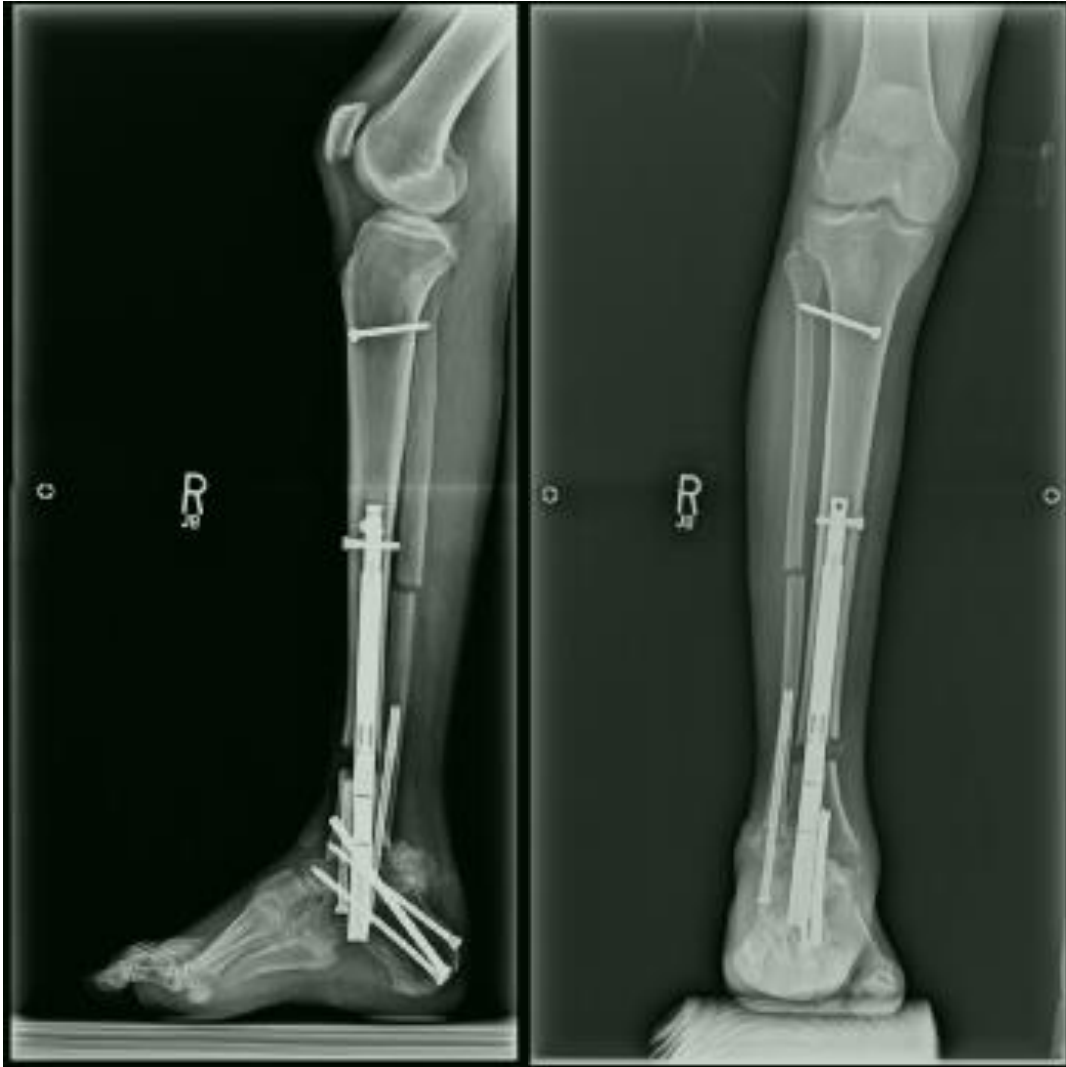May 1, 2013

Post-Op x-rays

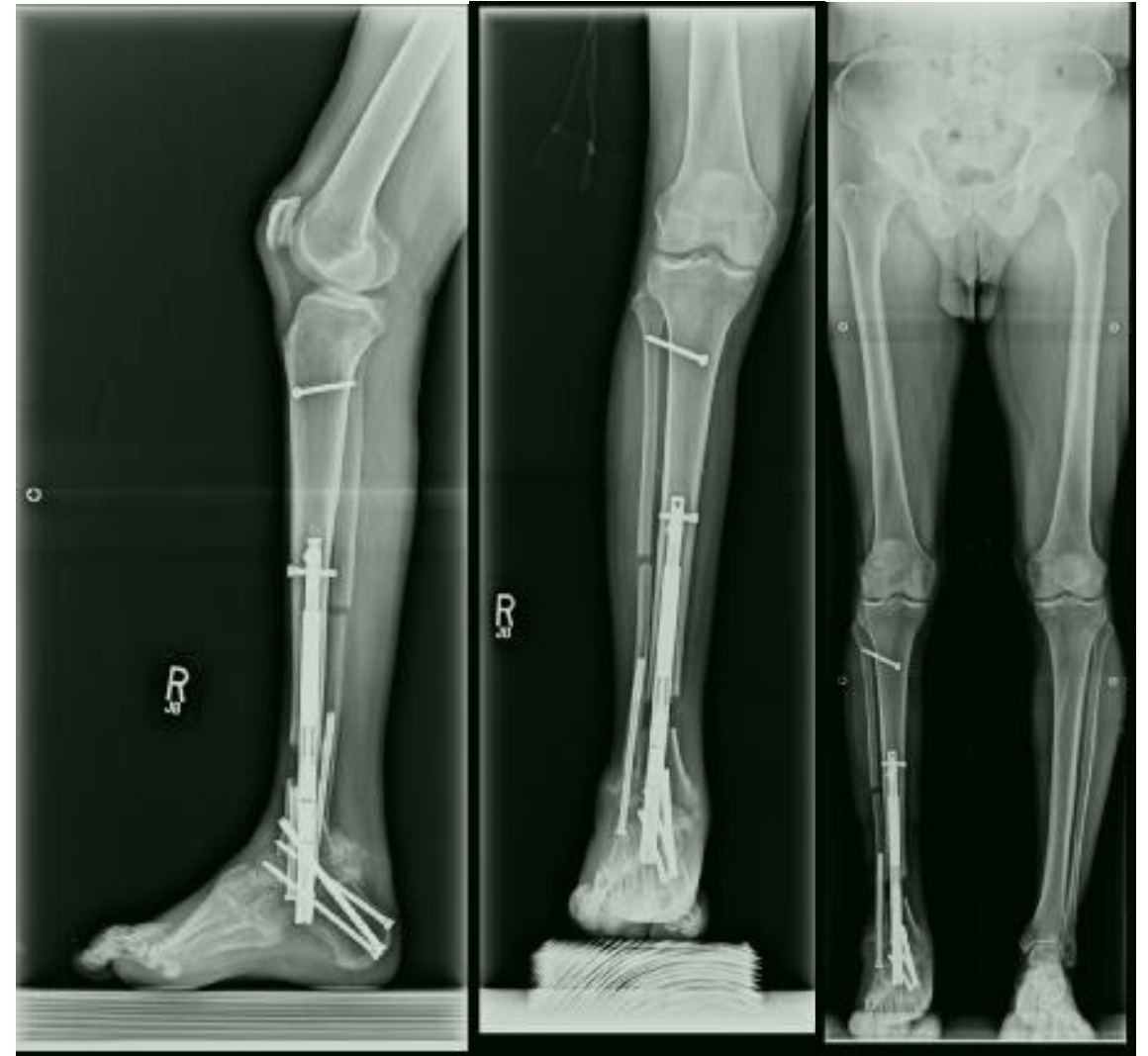

Nov 12, 2013

Follow up x-rays

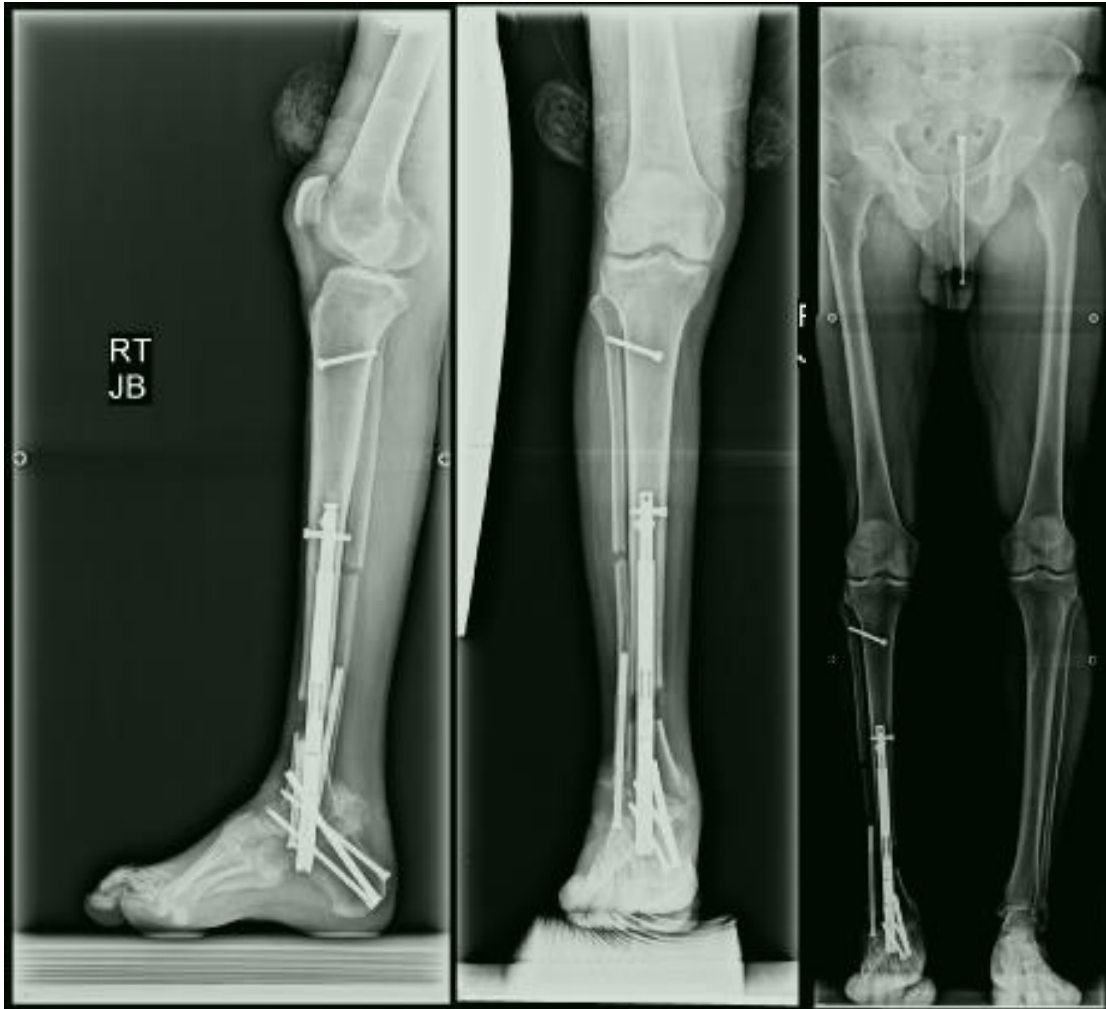

Dec 9, 2013

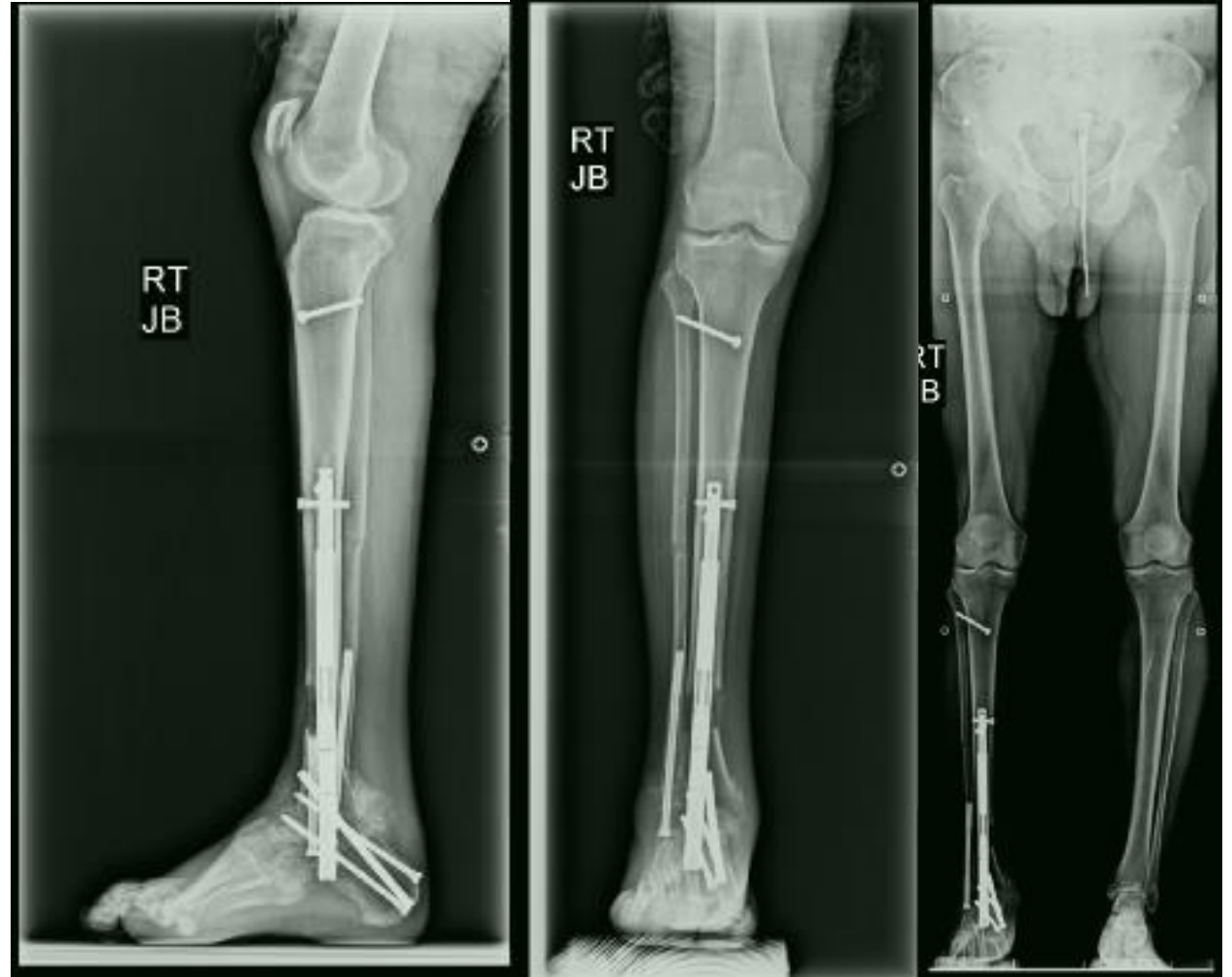

Dec 23, 2013

Follow up x-rays

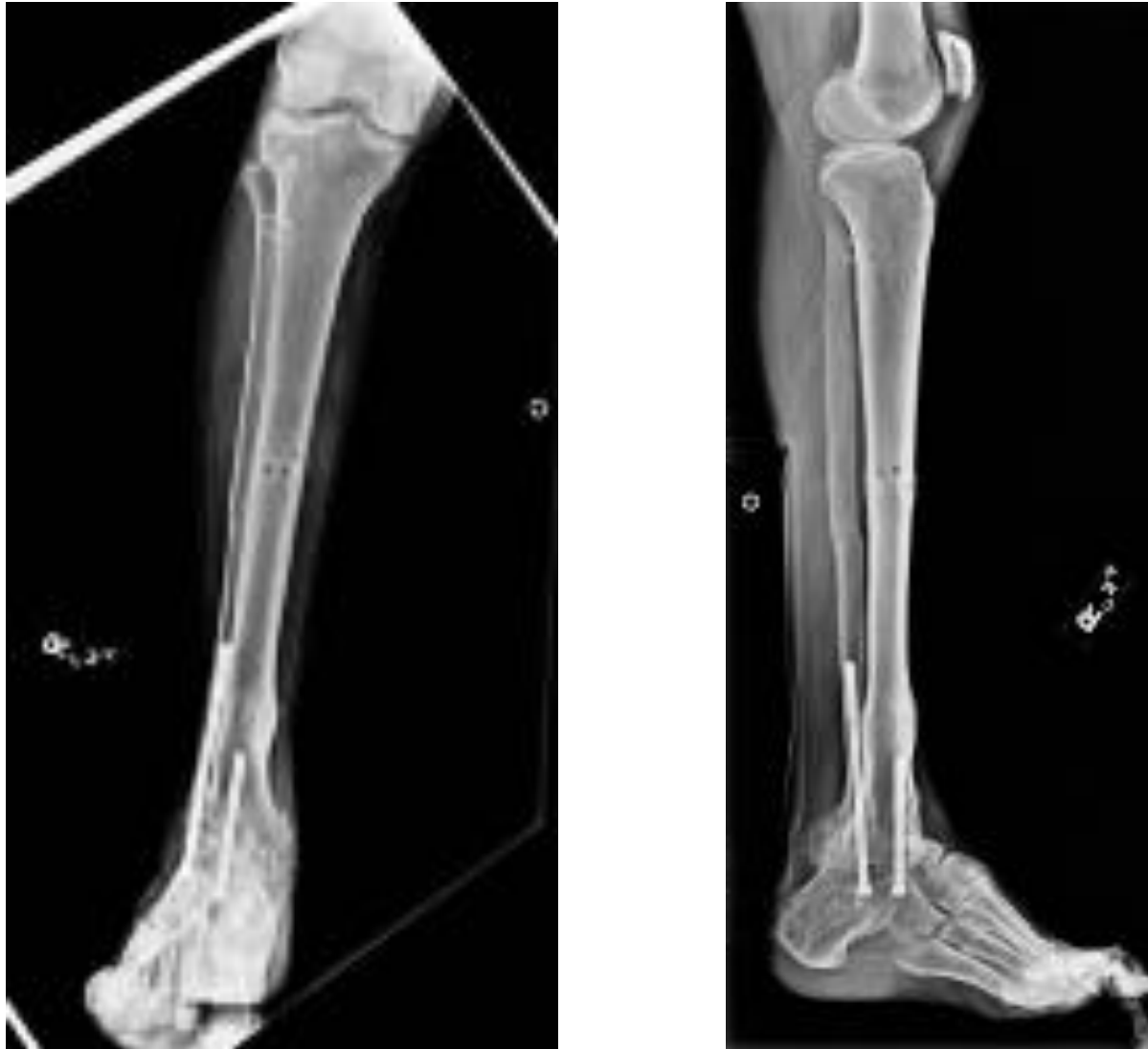

Dec 30, 2013



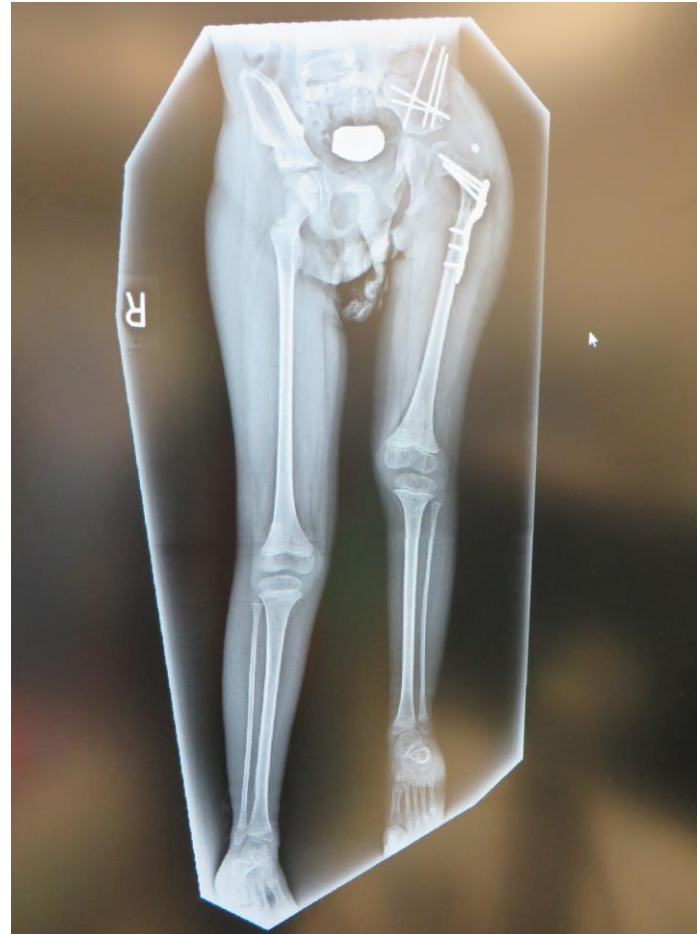Jan 27, 2013

Removal

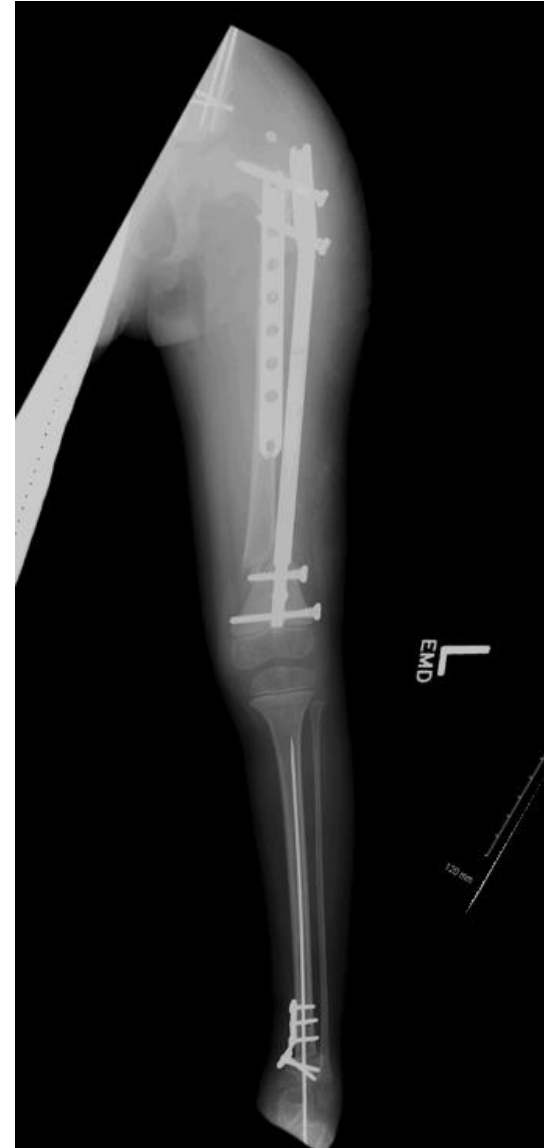
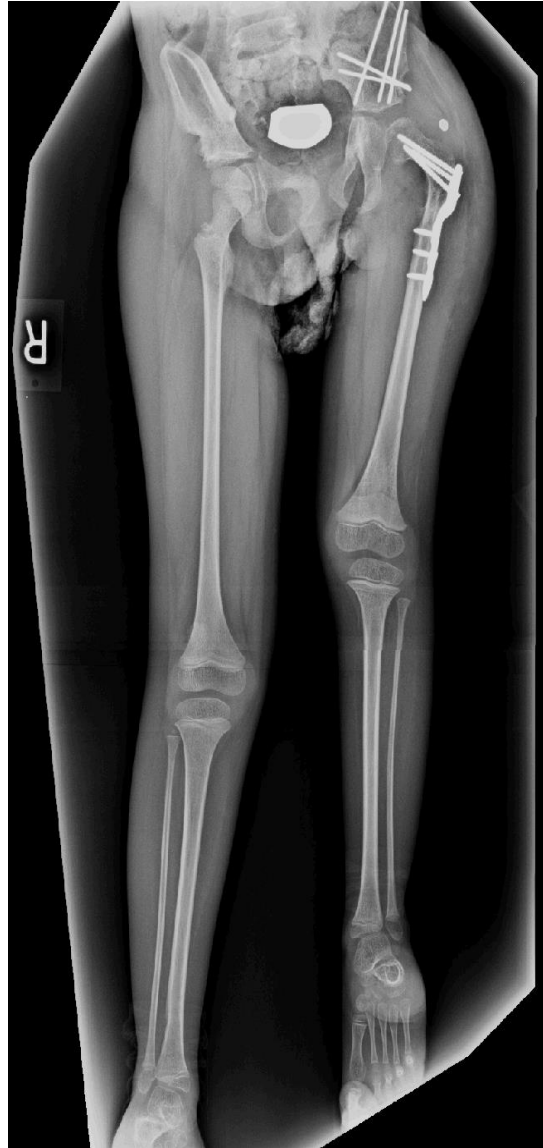

October 2014

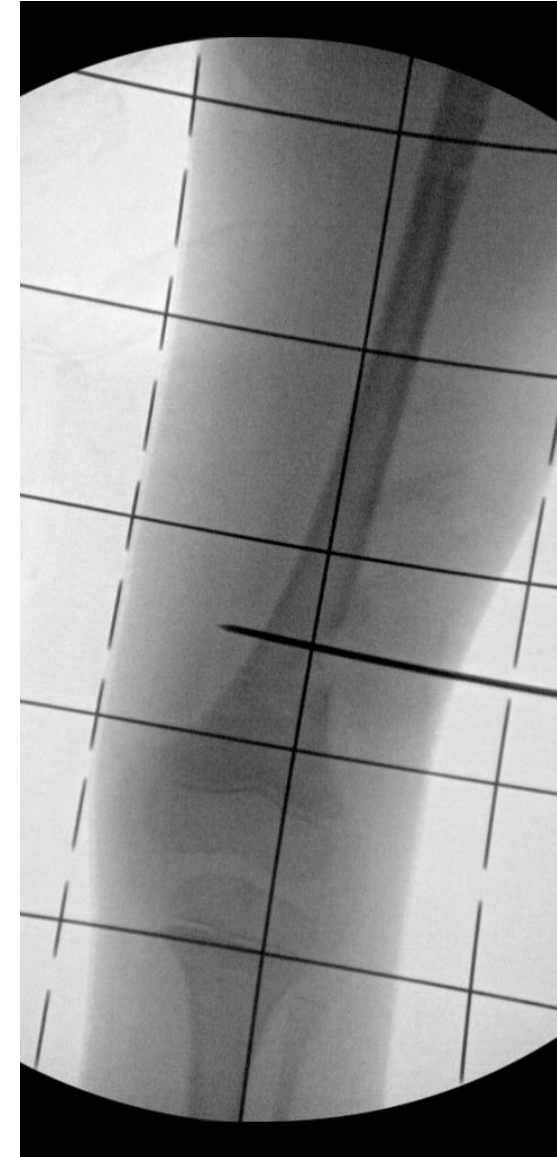
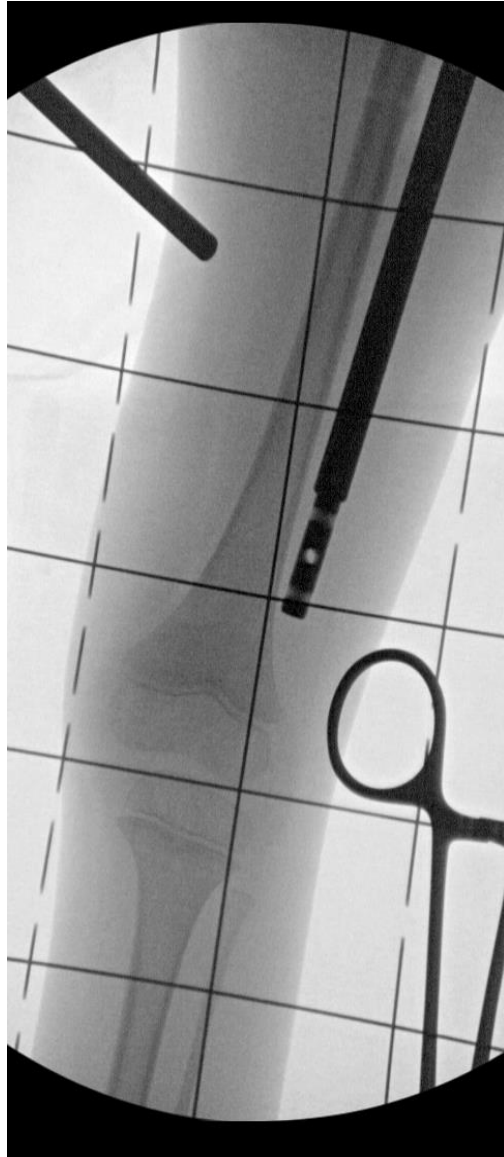Narrow Medullary Canal Too Narrow for a Nail



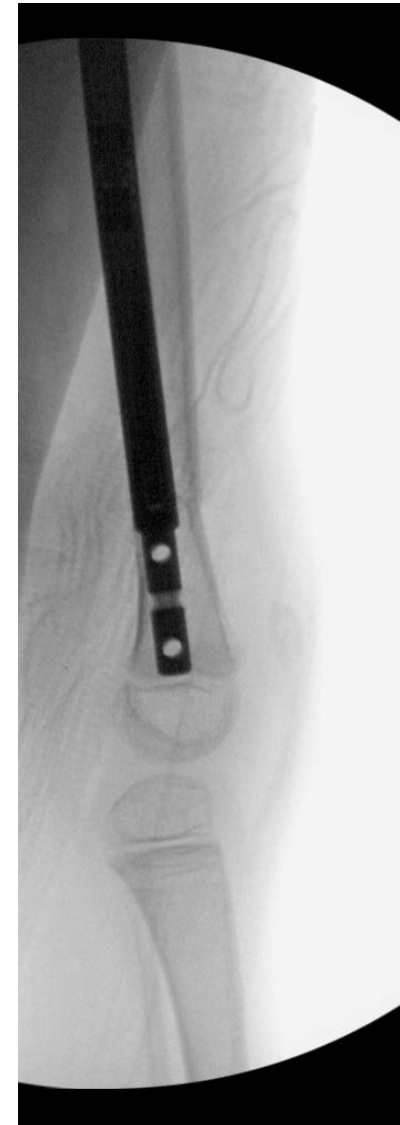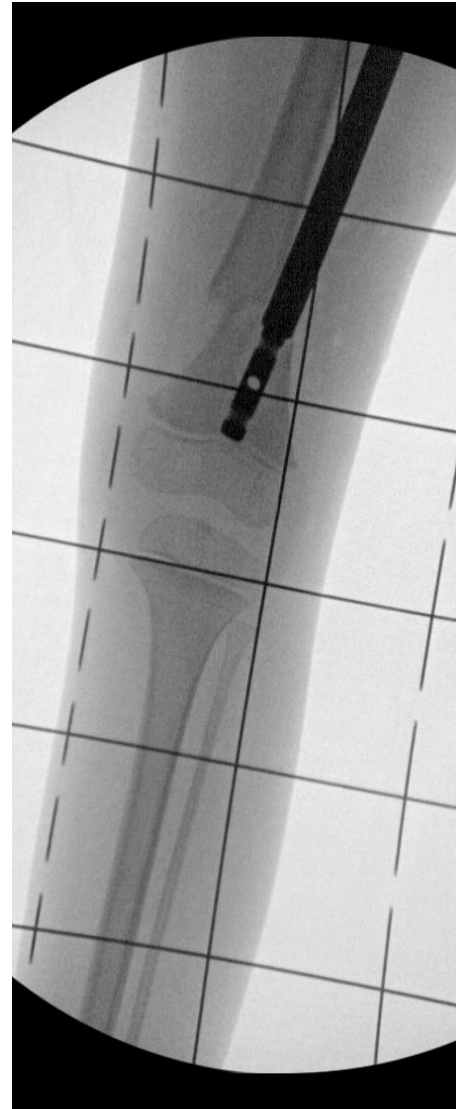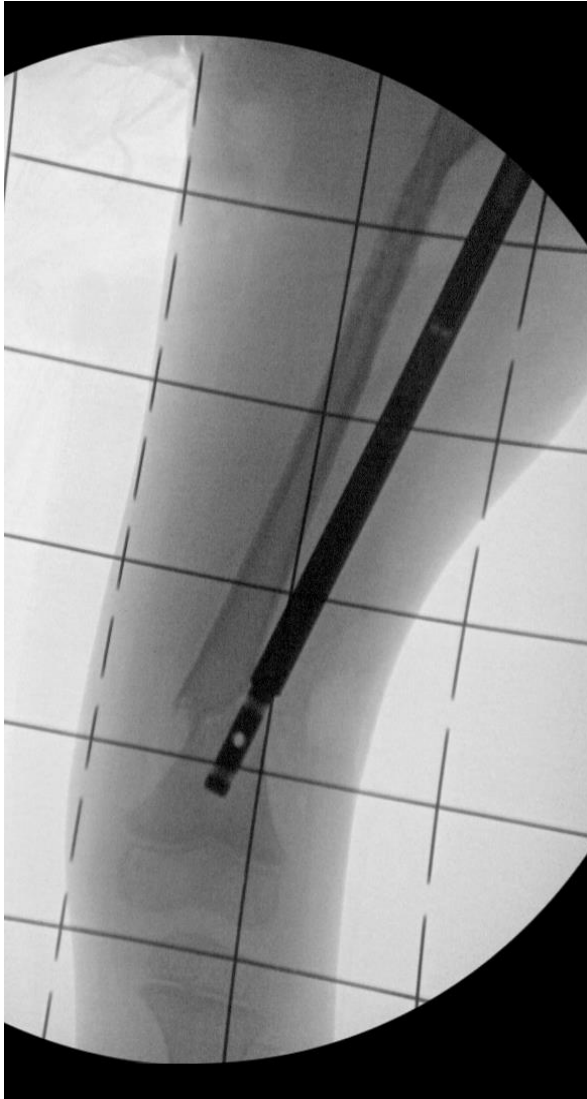Correction Valgus and Lengthening: Extramedullary



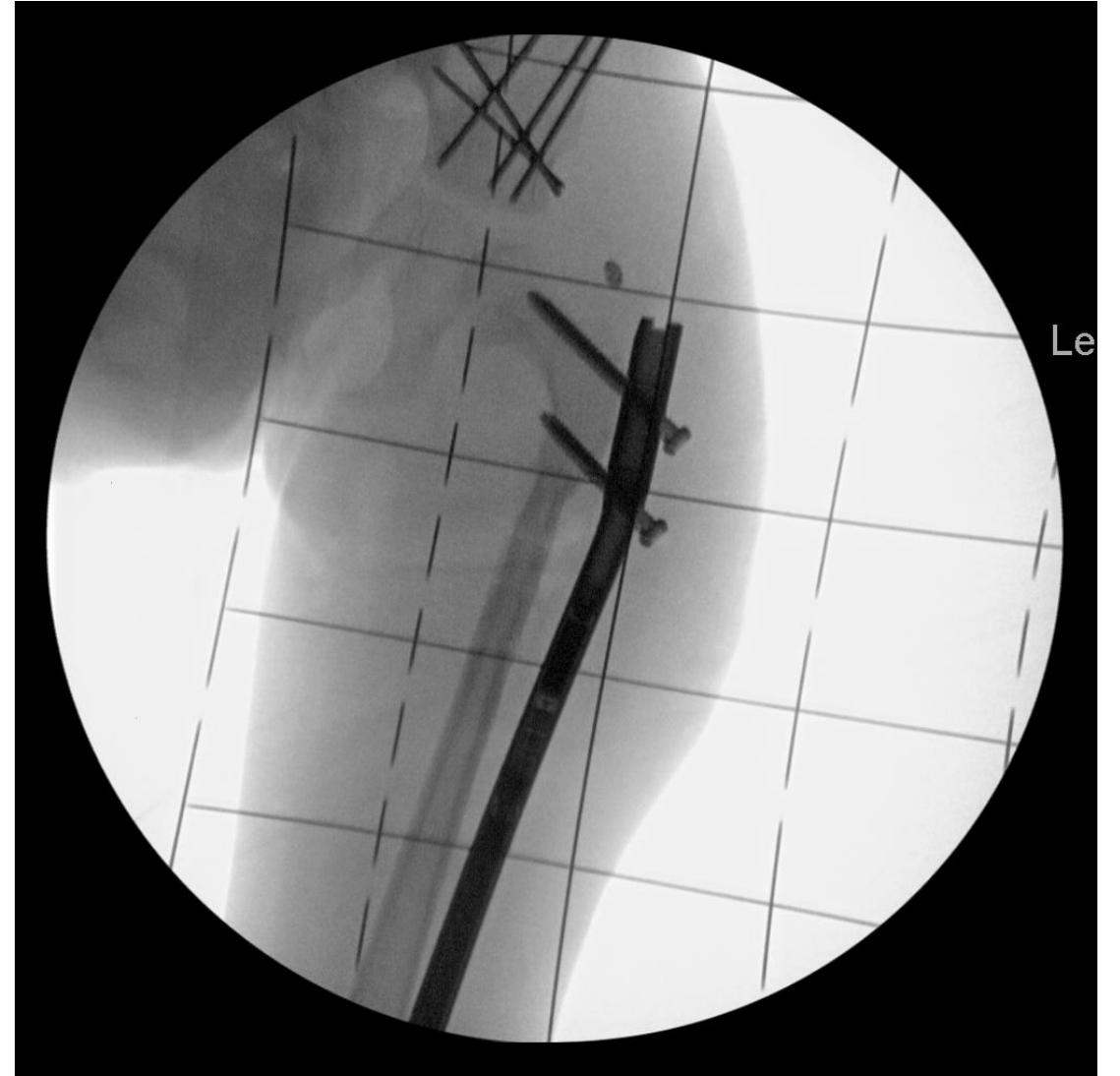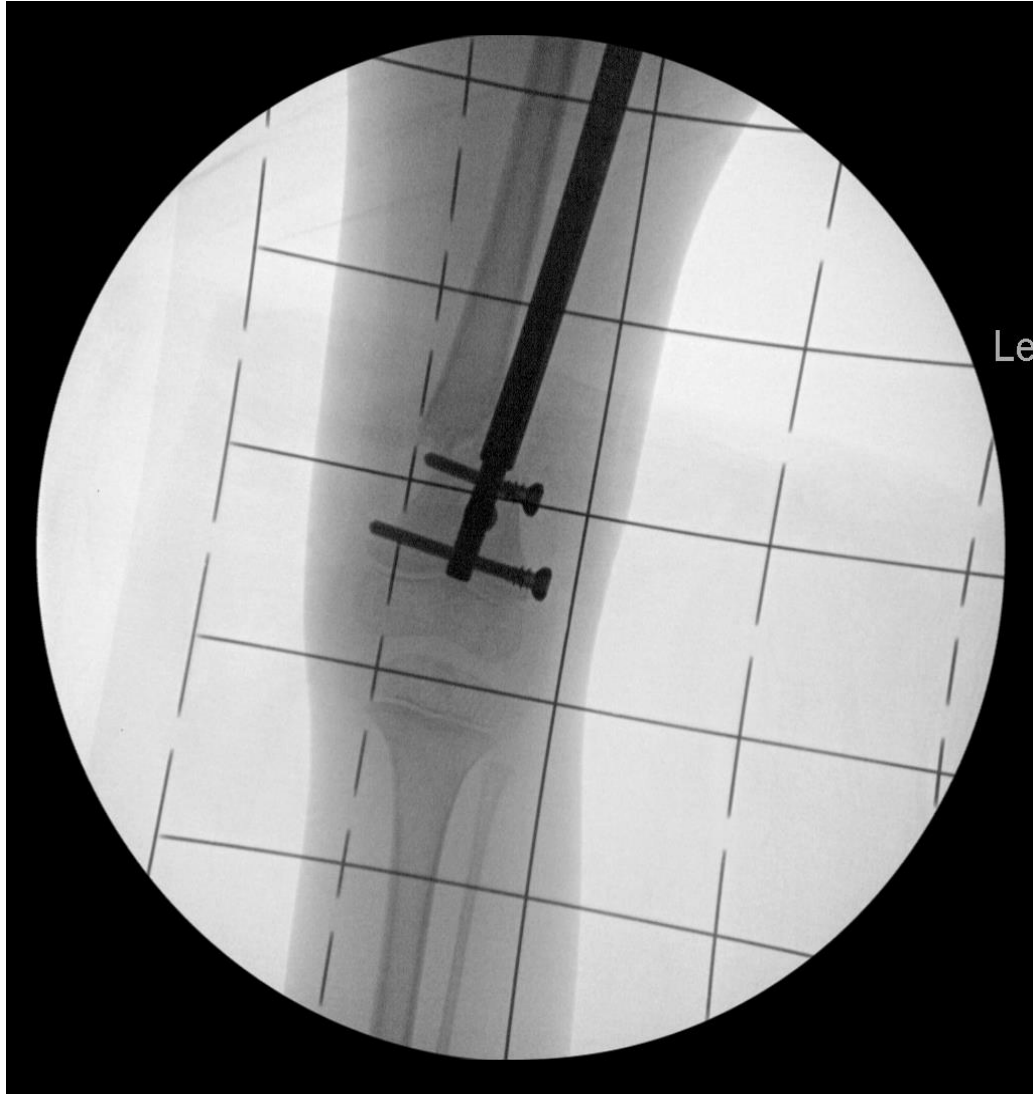Drilling and Osteotomy Distal Femur



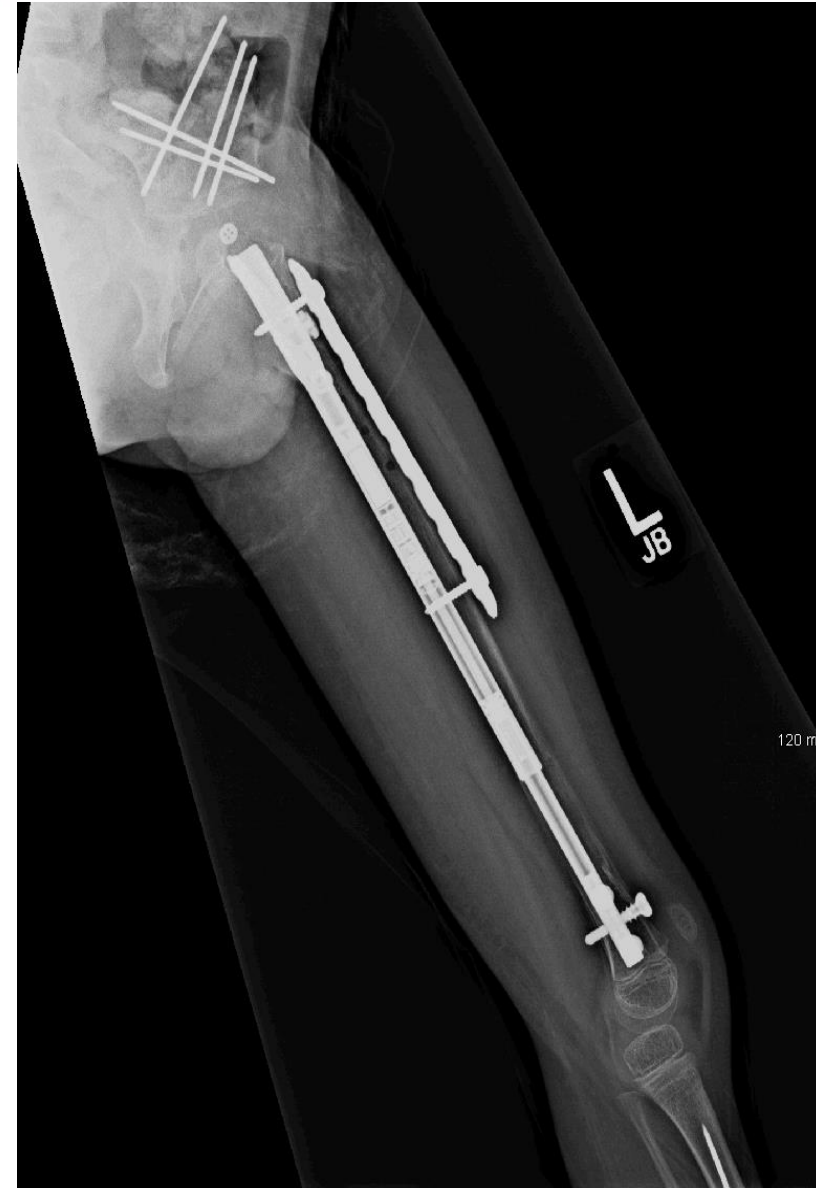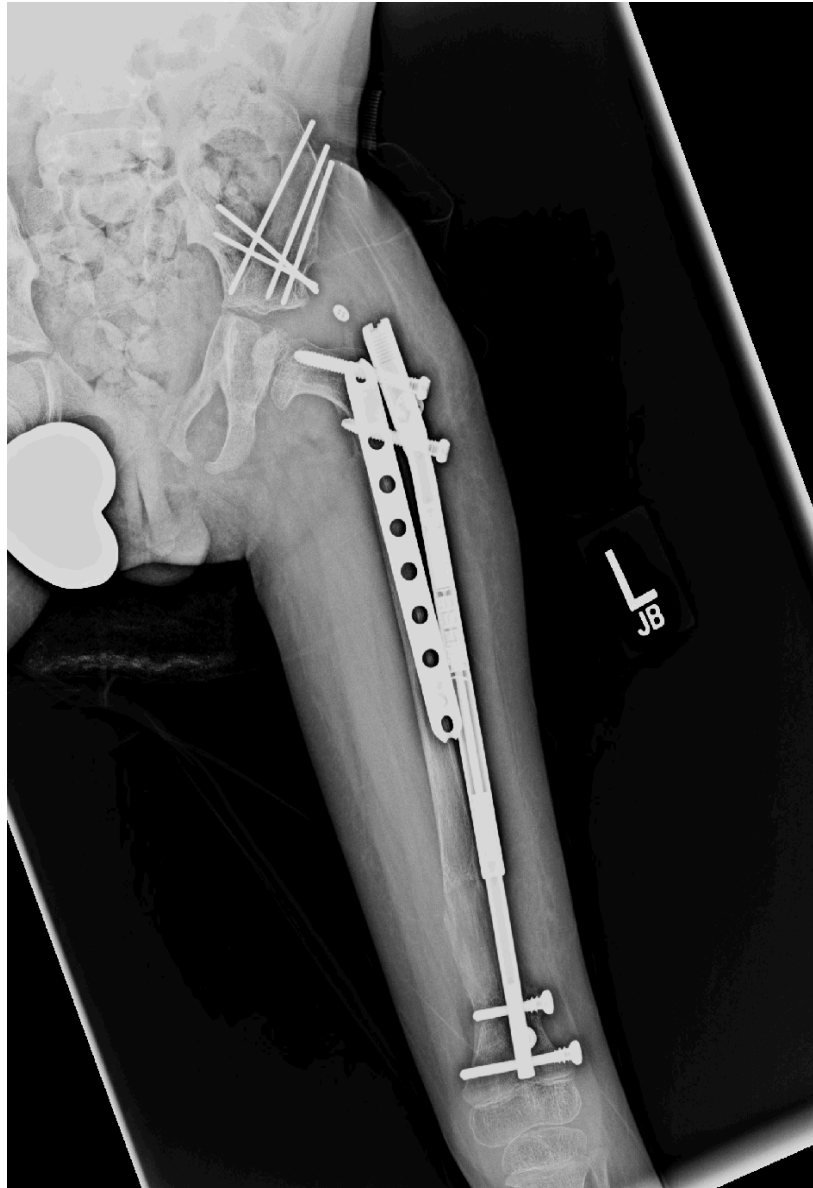Displace Osteotomy and Insert Precice



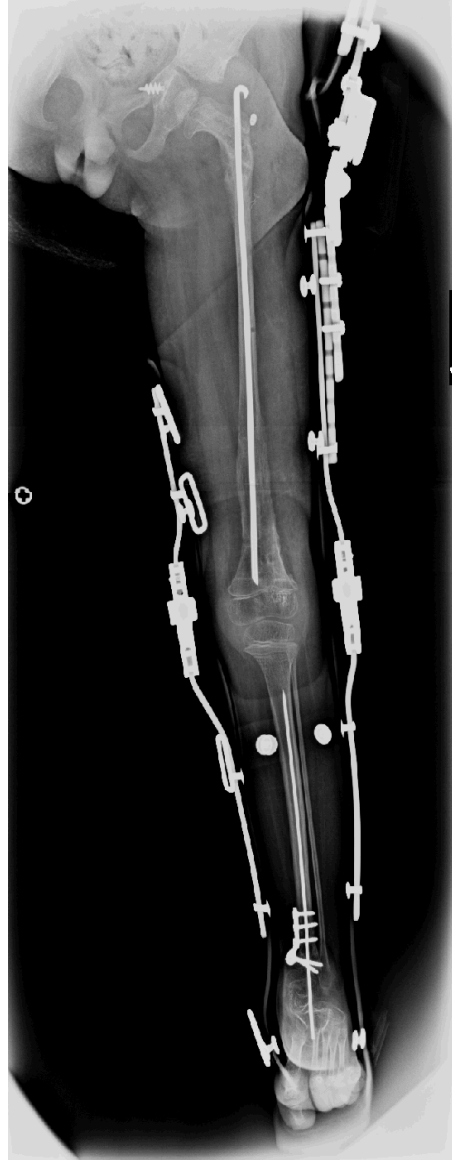Locking of Nail in Recon Mode



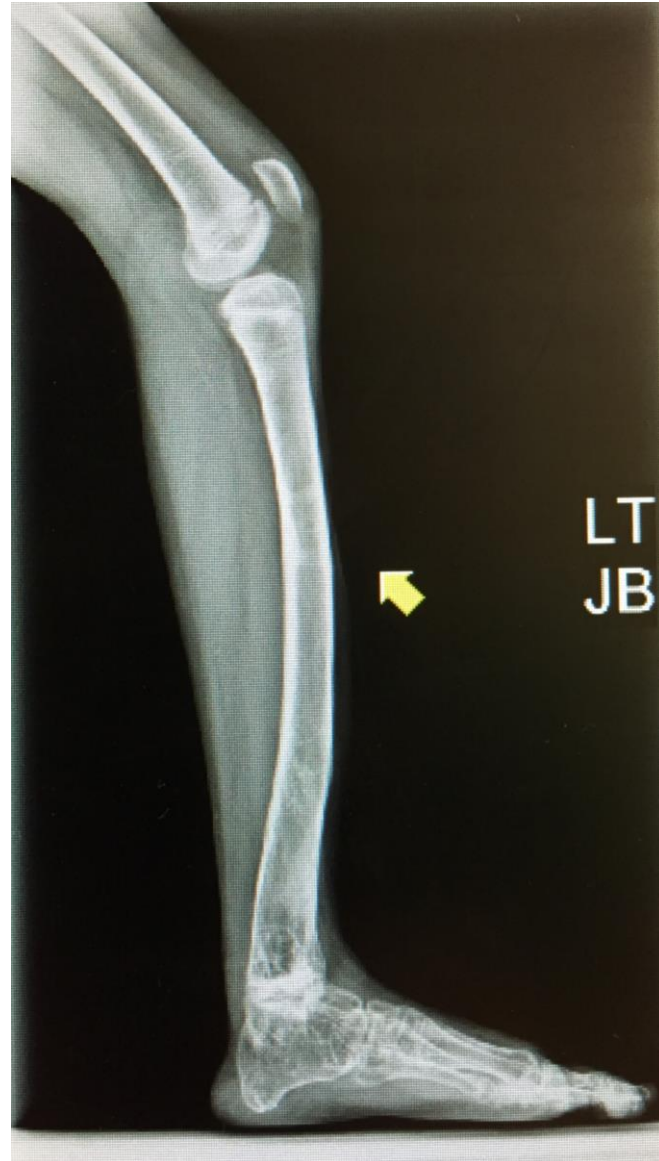Prophylactic Plate; Lengthening Distal Femur 5cm



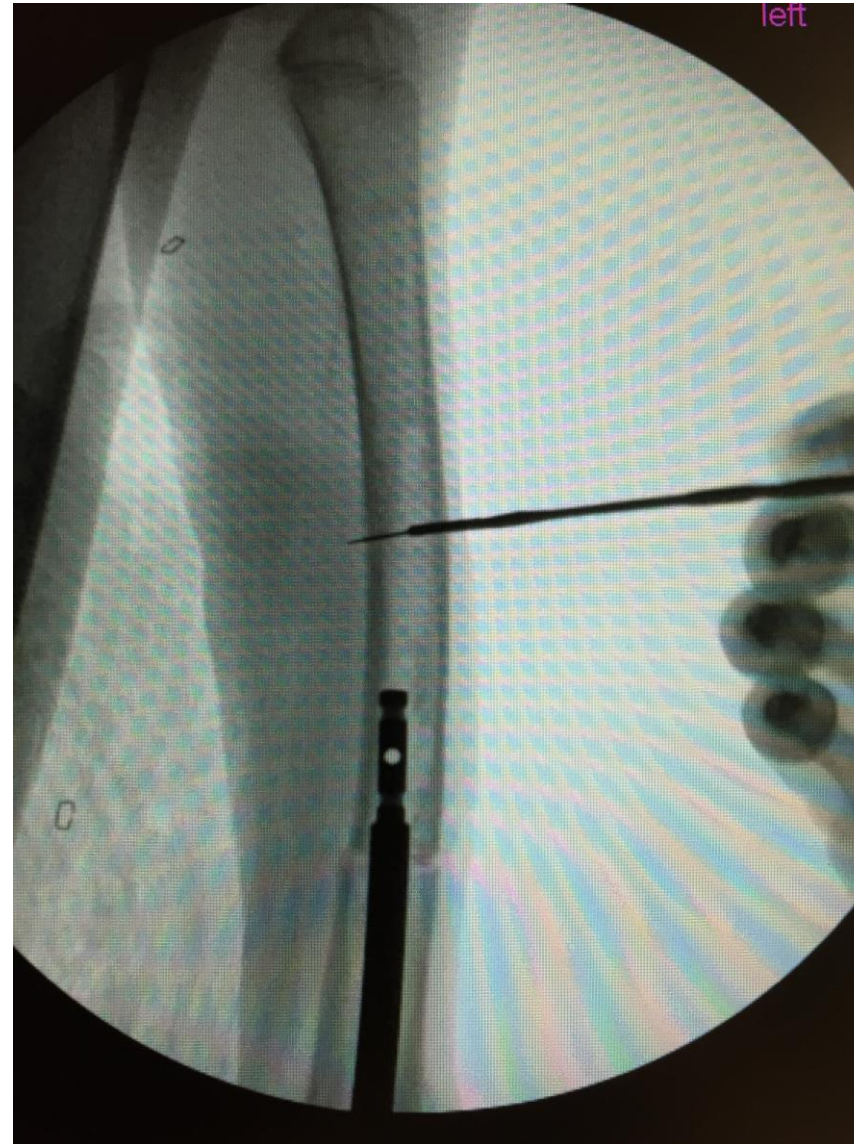
Removal Precice with Insert prophylactic rod

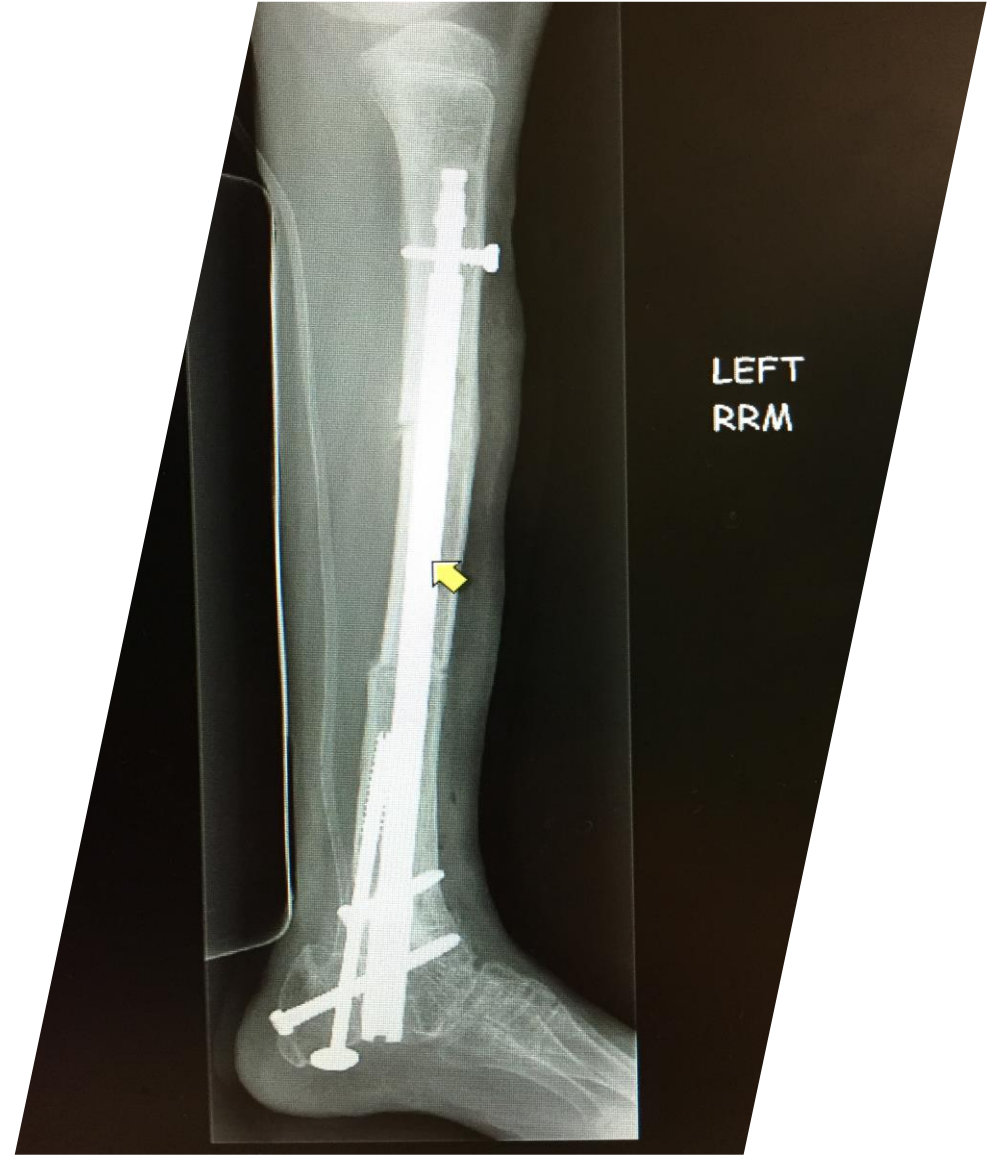
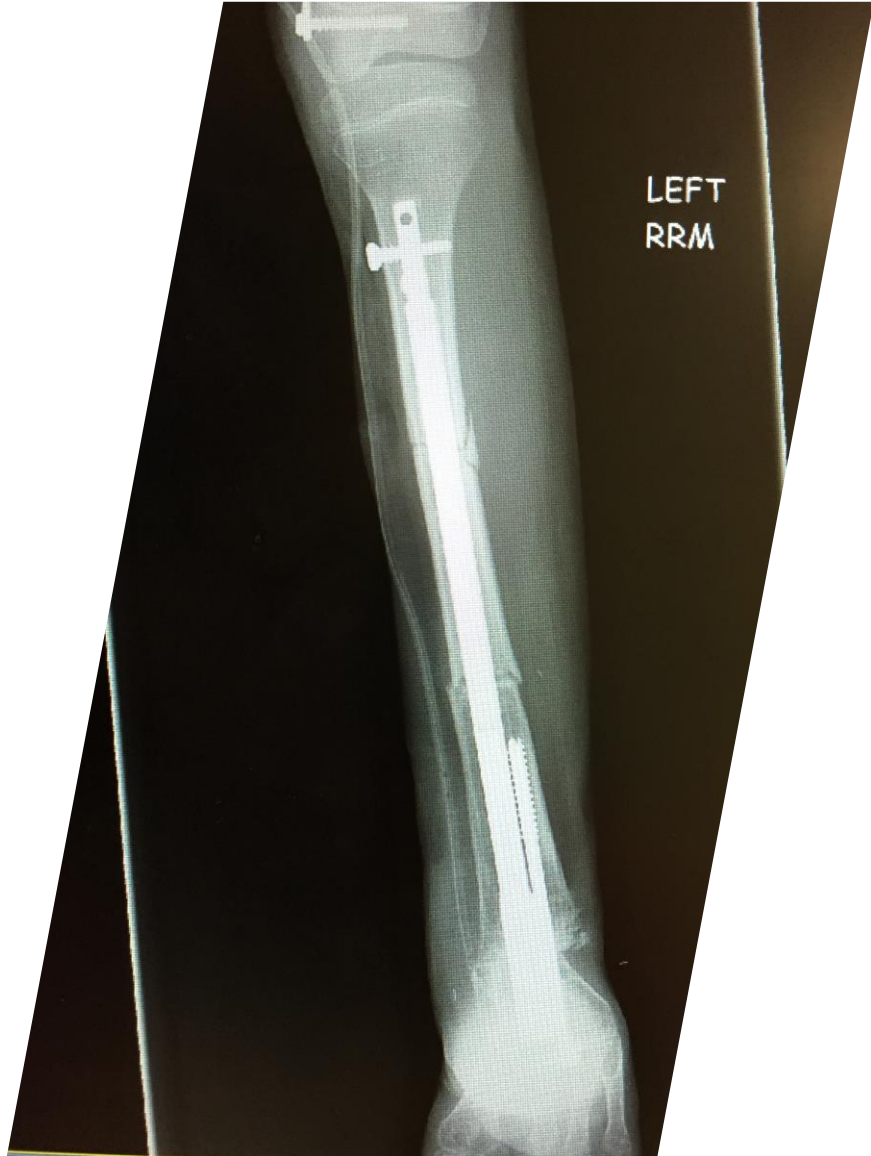
Apex of Angulation not at Lengthening Site



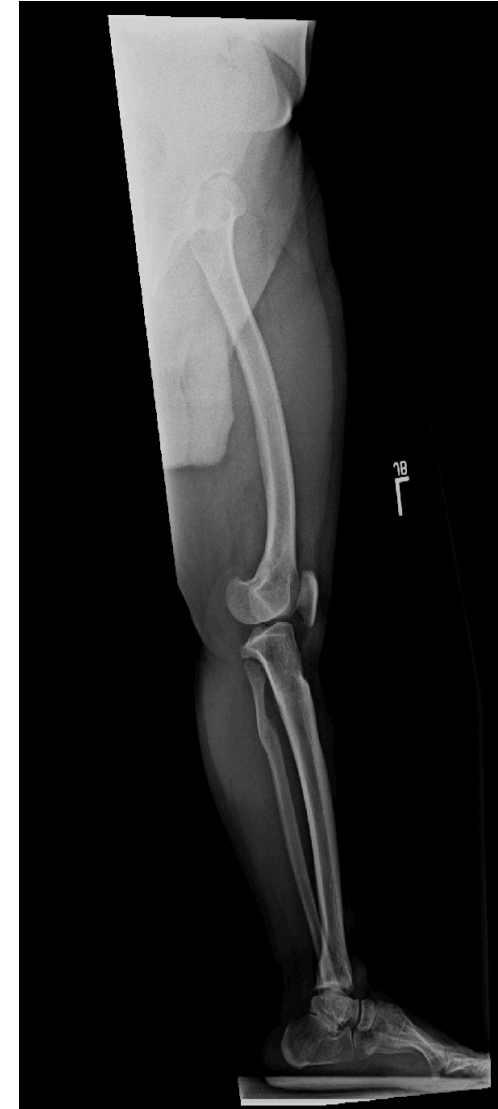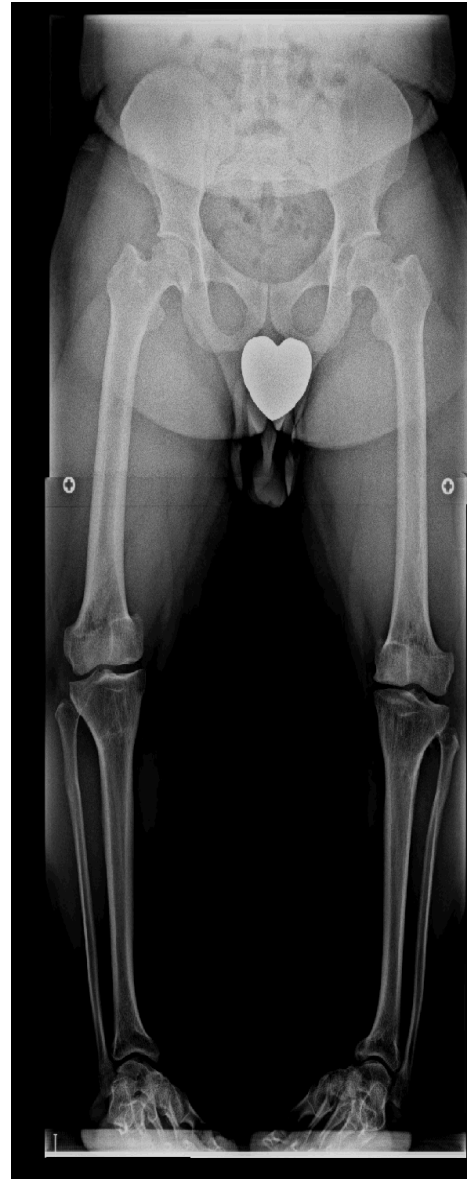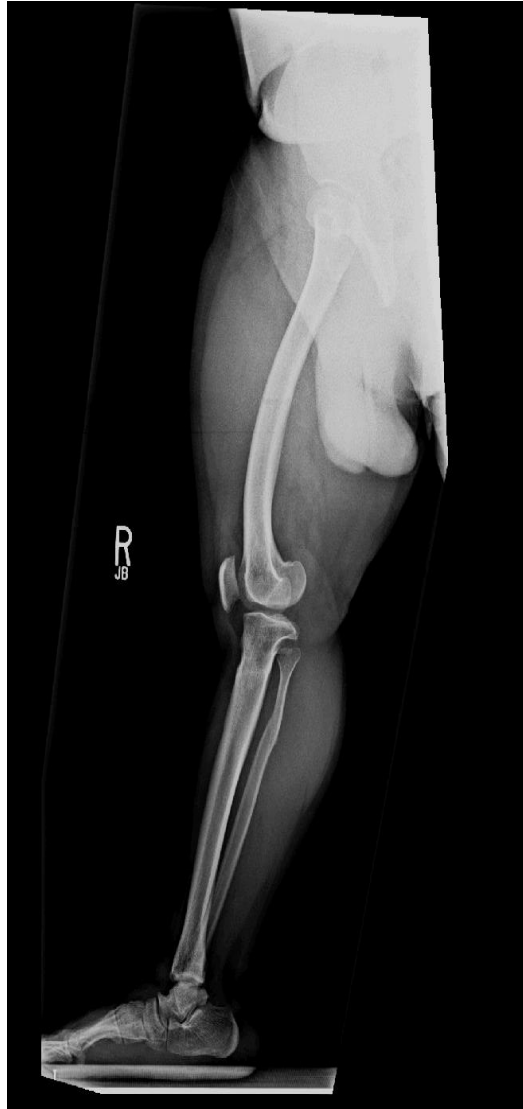Second Apex



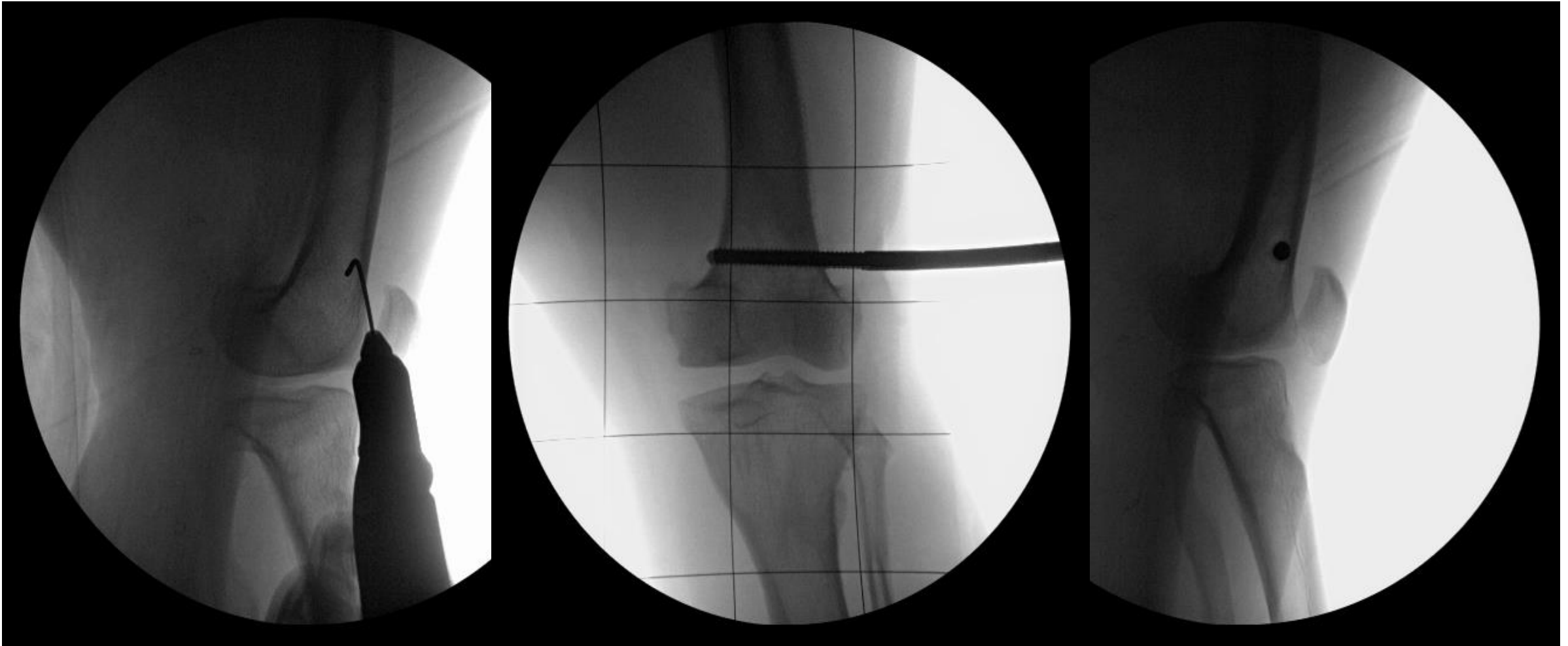

ChondroMetaphyseal Dysplasia

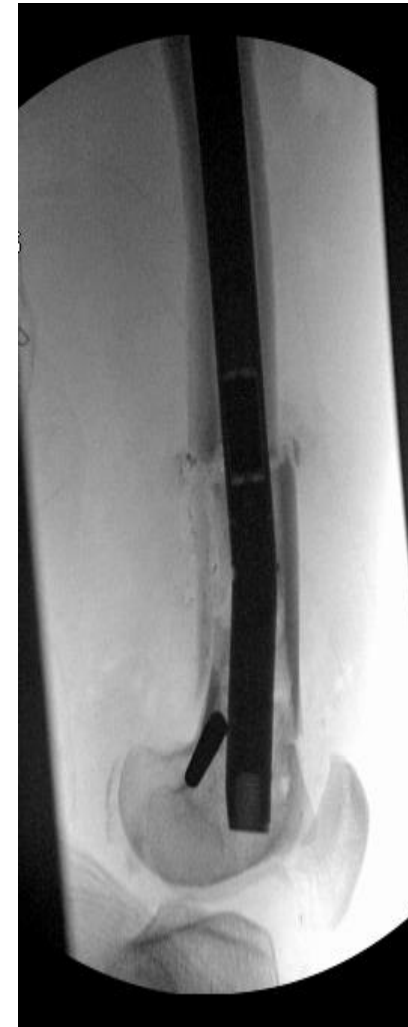
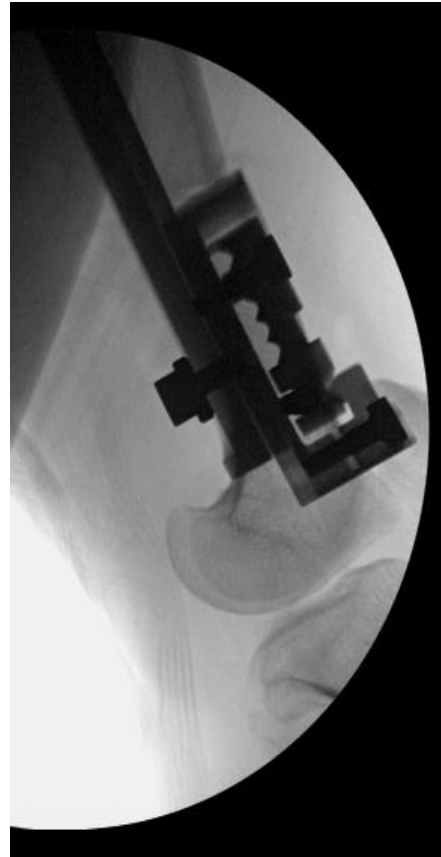
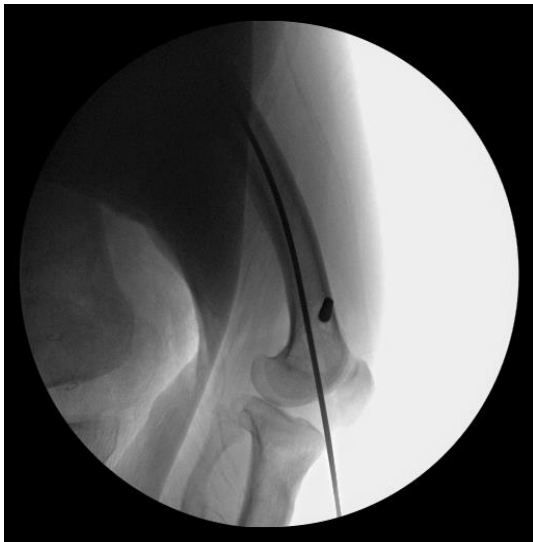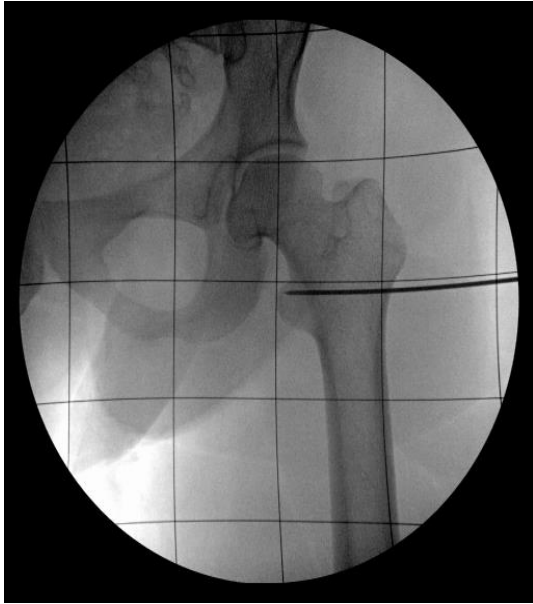Bowlegs and Short Stature



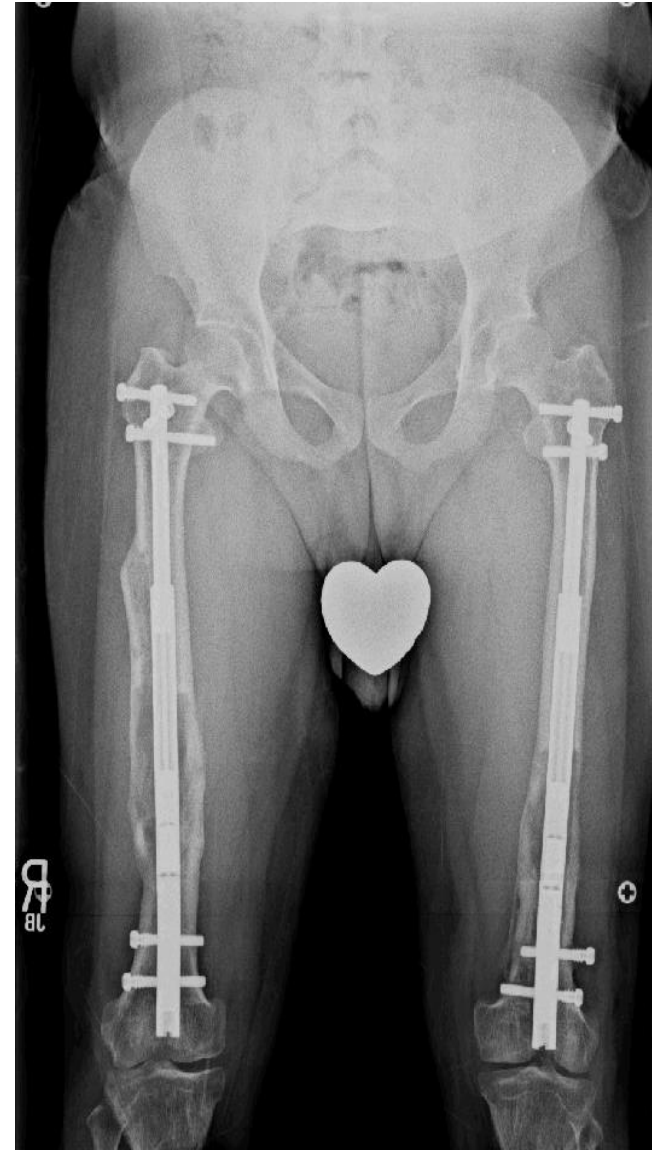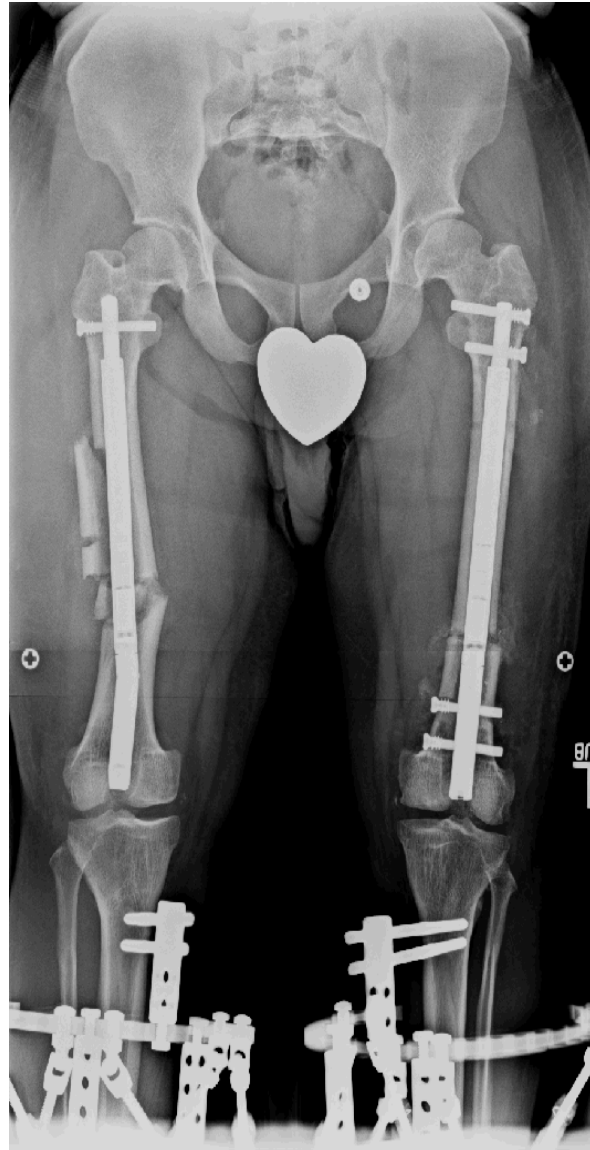
Fixator Assisted Nailing: Insert Pins



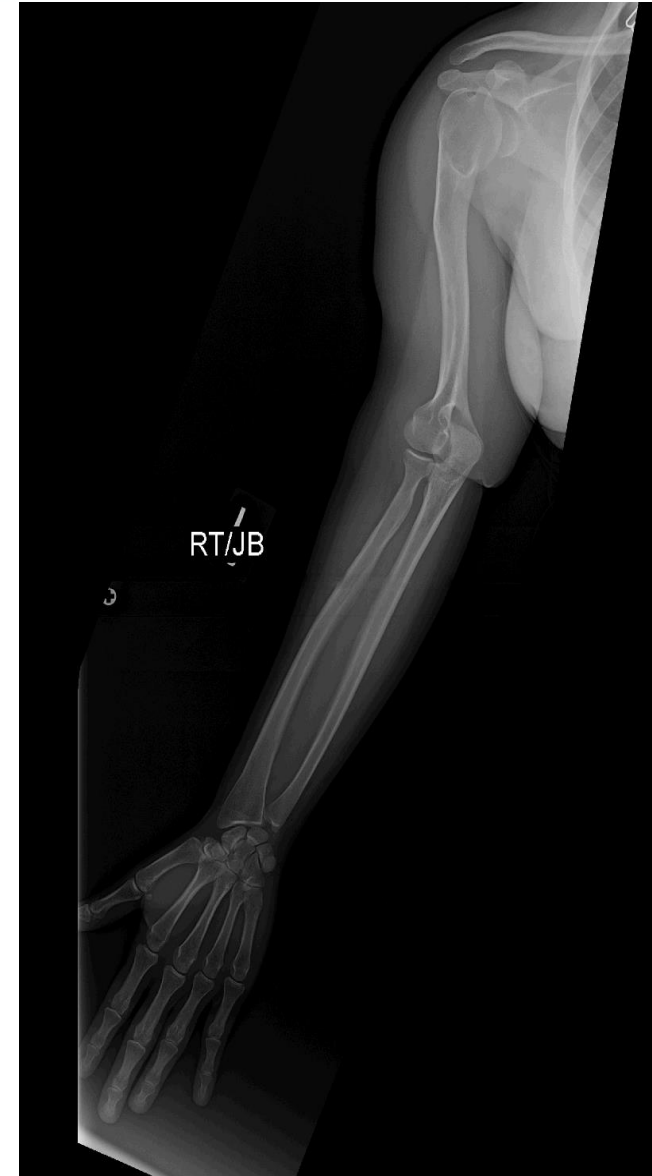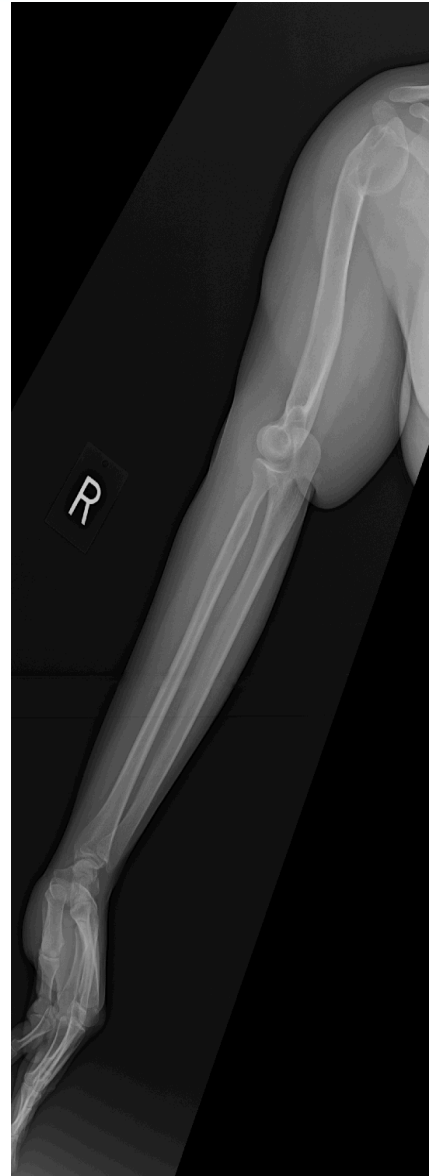Apply Ex Fix, perform osteotomy, Correct and Nail



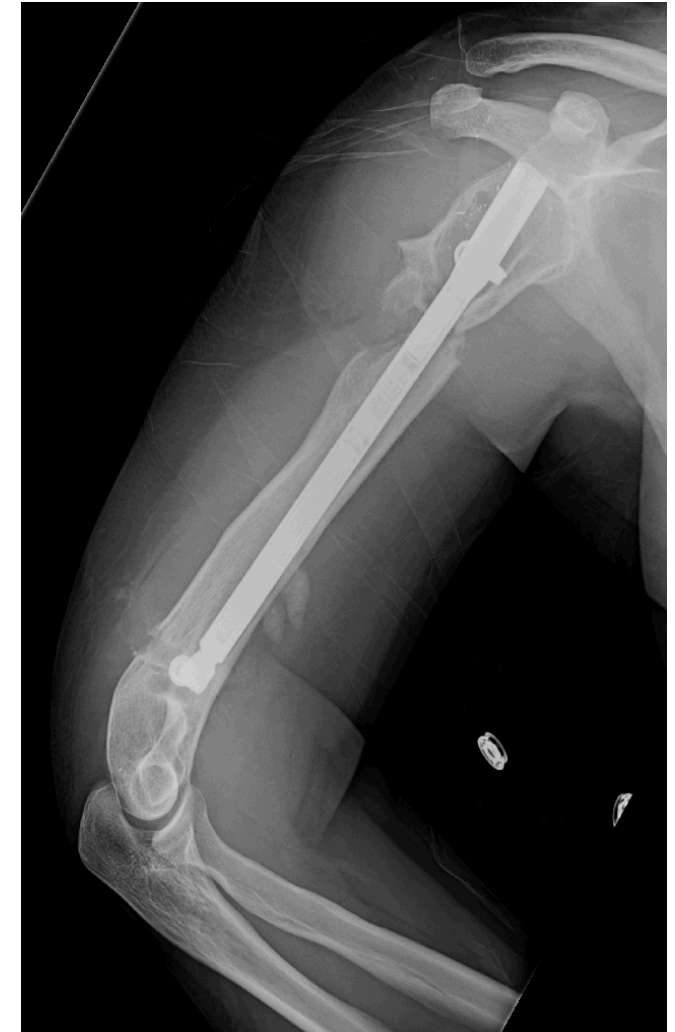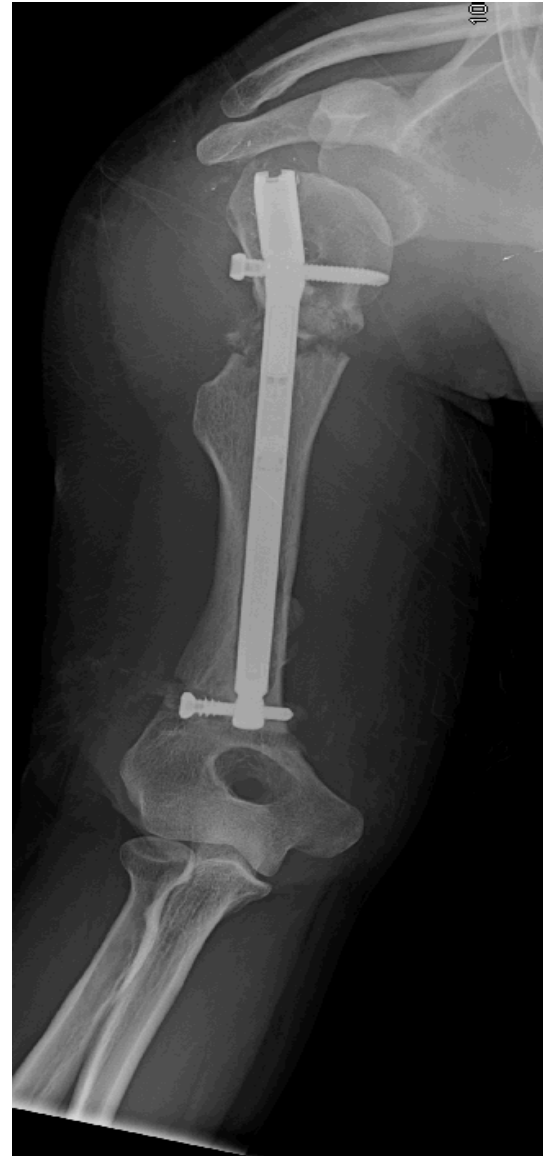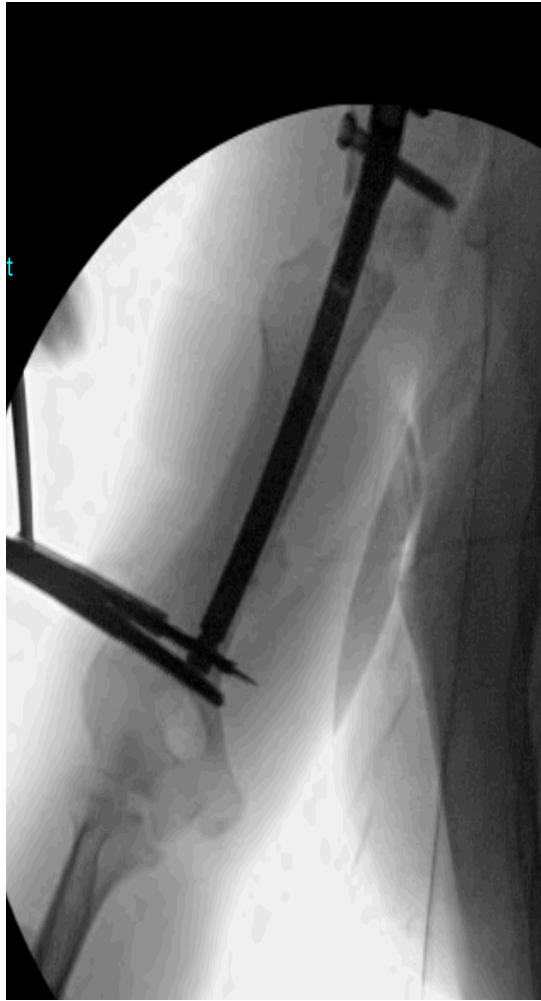Immediate Postop (left); After lengthening (right)



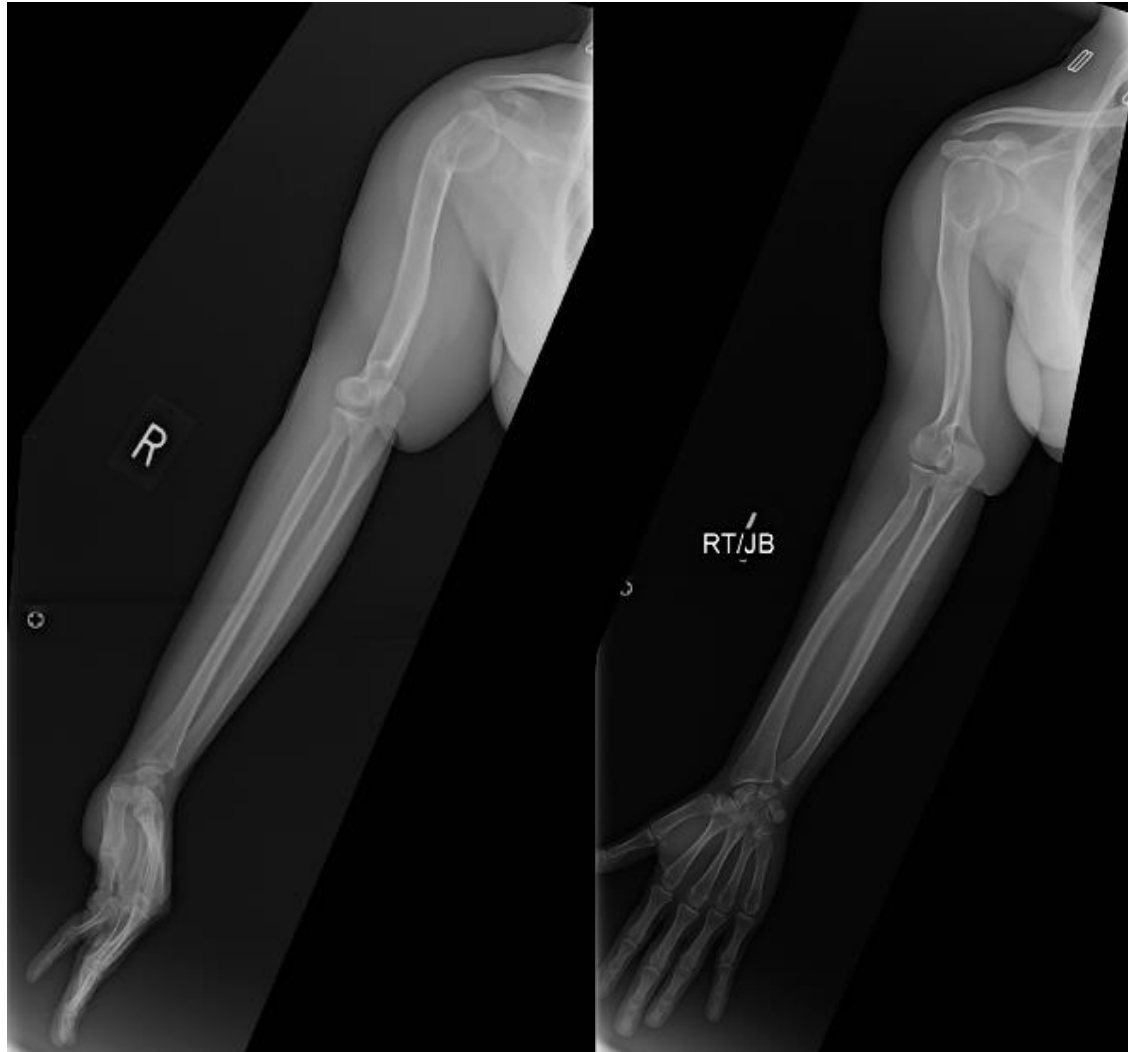
Humerus Varus, Extension, and ER deformities



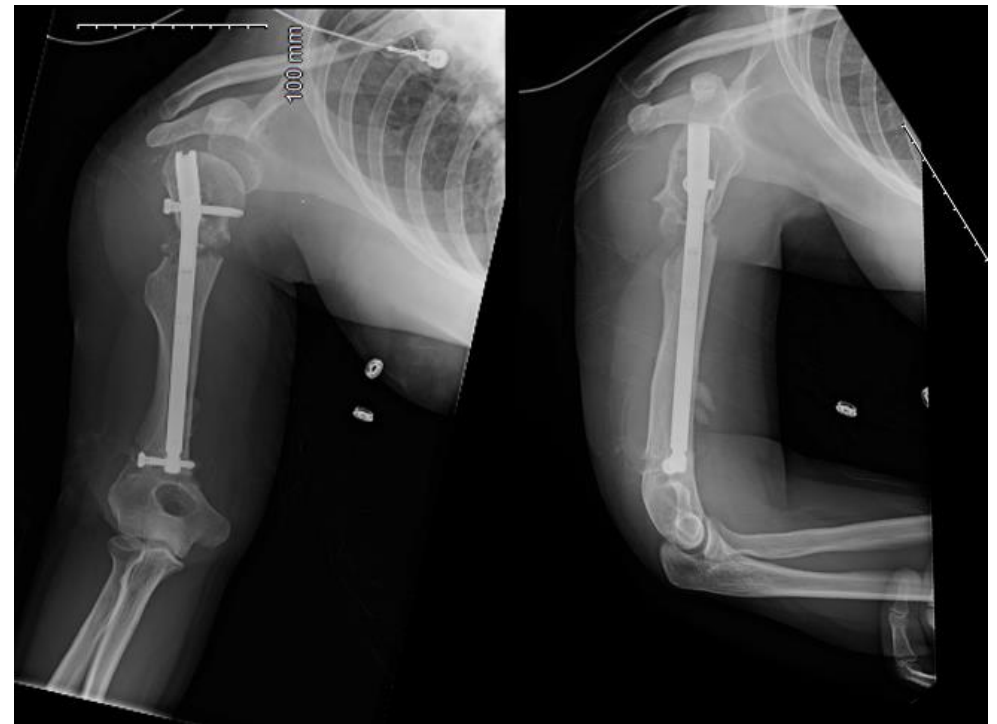
Fixator Assisted Nailing with Precice



LLD & Varus-Flexion Deformity Prox Humerus due to Neonatal Sepsis
Treatment with New Short Nails 150mm

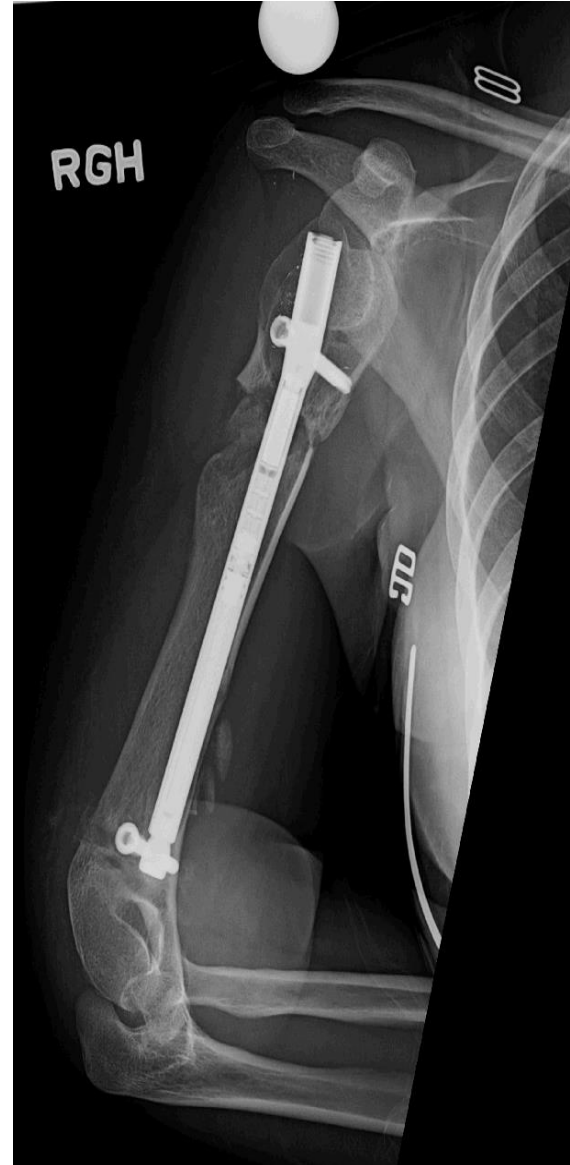
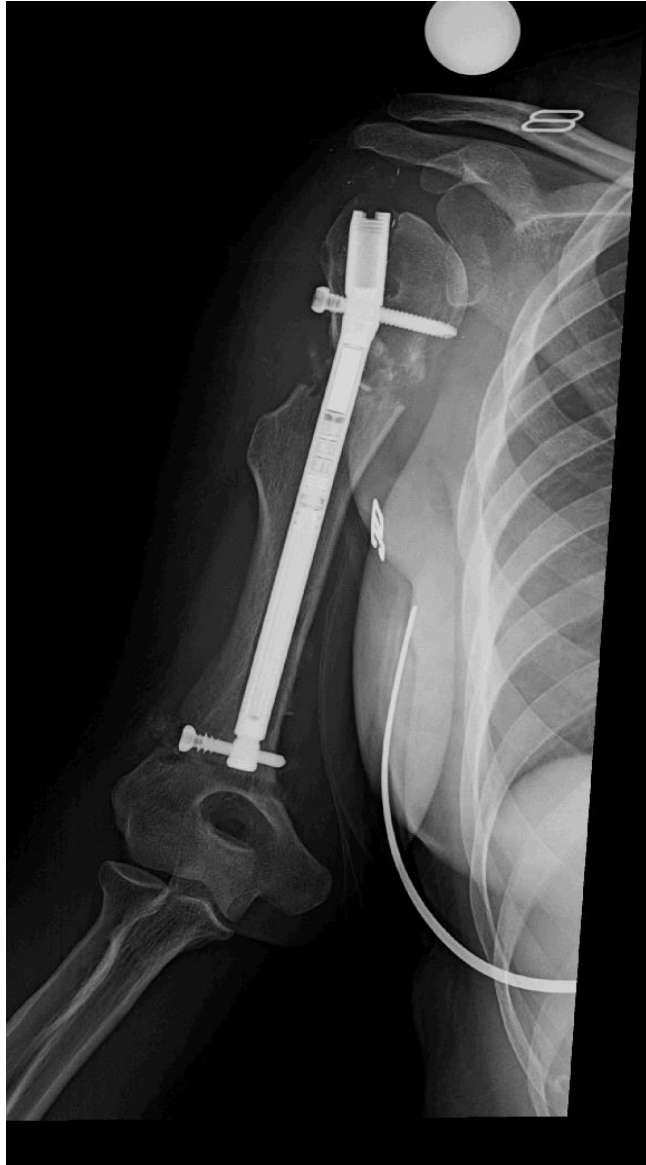
October 23, 2015

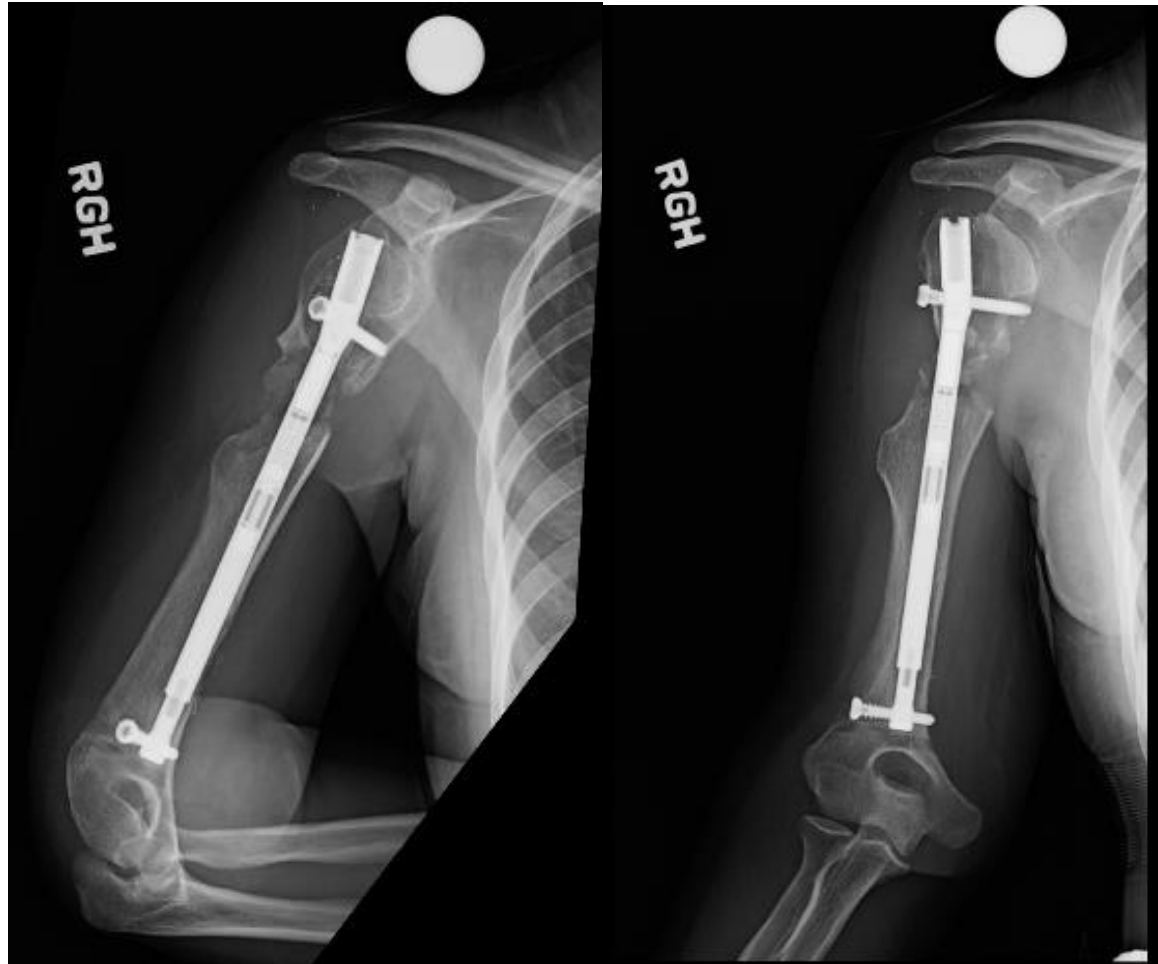


Aug 30, 2016

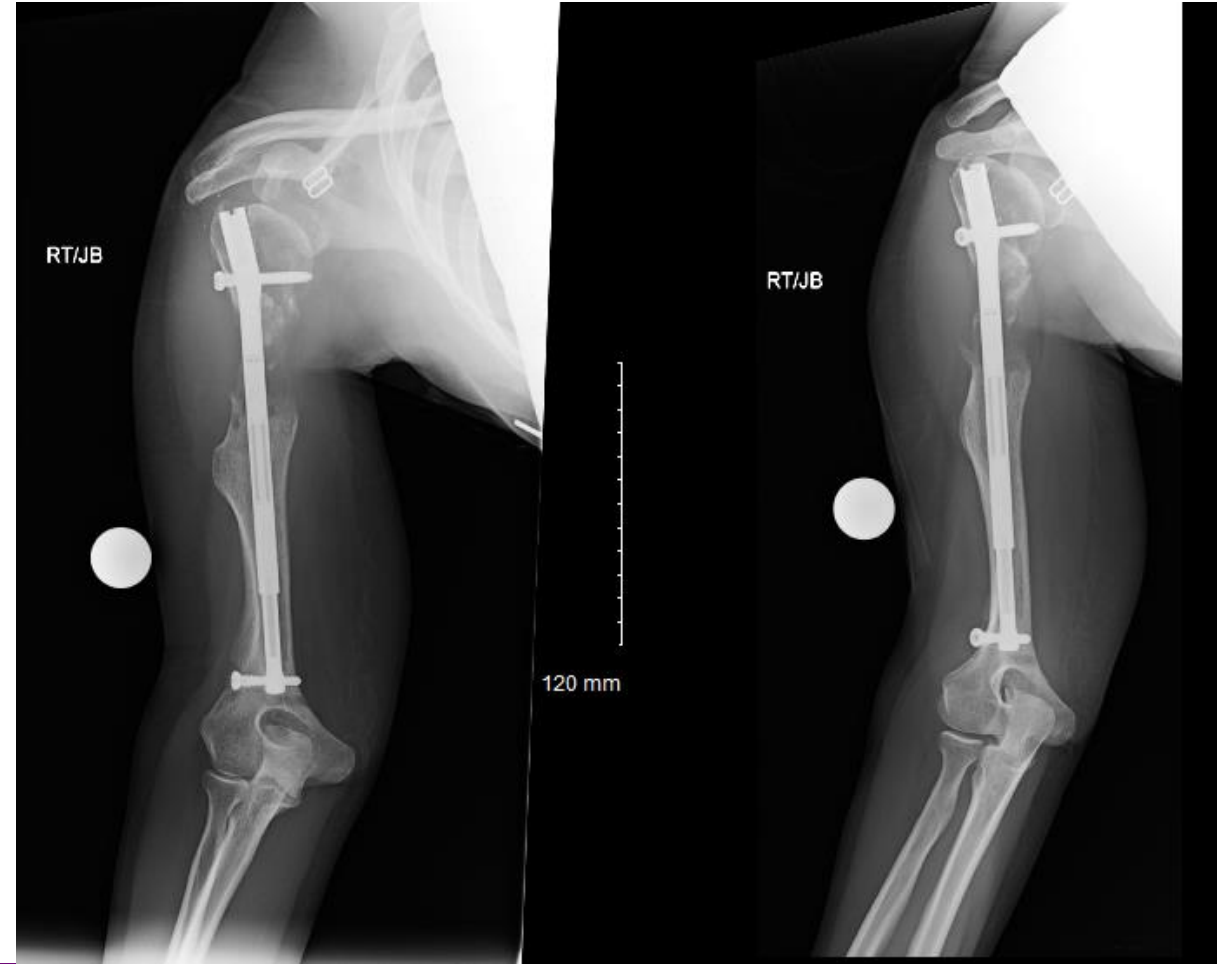
Started Lengthening



Lengthening

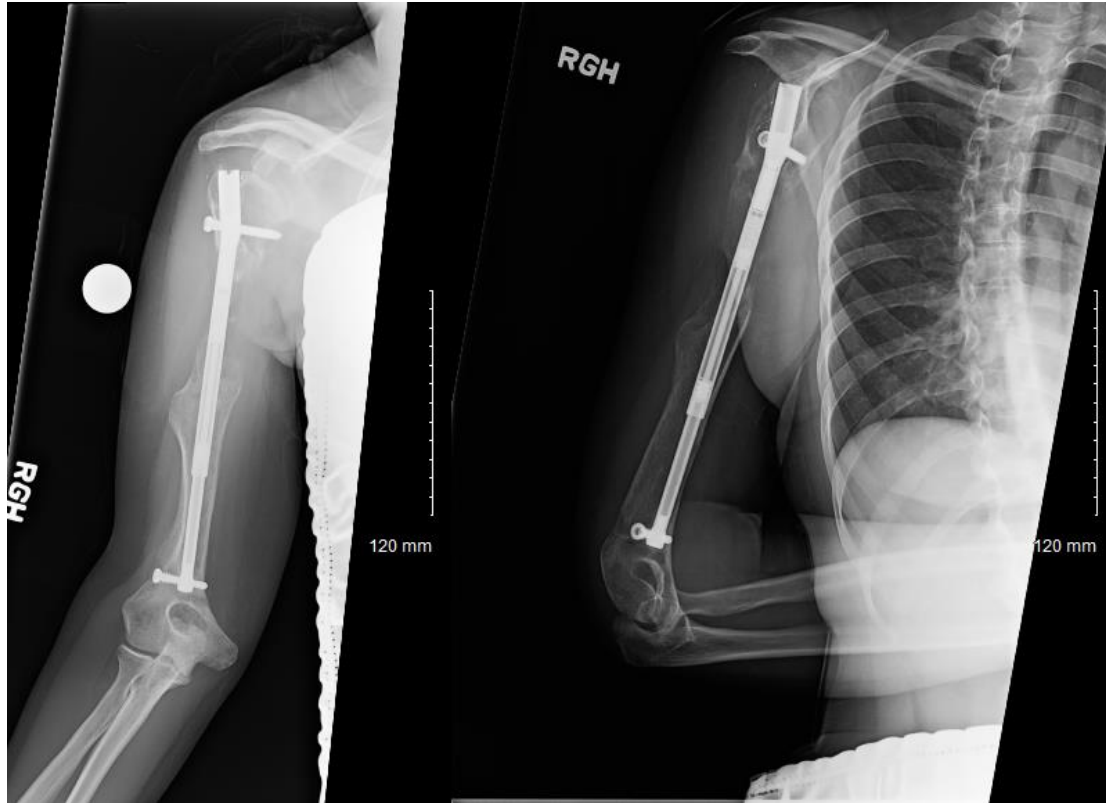


Sept 28, 2016

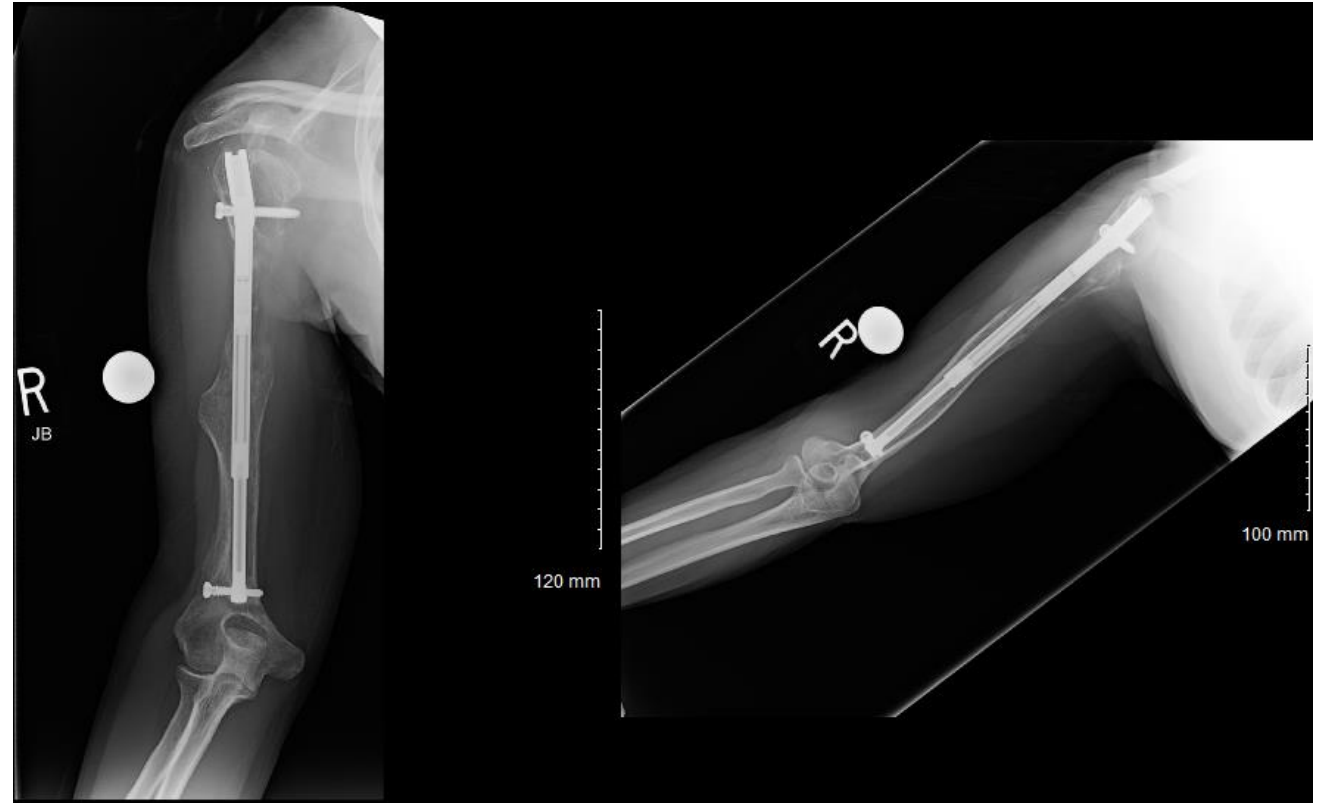


Oct 25, 2016

5cm lengthening

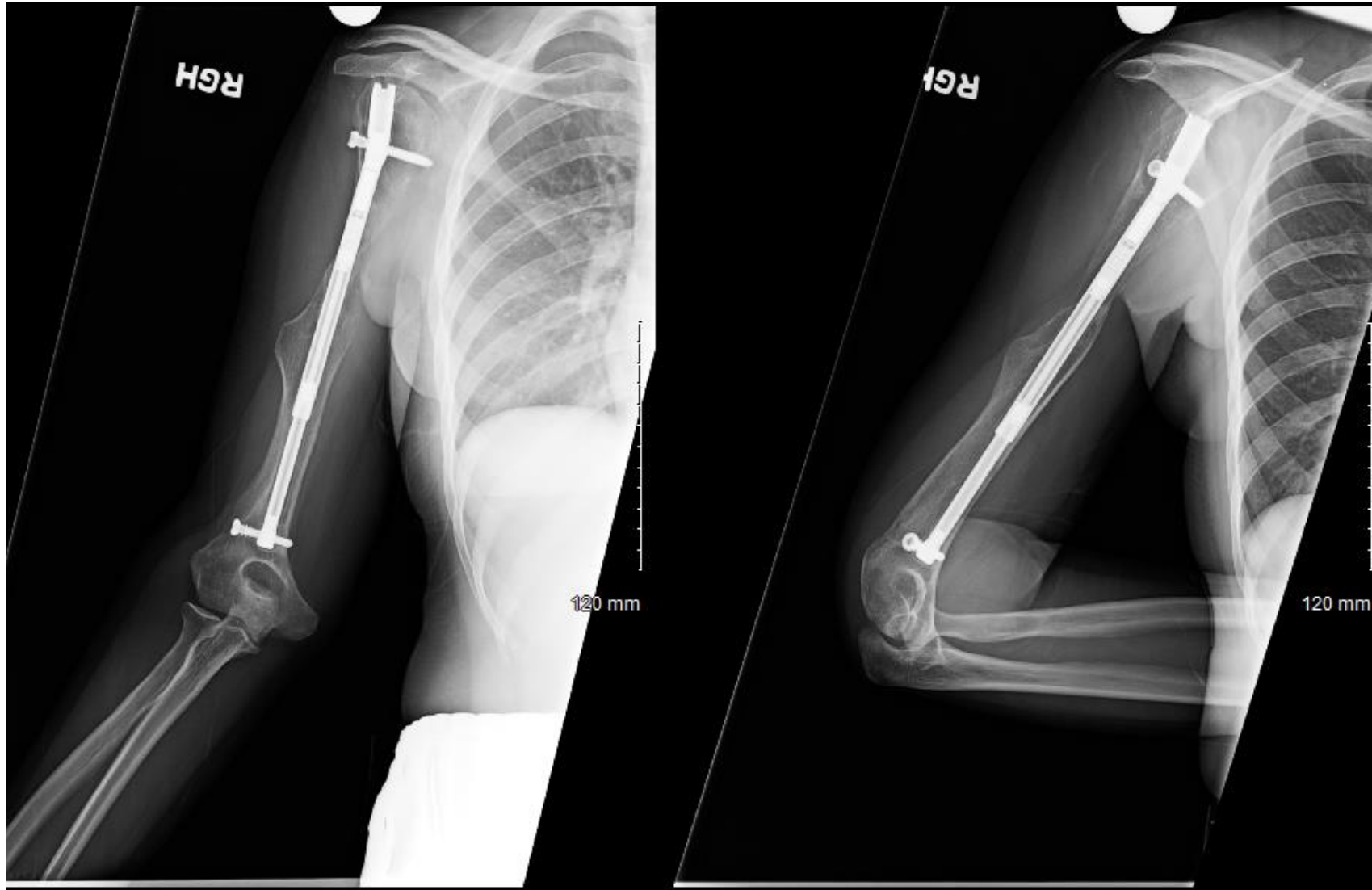

Dec 5, 2016



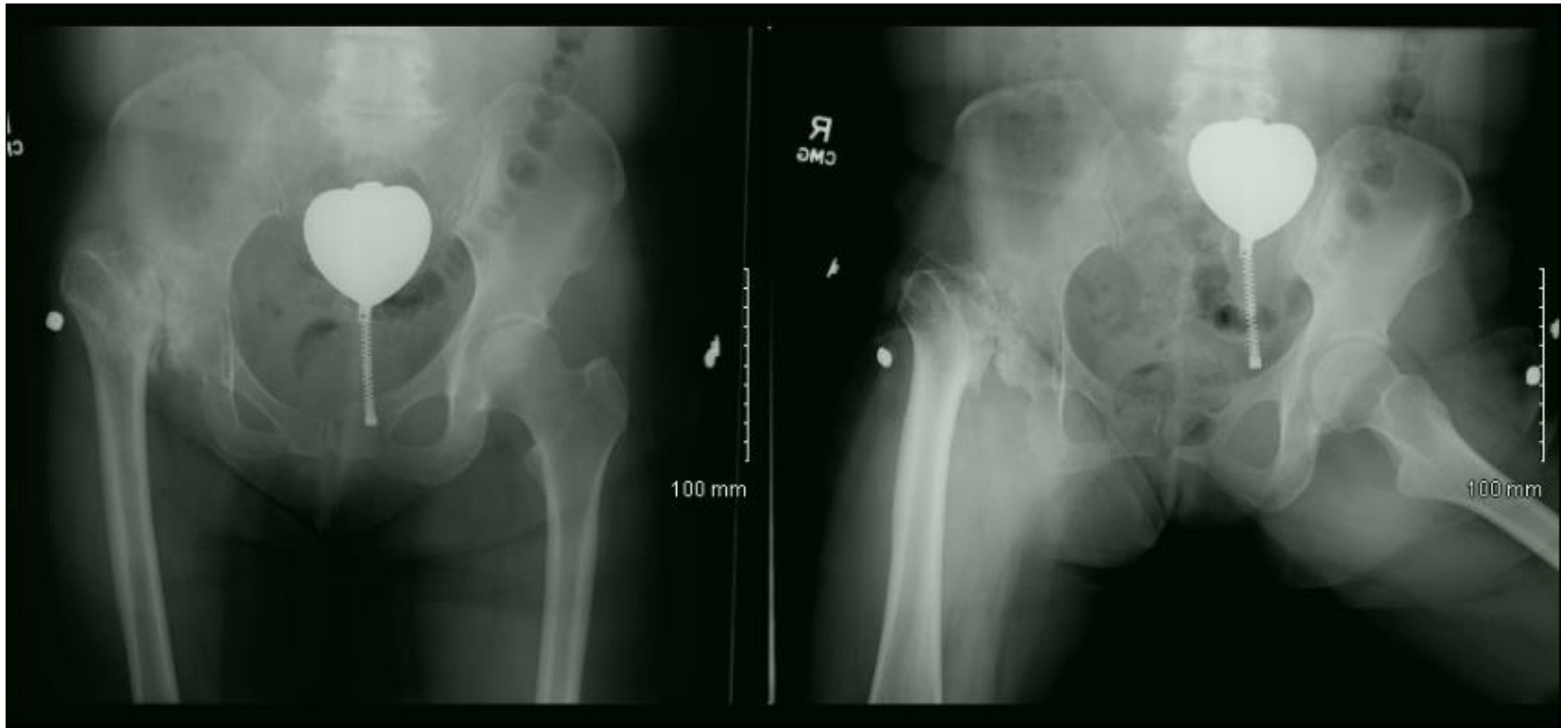Jan 5, 2017

Consolidation



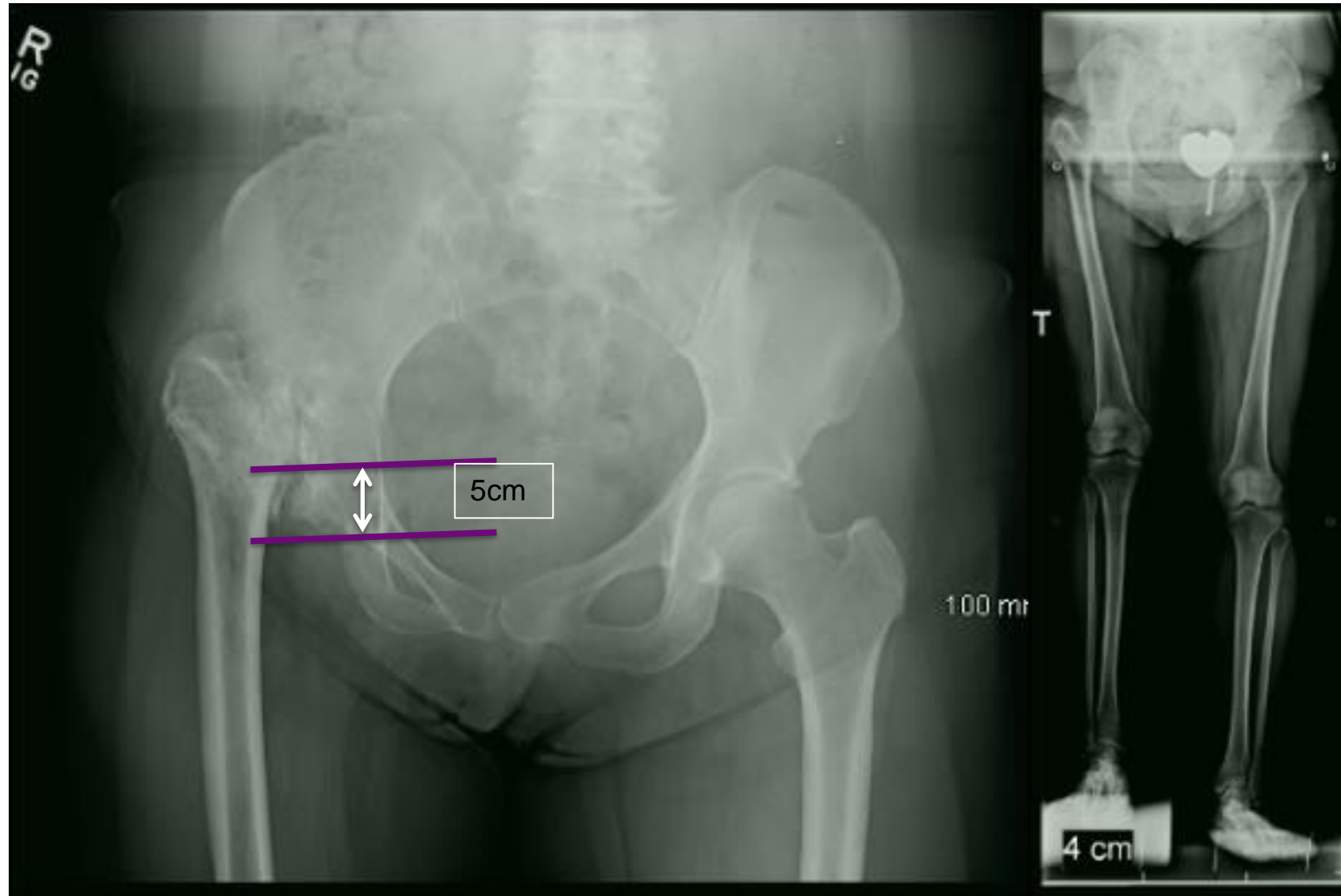
March 17, 2017

Proximal Migration of Resection Arthroplasty of Hip



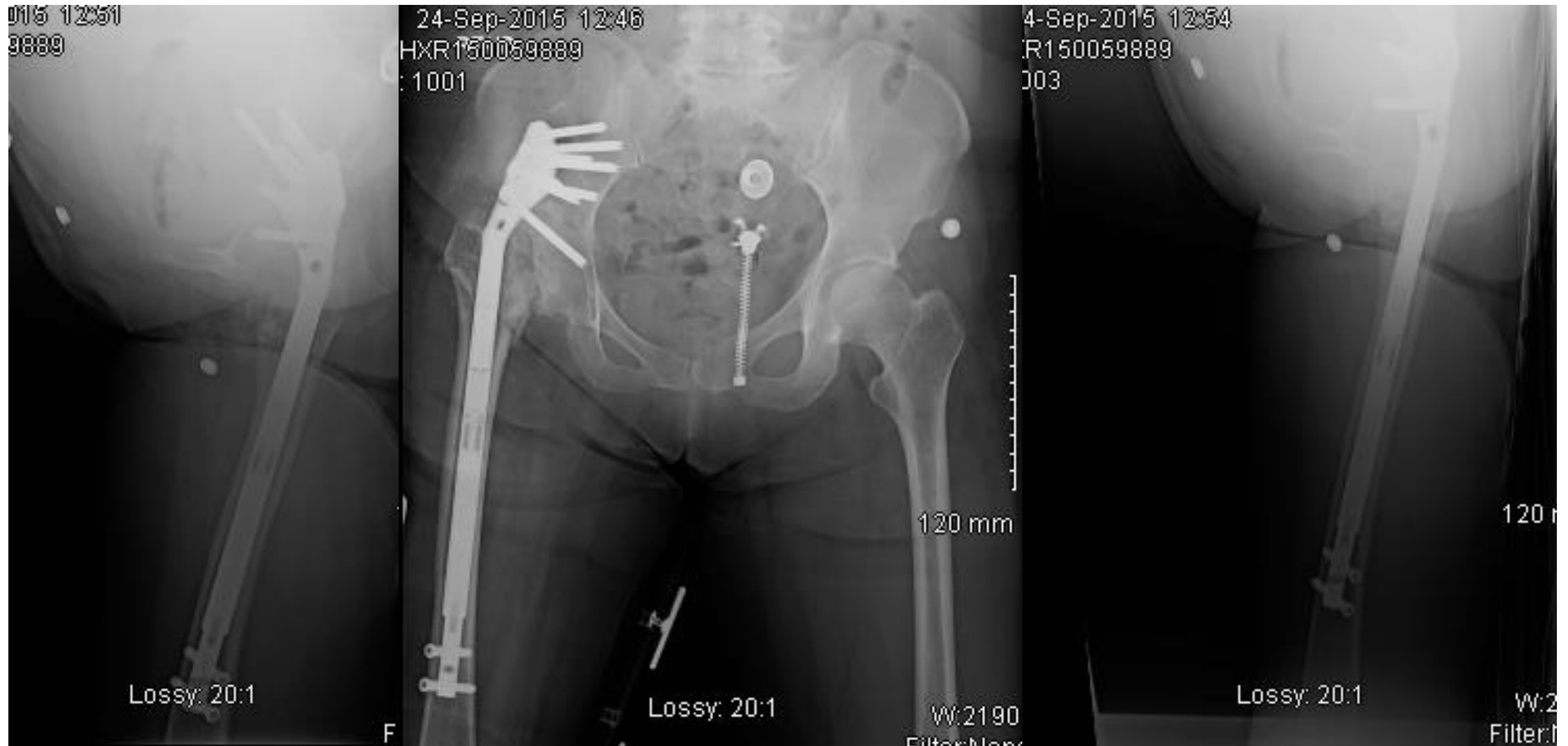July 26, 2013

55 y.o. woman with dislocated hip: LLD = proximal migration



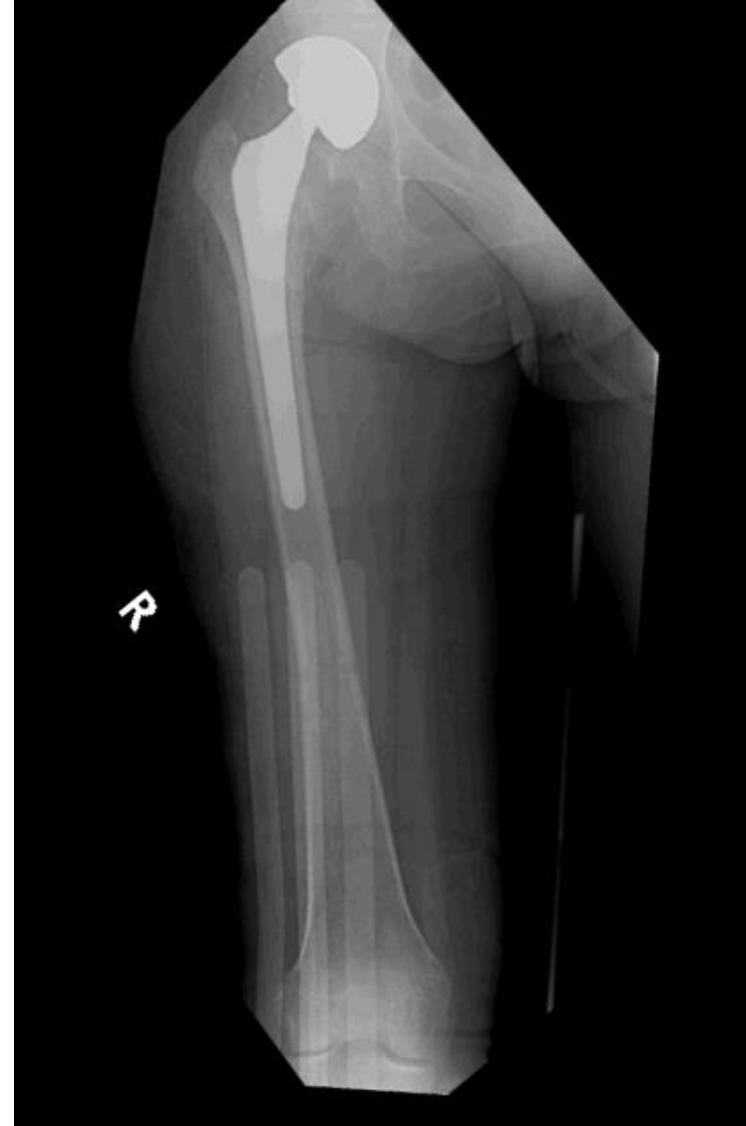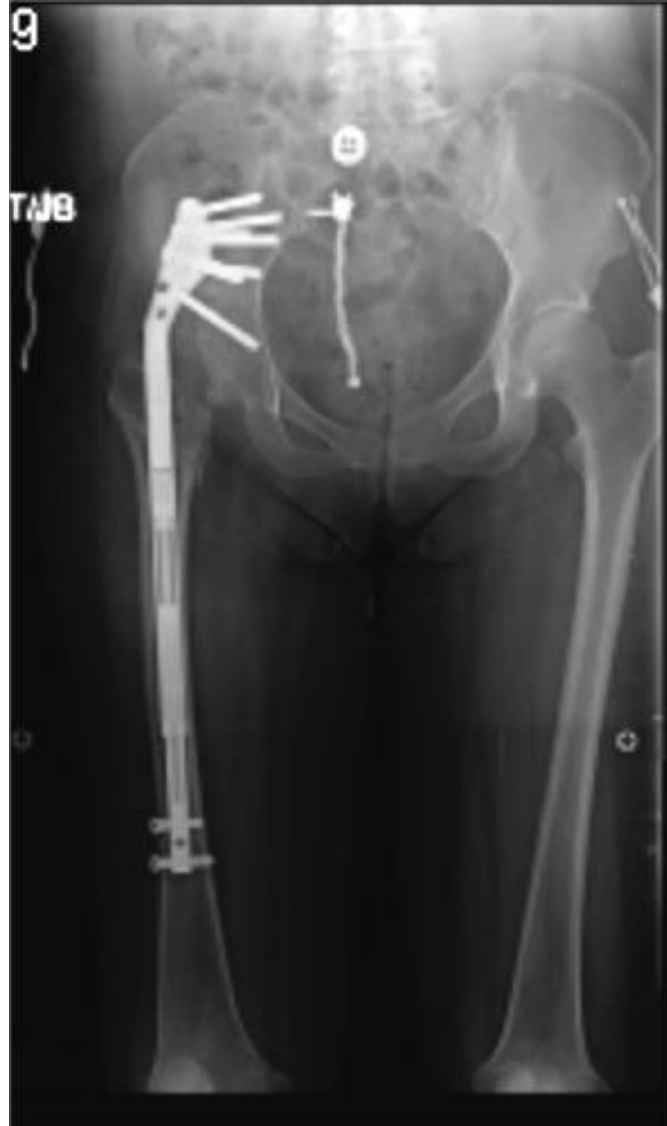Aug 31, 2015

Precice with Pelvic Fixation plate



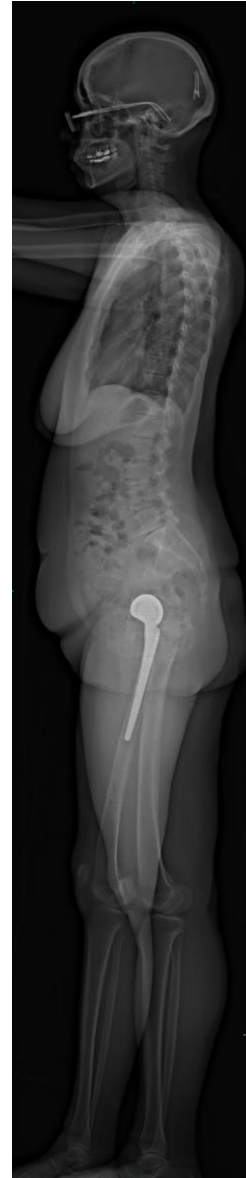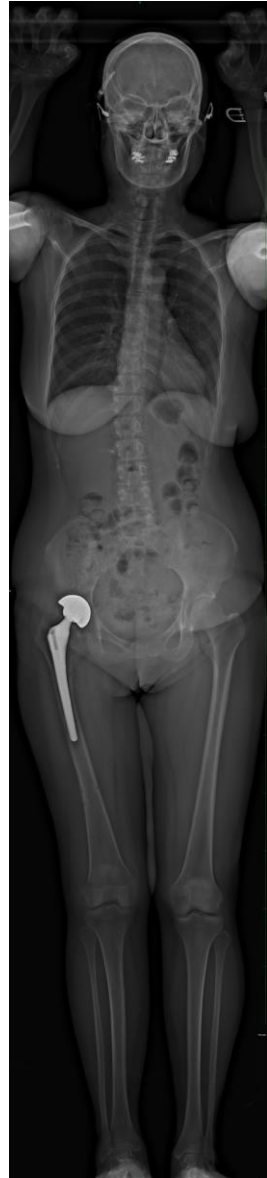September 24, 2015

5cm Lengthening: Femur at Station: THR



October 26, 2015

Leg Lengths Equalized



Deformity Correction with Lengthening

- Synchronus (same time) same osteotomy
- Synchronus separate osteotomy
- Metachronus (separate times) separate osteotomy

Strategies

- FAN using Precice as the Nail with lengthening thru deformity correction osteotomy
- FAN using Precice as the Nail with lengthening thru a second osteotomy
- FAN with Locking Nail and then later use Precice to lengthen
- Precice at one end and plate at other end either same time or delayed